International Journal of Applied Research 2018; 4(3): 197-203

ISSN Print: 2394-7500
ISSN Online: 2394-5869
Impact Factor: 5.2
IJAR 2018; 4(3): 197-203
www.allresearchjournal.com
Received: 15-01-2018
Accepted: 16-02-2018

KP Asifa
Endocrinology and Toxicology Laboratory, Department of Zoology, University of Calicut, Malappuram District, Kerala, India

Dr. KC Chitra
Endocrinology and Toxicology Laboratory, Department of Zoology, University of Calicut, Malappuram District, Kerala, India

Correspondence
KP Asifa
Endocrinology and Toxicology Laboratory, Department of Zoology, University of Calicut, Malappuram District, Kerala, India

Evaluation of acute toxicity of octylphenol in the cichlid fish, *Pseudetroplus maculatus* (Bloch, 1795)

KP Asifa and KC Chitra

Abstract
Octylphenol is an estrogenic environmental pollutant, widely used in the production of phenolic resins and octylphenol ethoxylates, which are used in the manufacturing of paints, textiles, detergents, pesticides and cleaning agents. The present study evaluates the median lethal concentration of octylphenol in the cichlid fish, *Pseudetroplus maculatus* for 96 h by probit analysis. Fish was exposed to eight different concentrations of octylphenol (50, 100, 150, 200, 250, 300, 350 and 400 µg/L) for 96 h along with control groups, maintaining ten animals in each group. Physico-chemical parameters of water as pH, hardness, dissolved oxygen and temperature were maintained during the treatment period. Mortality and behavioural changes of fish were observed and recorded throughout the experiment. The median lethal concentration (LC_{50}) for 96 h, determined by probit analysis was 150µg/L that killed 50% of the test animal. In all treatment groups, body weight remained unchanged whereas the mucous deposition was increased significantly in concentration-dependant manner when compared with the controls. Octylphenol treated fishes showed slow and restricted movement throughout the treatment period when compared to the control fishes. The entire body became haemorrhagic, fishes stayed in groups at the bottom with restricted activities and moved slowly towards the surface to gulp air, also showed inability to maintain normal posture and finally became lethargic. Octylphenol treatment altered the histo-architecture of gill and liver tissues which is evident by the degenerated primary and secondary lamellae or upliftment of epithelium of gill and vacuolated or necrotic hepatocytes at all concentrations. The results of the study concluded that octylphenol caused acute toxicity to fish when exposed for 96 h which is revealed by behavioural modifications and histological alterations that can be used as an indicator of ecologically relevant monitoring of environmental contaminants.

Keywords: Octylphenol, median lethal concentration, acute toxicity, *Pseudetroplus maculatus*

1. Introduction
The alkylphenol ethoxylates namely nonylphenol and octylphenol ethoxylates constitutes one of the major groups of surfactants used in a wide variety of industrial, agricultural, and domestic products and processes [1]. Due to its wide range of applications, the degradation products of these compounds are frequently found in the aquatic environments especially near wastewater outfalls [2, 3]. Octylphenol (OP) is one of the intermediates and common degradation products in the manufacture of octylphenol ethoxylates. It is widely used as non-ionic surfactant in the manufacturing of detergents, paints, plastics, paper, cosmetics, food products, emulsifiers and pesticide formulations [4, 5]. Even though the alkylphenol ethoxylates used in sewage treatment process are non-toxic and hydrophilic, the bacterial degradation of the compound produces more toxic hydrophobic metabolites namely nonylphenol, octylphenol and other derivatives [6]. Thus octylphenol is exposed more in the aquatic environments mainly from sewage treatment plants and manufacturing industries so that it is often detected in surface water, sediments, sewage sludge and waste waters [7, 8, 9, 10]. Due to its hydrophobic nature, octylphenol tend to accumulate in sewage sludge and river sediments [11]. Octylphenol has high potential of bioaccumulation and bio-concentration in different tissues of fishes with maximum in liver and fat tissues [12, 13]. It has been reported in aquatic environments at levels of 0.084 *ppb* or 0.407×10^{-9} M [2]. Moreover, studies have reported that octylphenol was detected in human breast milk, which has been correlated with consumption of contaminated fish foods [14].
Octylphenol contamination in various environmental compartments potentially resulted in toxicity and damage to the health status of exposed organisms due to its estrogenic activity

that disrupt endocrine function through competitive binding to the natural estrogen receptors [11]. Octylphenol binds to the estrogen receptors of fishes, stimulates transcriptional activation of estrogen-responsive genes and induce production of yolk protein vitellogenin in male rainbow trout and fish hepatocyte cell culture [15, 16]. Octylphenol has been shown to induce estrogenic responses in fish and are recognized as toxic to both marine and freshwater species [15, 17]. Estrogenicity of the contaminant is the main route cause of reproductive and developmental anomalies in fish and other animals. Studies have reported that octylphenol affect hormone production, gonadal development and spermatogenesis in different species of fish [18, 19, 20]. Octylphenol has been shown to impair the antioxidant status and at 75µg/ L concentration caused genotoxicity in *Oreochromis mossambicus* [21]. Similarly, octylphenol exposure caused induction of oxidative stress and histological alterations along with inhibition of brain acetycholinesterase activity in *Oreochromis niloticus* [22].

The present study made an attempt to evaluate the acute toxicity effects of octylphenol in the cichlid fish *Pseudetroplus maculatus*. Nowadays, several methods are available to study the acute toxicity effects of environmental contaminants. Usually, in acute toxicity studies, the contaminant induced damages were examined during short-term exposures. Determination of median lethal concentration (LC_{50}) is one of the most commonly used acute toxicity test that measures the concentration-lethality relationship of the test chemical in the experimental organism for 96 h exposure duration [23]. Based on the physiological nature of the test organism the concentration of chemical responsible for lethality may vary from species to species. *Pseudetroplus maculatus*, the experimental organism used in the present study is highly sensitive to various environmental contaminants [24, 25]. The present study also evaluates behavioural modifications and histopathological alterations in the gill and liver tissues after exposure to octylphenol at different concentrations.

2. Materials and methods

2.1 Experimental animal

Healthy adult freshwater cichlid fish, *Pseudetroplus maculatus* weighing 7 ± 1 g and length 7 ± 1.5 cm were collected from Angel fish aquarium, Chalakkudi, Trissur, Kerala. India and acclimated to the laboratory conditions for 15 days before experiment. During acclimatization the specimens were fed with standard fish pellets. Fishes were maintained in aquarium tank with 40L capacity, containing dechlorinated water.

2.2 Preliminary tests

The physico-chemical features of the tap water were estimated as per APHA guidelines [26]. Water temperature in the test ranged from 28 ± 2 °C during the experiment, oxygen saturation of water ranged between 70 and 100 %, pH is 7.6 which were continuously monitored using standardized procedures.

2.3 Chemicals

Octylphenol (4-(1, 1, 3, 3-tetramethylbutyl) phenol) of 90% purity was obtained from SISCO Research Laboratories Pvt. Ltd., Mumbai, India. Dimethyl sulfoxide, formalin, alcohol, xylene, paraffin wax, eosin and haematoxylin were obtained from Himedia Laboratories, Mumbai, India.

2.4 Evaluation of median lethal concentration (LC_{50} -96 h)

The median lethal concentration of octylphenol exposed for 96 h was determined by probit analysis, with a confident limit of 5% level [27]. The fishes were not fed a day prior to and during the test to reduce faecal and excess food contaminating the test solution. Monofilament netting was used to cover the tanks so as to prevent the fishes from jumping out of test solutions and aerated using tubed motorized pumps. The concentration of the pollutant at which 50 percentage of the test animals dies during a specific period or the concentration lethal to one half of the test population is referred to as median lethal concentration (LC_{50}) or median tolerance limit. For determining LC_{50} of octylphenol, eight different concentrations (50, 100, 150, 200, 250, 300, 350 and 400 µg/L) of octylphenol were introduced in to separate tanks of 40 L capacity maintaining 10 animals in each group. Since octylphenol is insoluble in water, it was first dissolved in 1% dimethyl sulfoxide (DMSO) and thus it was used as the vehicle control. Control tanks (Vehicle control and solvent-free control) having 10 fishes were also maintained along with treatment groups. The mortality as well as behavior of fishes in each group was monitored throughout the experiment at varying concentrations. The body weight and mucous deposition of fish in each control and treatment groups were recorded as soon as the mortality was observed or at the end of 96 h as well as before treatment. Histopathology of gill and liver from 150 µg/L and above concentrations groups were done as per standard procedure and changes at 150 and 400 µg/L alone were photomicrographed using Cannon shot camera fitted to Carl Zeiss Axioscope 2 Plus Trinocular Research Microscope.

2.5 Statistical analyses

Median lethal concentration or 96 h-LC_{50} value were analyzed by Probit analysis using SPSS statistical software (Version 19.0). The correlation between mortality on the Y-axis and concentrations on X-axis and the best-fit line was also obtained by using MS Excel 2007.

3. Results

In the present study, fishes irrespective of gender were exposed to eight different concentrations of octylphenol for 96 h maintaining the control groups. Mortality of the animal was continuously monitored throughout the experiment and it was observed that in both vehicle and solvent-free control groups, fishes showed no mortality or behavioural changes. Octylphenol at concentrations, 50, 100, 150, 200, 250 and 300 µg/L showed death of 1, 2, 5, 6, 7 and 8 animals respectively at the end of 96 h exposure (Table 1). Mortality of 100% was observed at 350 and 400 µg/L octylphenol concentrations after 96 h and 48 h, respectively (Table 1). The median lethal concentration analysed using Probit analysis was found as 150 µg/ L that kills 50% of animals. The regression line was plotted against mortality (vertical axis) and concentrations (horizontal axis) and the best fit line showed 150 µg/ L as the median lethal concentration of octylphenol for 96 h in cichlid fish, *Pseudetroplus maculatus* (Figure 1).

Octyphenol treatment showed behavioural alterations such as slow and restricted activities throughout the treatment period, fishes stayed in groups at the bottom of the tank without normal movements meanwhile moved slowly

towards the water surface to gulp air. The opercular movement of treated fishes initially increased and then gradually decreases at the end to exposure. At the end of treatment, the entire body of fish became hemorrhagic and showed inability to maintain normal posture and lost equilibrium immediately before mortality. No significant changes were noticed on the body weight of the animal after different concentrations of octylphenol exposure when compared with the control groups (Figure 2). However, mucous secretion was found increased significantly ($P<0.05$) in all octylphenol exposed groups in concentration-dependant manner (Figure 3).

The normal histoarchitecture of gill composed of gill arches, primary and secondary gill lamellae (Figure 4A), whereas in octylphenol exposed fishes showed upliftment of gill epithelium, vacuolization, atrophy of gill lamellae and fusion or absence of secondary lamellae from 150 µg/L concentrations (Figure 4B). In both control groups, the liver histology showed normal architecture having regular arrangement of hepatocytes with distinct cell membrane and spherical nucleus (Figure 4C). In the treatment groups from 150 µg/L concentration onwards the hepatocyte showed vacuolization, loss of membrane structure, necrosis, and irregular or absence of nucleus (Figure 4D).

Table 1: Acute toxicity of octylphenol on the mortality rate of the fish, *Pseudetroplus maculatus* exposed for 96 h

Concentration (µg/ L)	Total number of fish	Mortality (in Numbers)	Mortality (in %)	Hour of mortality
Control	10	0	0	-
Vehicle	10	0	0	-
50	10	1	10	96 h
100	10	2	20	96 h
150	10	5	50	96 h
200	10	6	60	96 h
250	10	7	70	96 h
300	10	8	80	96 h
350	10	10	100	96 h
400	10	10	100	48 h

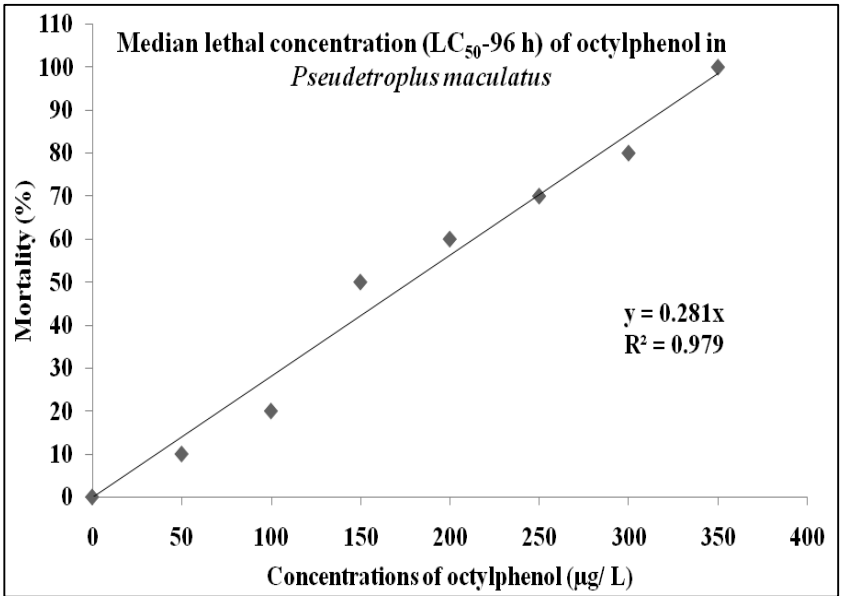

Fig 1

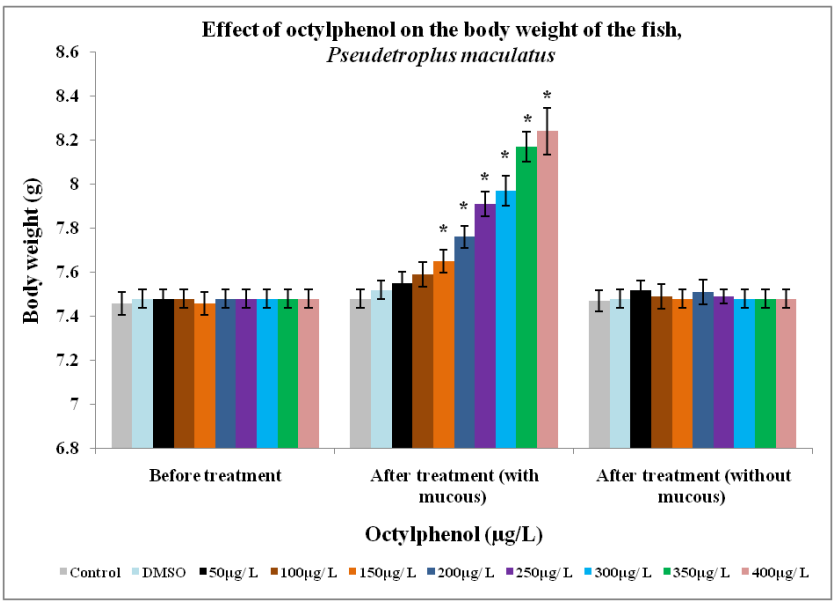

Fig 2

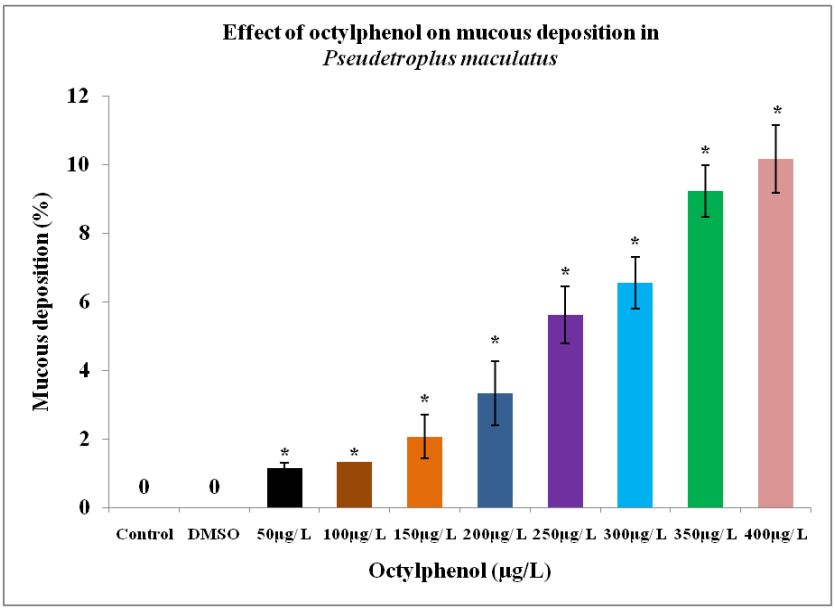

Fig. 3

4. Discussion

Recently, the widespread mortality of fish and other aquatic species is considered as one of the major environmental impacts due to the contamination of aquatic ecosystem with different industrial and agricultural pollutants. Generally, exposure to toxic substances could not result in immediate fish kills, but may affect fish population by increasing the incidence of abnormalities, increasing natural mortality, decreasing fecundity, decreasing viability of egg, sperm and larvae and reducing life expectancy [28]. Thus to evaluate the incidence of contamination by different toxicants in various environmental compartments, several methods are available. Usually aquatic toxicological studies involve assessment of toxicity effects of various environmental contaminants based on the median lethal concentration as it directly measures the toxicity of substances on the exposed organisms. The present study evaluates the acute toxicity of octylphenol by exposing at eight different concentrations in cichlid fish *Pseudetroplus maculatus* and the results clearly demonstrated that as the concentration of octylphenol increased, fish mortality also increased indicating a direct proportional relationship between mortality and concentration of test chemical. The probit analysis clearly states that 150 µg/L as the median lethal concentration of octylphenol to the cichlid fish *Pseudetroplus maculatus*. Previous studies in our laboratory have reported the median lethal concentration of octylphenol in *Oreochromis mossambicus* and *Oreochromis niloticus*, as 750 µg/ L and 506.17µg/L respectively for 96 h [21, 22]. From these studies, it is clearly understood that the fish *Pseudetroplus maculatus* is more sensitive to octylphenol than the other two species.

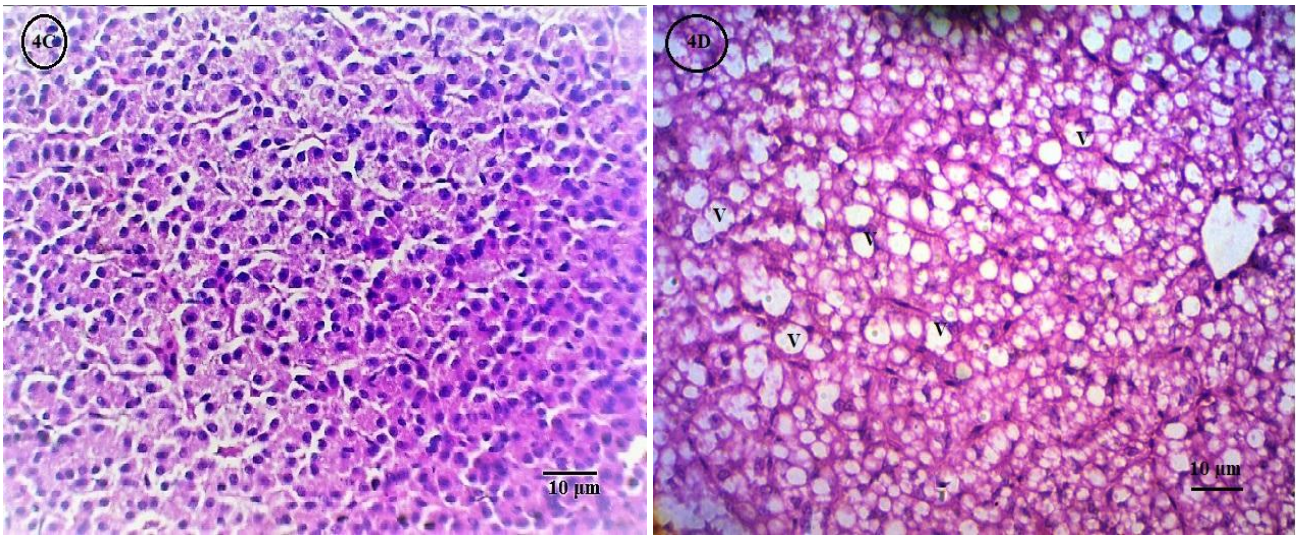

Fig 4: Histomorphology of gill and liver tissues exposed to octylphenol in *Pseudetroplus maculatus*. 4A-Gill Control; 4B-Gill exposed to octylphenol showing upliftment of gill epithelium (←), vacuolization (V), fusion or absence of secondary lamellae (→); 4C-Liver Control; 4D-Liver exposed to octylphenol showing vacuolization (V), loss of membrane structure, necrosis, and irregular or absence of nucleus.

Behavioural characteristics are obviously sensitive indicators of toxicant effect because it serves as the link between physiological and ecological processes in an organism [29]. Thus any variations in the normal behavioural pattern may be affected by numerous physiological and environmental influences. In the present study, fish exposed to octylphenol showed slow and restricted swimming activities throughout the experimental period, where fishes were found stayed in groups at the bottom of the tank and swim slowly towards the water surface for gulping air. The exposed fish exhibited increased opercular movement initially and then it was decreased slowly as the treatment proceeds. At the end of treatment period, the entire body of fish became reddened and hemorrhagic, unable to maintain normal posture and balance and finally became lethargic. Similarly, gulping air and swimming at the water surface were observed along with increased mucous secretion in *Oreochromis mossambicus* when exposed to sublethal concentrations of organophosphorus insecticide RPR-V [30]. Impairments in neuromuscular coordination is considered as one of the reasons for abnormal swimming activities and loss of equilibrium and this could be due to accumulation of acetylcholine in synaptic and neuromuscular junctions [31]. This is also confirmed by one of the previous study in our laboratory, which proved that octylphenol at sublethal concentration inhibits the activity of acetylcholinesterase activity in the brain and blood of *Oreochomis niloticus* after 48 h of exposure [22]. Along with behavioural alterations octylphenol exposure caused increased secretion of mucous in concentration-dependant manner when compared to the control groups. The excess secretion of mucous in fish forms a non-specific response against toxicants, thereby possibly dropping toxicant contact. It also forms a barrier between the body and the toxic medium, so as to minimize its exasperating effect, or to forage it through epidermal mucous [32].

Histological examination is a simple and very sensitive tool to realize the structural modifications occurring in the tissues as a result of contaminant exposure. In fish, gills are the first organ to which the pollutant primarily contact and also functions as the site of respiration, osmoregulation and excretion [33]. Thus, gills are often predisposed to damage by any toxicant which shows several cellular modifications such as upliftment, hyperplasia and hypertrophy of the epithelial cells, partial or complete fusion of some secondary lamellae, vacuolization and necrosis [33]. In the present study, octylphenol exposure resulted in vacuolization, upliftment of gill epithelium, atrophy and necrosis of primary and secondary gill lamellae and fusion of secondary lamellae. Lifting of lamellar epithelium increases the distance between epithelial spaces so that the waterborne pollutants are less able to diffuse and reach the blood stream, which could be one of the initial defensive mechanisms of the gill tissue against the contaminant. Similar observations have been reported when the fish, *Pseudetroplus maculatus* was exposed to the pesticide chlorpyrifos and carbon nanomaterial fullerene [34, 35]. Liver is considered as the most vulnerable organ for toxicant-induced damage, since it is associated with detoxification and biotransformation processes [36]. Hepatocytes are parenchymal tissue having homogenous cytoplasm with a large central or subcentral spherical nucleus. Several environmental contaminants are known to alter the normal histoarchitecture of liver in fish [37]. *Oreochromis mossambicus* when exposed to heavy metals as copper and zinc induce histological alterations as hyalinization, hepatocyte vacuolation, cellular swelling, and congestion of blood vessels in the liver [38]. Similarly, the organophosphorus pesticide profenofos induced vacuolation, nuclear degeneration, cellular edema and pyknotic nucleus in the liver of *Labeo rohita* at sublethal concentrations [39]. In the present study octylphenol also caused cellular alterations such as vacuolization, broken cell membrane, irregular shaped hepatocytes and necrosis in the liver tissue. The vacuole formation is a cellular defensive mechanism of hepatocytes against toxic compounds that check it from interfering with the biological activities of hepatocytes [40]. Thus the fish try to overcome the toxic effects of octylphenol at some extent, but at higher concentrations, the contaminant caused complete cellular disintegration of both gill and liver tissues after 96 h of exposure duration.

5. Conclusion

The median lethal concentration of octylphenol (LC_{50}-96 h) by probit analysis for *Pseudetroplus maculatus* was determined as 150 µg/ L. The toxicity effect of octylphenol is also demonstrated by modifications in normal behaviour and histopathological alterations, which confirm the negative impacts of the contaminant. Thus the acute toxicity test have been documented as the primary step in determining the water quality management of fish and disclose toxicant concentrations which cause fish mortality even after short period of exposure.

6. Acknowledgement

Authors gratefully acknowledge the financial support from Kerala State Council for Science, Technology and Environment (KSCSTE), Thiruvananthapuram, Kerala, India to carry out this study.

7. References

1. Nimrod AC, Benson WH. Environmental estrogenic effects of alkylphenol ethoxylates. Crit Rev Toxicol. 1996; 26(3):335-364.
2. Bennie D, Sullivan CA, Lee HB, Peart TE, Maguire RJ. Occurrence of alkylphenols and alkylphenol mono- and diethoxylates in natural waters of the Laurentian Great Lakes Basin and the upper St. Lawrence River. Sci Total Environ. 1997; 193(3):263-275.
3. Bennett ER, Metcalfe CD. Distribution of alkylphenol compounds in Great Lake sediments, United States and Canada. Environ Toxicol Chem. 1998; 17(7):1230-1235.
4. Tolls J, Kloepper-Sams P, Sijm D. Surfactant bioconcentration-A critical review. Chemosphere. 1994; 29(4):693–717.
5. Ying GG, Williams B, Kookana R. Environmental fate of alkylphenols and alkylphenol ethoxylates-a review. Environ Int. 2002; 28(3):215-226.
6. Ahel M, Giger W, Koch M. Behavior of alkylphenol polyethoxylate surfactants in the aquatic environment-I. Occurrence and transformation in sewage treatment. Water Res. 1994; 28(5):1131–1142.
7. Rudel RA, Melly SJ, Geno PW, Sun G, Brody JG. Identification of alkylphenols and other estrogenic phenolic compounds in wastewater, seepage, and groundwater on Cape Cod, Massachusetts. Environ Sci Technol. 1998; 32(7):861–869.
8. Bolz U, Hagenmaier H, Korner W. Phenolic xenoestrogens in surface water, sediments and sewage sludge from Baden- Wurttemberg, south-west Germany. Environ Pollut. 2001; 115(2):291–301.
9. Isobe T, Nishiyama H, Nakashima A, Takada H. Distribution and behavior of nonylphenol, octylphenol and nonylphenol monoethoxylate in Tokyo metropolitan area: their association with aquatic particles and sedimentary distribution. Environ Sci Technol. 2001; 35(6):1041–1049.
10. Jin X, Jiang G, Huang G, Liu J, Zhou Q. Determination of 4- tert-octylphenol, 4-nonylphenol and bisphenol A in surface waters from the Haihe River in Tianjin by gas chromatography-mass spectrometry with selected ion monitoring. Chemosphere 2004; 56(11):1113–1119.
11. White R, Jobling S, Hoare SA, Sumpter JP, Parker MG. Environmentally persistent alkylphenolic compounds are estrogenic. Endocrinology. 1994; 135(1):175-182.
12. Ferreira-Leach AM, Hill EM. Bioconcentration and distribution of 4-tert-octylphenol residues in tissues of the rainbow trout (*Oncorhynchus mykiss*). Mar Environ Res. 2001; 51(1):75-89.
13. Liu J, Wang R, Huang B, Lin C, Wang Y, Pan X. Distribution and bioaccumulation of steroidal and phenolic endocrine disrupting chemicals in wild fish species from Dianchi Lake, China. Environ Pollut. 2011; 159(10):2815-2822.
14. Chen GW, Ding WH, Ku HY, Chao HR, Chen HY, Huang MC, Wang SL. Alkylphenols in human milk and their relations to dietary habits in central Taiwan. Food Chem Toxicol. 2010; 48(7):1939-1944.
15. Jobling S, Sumpter JP. Detergent components in sewage effluent are weakly oestrogenic to fish: an in vitro study using rainbow trout (*Oncorhynchus mykiss*) hepatocytes. Aquat Toxicol. 1993; 27(3-4): 361-372.
16. Flouriot G, Pakdel F, Valotaire Y. Influence of xenobiotics on rainbow trout liver estrogen receptor and vitellogenin gene expression. J Mol Endocrinol. 1995; 15(2):143-151.
17. Robinson CD, Brown E, Craft JA, Davies IM, Moffat CF. Effects of prolonged exposure to 4-tert-octylphenol on toxicity and indices of oestrogenic exposure in the sand goby (*Pomatoschistus minutus*, Pallas). Mar Environ Res. 2004; 58(1):19-38.
18. Gray MA, Niimi AJ, Metcalfe CD. Factors affecting the development of testis- ova in medaka, *Oryzias latipes*, exposed to octylphenol. Environ Toxicol Chem. 1999; 18(8):1835-1842.
19. Zaroogian G, Gardner G, Horowitz DB, Gutjahr-Gobell R, Haebler R, Mills L. Effect of 17β-estradiol, o, p′-DDT, octylphenol and p, p′-DDE on gonadal development and liver and kidney pathology in juvenile male summer flounder (*Paralichthys dentatus*). Aquat Toxicol. 2001; 54(1-2):101-112.
20. Ortiz-Zarragoitia M, Cajaraville MP. Effects of selected xenoestrogens on liver peroxisomes, vitellogenin levels and spermatogenic cell proliferation in male zebrafish. Comp Biochem Physiol C Toxicol Pharmacol. 2005; 141(2):133-144.
21. Sreedevi NV, Chitra KC. Biochemical and genotoxic effects of octylphenol in hepato-mitochondrial fractions of freshwater fish, *Oreochromis mossambicus*. J Cell Tissue Res. 2014; 14(2):4211-4218.
22. Jayasree PJ, Sumi N, Chitra KC. Effects of octylphenol on oxidative stress-mediated neurotoxicity in brain of the fish, *Oreochromis niloticus* (Linnaeus, 1758). Int J Fish Aquat Stud. 2018; 6(1):52-58.
23. Hodson PV, Dixon DG, Kaiser KL. Measurement of median lethal dose as a rapid indication of contaminant toxicity to fish. Environ Toxicol Chem. 1984; 3(2):243-254.
24. Asifa KP, Chitra KC. Effects of nonylphenol-induced oxidative stress in ovary of cichlid fish, *Etroplus maculatus* (Bloch, 1795). Int Lett Nat Sci. 2016; 1(58):11-15.
25. Raibeemol KP, Chitra KC. Effect of acute exposure to chlorpyrifos on hepatic antioxidant system in the freshwater fish, *Pseudetroplus maculatus* (Bloch, 1795). 2017; 4(9):7-14.
26. APHA. Standard methods for the examination of water and waste water, 20th Edition, Washington, DC. 1998.

27. Finney DJ. Probit analysis, 3rd (Ed.), Cambridge University Press, London. 1971; 333.
28. Allan L. Fish kills in New South Wales. NSW Department of primary industries, Department of Agriculture advisory. 2000; 4(86).
29. Atchison GJ, Henry MG, Sandheinrich MB. Effects of metals on fish behavior: a review. Environ Biol Fish. 1987; 18(1):11-25.
30. Rao JV. Toxic effects of novel organophosphorus insecticide (RPR-V) on certain biochemical parameters of euryhaline fish, *Oreochromis mossambicus*. Pest Biochem Physiol. 2006; 86(2):78-84.
31. Rao JV, Begum G, Pallela R, Usman PK, Rao RN. Changes in behavior and brain acetylcholinesterase activity in mosquito fish, *Gambusia affinis* in response to the sub-lethal exposure to chlorpyrifos. Int J Environ Res Public Health. 2005; 2(3):478-483.
32. Nagaraju B, Rathnamma V. Determination of median lethal concentrations (LC_{50}) of carbosulfan to freshwater fish *Labeo rohita* (Hamilton) and its behavioural impacts. J Stress Physiol Biochem. 2014; 10(3):218-231.
33. Mallatt J. Fish gill structural changes induced by toxicants and other irritants: a statistical review. Canad J Fish Aquat Sci. 1985; 42(4):630-648.
34. Raibeemol KP, Chitra KC. Chronic effect of chlorpyrifos on histoarchitectural alterations in gill, liver, kidney and spleen of freshwater fish, *Etroplus maculatus* (Bloch, 1795). Int J Res. 2016; 3(5):350-360.
35. Sumi N, Chitra KC. Histopathological alterations in gill, liver and muscle tissues of the freshwater fish, *Pseudetroplus maculatus* exposed to fullerene C_{60}. Int J Fish Aquat Stud. 2017; 5(3):604-608.
36. Camargo MMP, Martinez CBR. Histopathology of gills, kidney and liver of a Neotropical fish caged in an urban stream. Neotrop Ichthyol. 2007; 5(3):327-336.
37. Bernet D, Schmidt H, Meier W, Burkhardt- Holm P, Wahli T. Histopathology in fish: proposal for a protocol to assess aquatic pollution. J Fish Dis. 1999; 22(1):25-34.
38. Van Dyk JC, Pieterse GM, Van Vuren JH. Histological changes in the liver of *Oreochromis mossambicus* (Cichlidae) after exposure to cadmium and zinc. Ecotoxicol Environ Saf. 2007; 66(3):432-440.
39. Nataraj B, Hemalatha D, Rangasamy B, Maharajan K, Ramesh M. Hepatic oxidative stress, genotoxicity and histopathological alteration in fresh water fish *Labeo rohita* exposed to organophosphorus pesticide profenofos. Biocatal Agric Biotechnol. 2017; 12:185-190.
40. Mollendroff. Cytology and cell physiology. Edn 3, Academic press, New York, 1973.