



ISSN Print: 2394-7500
ISSN Online: 2394-5869
Impact Factor: 5.2
IJAR 2015; 1(10): 1078-1080
www.allresearchjournal.com
Received: 03-07-2015
Accepted: 04-08-2015

Dr. SD Takele
Department of Orthopedics
KIMS, Karad, Maharashtra,
India

Dr. Ram M Jethmalani
Department of Orthopedics
KIMS, Karad, Maharashtra,
India

Study of management of fracture distal end femur with locking compression plate and screw system

SD Takele and Ram M Jethmalani

Abstract

Aim: To defining the role of locking condylar plate in the treatment of distal femur fractures.

Material and Method: Fractures were classified with the help of radiographs according to the AO-ASIF classification. Preoperative calculation was done on radiographs to ascertain the size of the plate, accurate size of locking, cortical and cancellous screws after subtraction of the magnification factor. The limb to be operated was prepared. One gm of third generation cephalosporin was injected the night before surgery and early morning on the day of surgery before shifting the patient to the operation theatre.

Results: Out of 25 patients, 3 had shortening, 2 of them shortening of 15 mm and 1 patient had shortening of 10mm. In this study, very few patients had significant varus/valgus malalignment. The duration of follow-up ranged from 3 months to 18 months.

Conclusion: Locking Compression Plate is an important armamentarium in treatment of fractures of distal end femur, especially when fracture is severely comminuted and in situations of osteoporosis. However a more comprehensive study with longer follow up periods is essential to throw more light into the advantages, complications and possible disadvantages of the use of Locking Compression Plate with special attention to the long term outcomes.

Keywords: distal femur fractures, locking condylar plate

Introduction

The incidence of distal femur fractures is approximately 37 per 1,00,000 person-years [1]. Distal femoral fractures mainly arise from two different injury mechanisms. They are often caused by high energy trauma mainly sustained in road traffic accidents. Open injuries with considerable comminution of condyles and metaphysis are frequently seen, as is low energy trauma, relating to elderly patients with severe osteoporosis frequently seen as periprosthetic fracture. In high-energy trauma, the problem of restoring the function in a destroyed knee joint persists. Complex knee ligament injuries frequently occur additionally to extensive cartilage injuries. In elderly patients, extreme osteoporosis represents a particular problem for anchoring the implant [1].

Internal fixation with locking plates creates a toggle free, fixed angle construct [4]. The introduction of plates with the option of locked screws has provided the means to increase the rigidity of fixation in osteoporotic bone or in the presence of periarticular or juxta-articular fractures with a small epiphyseal segment. The implant offers multiple points of fixed-angle contact between the plate and screws in the distal part of femur, theoretically reducing the tendency for varus collapse that is seen with traditional lateral plates [10]. The DF-LCP is a further development from the LISS which was introduced in the mid to late 1990's. The main difference between the DF-LCP and the LISS is that the LISS utilizes an outrigger device for shaft holes, functioning essentially as a locking guide jig, which is attached to the distal part of the plate and guides the placement of the proximal locking screws. The shaft holes on the DF-LCP are oval allowing for the options of a compression screw or a locking screw. This leads to a more precise placement of the plate, as it is able to be compressed more closely to the bone [2, 3].

Since there have been no published studies focusing specifically on the LCP condylar plate, this study will help us in defining the role of locking condylar plate in the treatment of distal femur fractures [5].

Correspondence

Dr. SD Takele
Department of Orthopedics
KIMS, Karad, Maharashtra,
India

The study is justified for the fact that it will be one of the solutions for the age old complications associated with the treatment of supracondylar fractures with traditional fixed angle plates and nails of, postoperative loss of reduction (varus collapse) and malalignment due to their inherent lack of rigidity and in some cases, eventual implant failure [6]. The locking condylar plate is based on the firm principles of locked plating, which has really yielded a lot of success in the treatment of fractures over the years.

Material and Method

In this study 25 patients with closed supracondylar fractures of femur (distal fifteen cm of femur) were studied. All the cases were treated at Krishna Hospital, karad, between 1 – 10 - 2009 & 01- 04 -2011 at our institution and followed for a minimum of 6 months. The duration of follow up ranged from 6 months to 24 months. All the fractures in this series were post-traumatic. No pathological fracture was included in the study. Also supracondylar fractures in children were not considered. Supracondylar fractures treated conservatively and fixed with other fixation systems like AO blade plate and condylar buttress plate were not included.

Fractures were classified with the help of radiographs according to the AO-ASIF classification. Preoperative calculation was done on radiographs to ascertain the size of the plate, accurate size of locking, cortical and cancellous screws after subtraction of the magnification factor. The limb to be operated was prepared. One gm of third generation cephalosporin was injected the night before surgery and early morning on the day of surgery before shifting the patient to the operation theatre.

Patient is placed supine on a radiolucent table with a pillow below the knee, the entire injured extremity and ipsilateral iliac crest are prepared and draped. Tourniquet applied and inflated. Lateral incision is made parallel to the shaft of the femur, beginning at the Gerdy tubercle and extending proximally far enough to permit application. Longitudinal incision is made through the fascia lata, and extended distally into the iliotibial band. The distal part of the incision is extended through the lateral joint capsule and synovium, avoiding injury to the meniscus. More proximally, the fascia overlying the vastus lateralis muscle is incised and the muscle reflected anteriorly off the intermuscular septum and perforating vessels are identified and ligated or coagulated. Minimal Stripping of soft tissue necessary for application of the plate and reduction of the articular surface is done. To preserve their vascularity, attempt is not made to expose and anatomically reduce comminuted anterior and metaphyseal fragments. Often the shaft of the femur is wedged between two condyles; if so, by applying traction to the leg with the knee flexed, wedged shaft of femur is displaced. Quadriceps mechanism and the patella are reflected medially to expose the entire lower end of the femur.

Result

In present study 25 fractures of the supracondylar femur were treated. All cases were fresh, 18 patients were males and 7 patients were females. The median age was 45 years ranging from 22-68 years. 18 of the fractures were caused by road traffic accidents and 7 were due to fall. 18 patients were with fracture on right side and 7 on left side. Of the 25 'lower end of Femur' fractures, 5 were Mullers type A3; 3 was Mullers type B1; 7 were Mullers type C1; 5 were Mullers type C2 and remaining 5 were Mullers type C3. All

fractures were closed. 8 patients had associated injuries. Of them, 2 patients had comminuted fracture of contralateral tibia. 2 patients among fracture lower end femur pattern had ipsilateral tibial fracture and 2 patient had fractures of the acetabulum one patient had associated distal end radius fracture and one patient had fracture of patella ipsilateral side. All patients were operated within 7 days. 7 of them within 3 days of injury. Average time duration of surgery was 112 minutes.

The size of plate was selected based on the type of fracture. Five to Twelve holed plates were [6].

Used more commonly. One patient went for delayed union. Infection was encountered in 4 cases. They were early infections treated with saline wash, Debridement and higher antibiotics as warranted by culture report. The fractures went on to heal uneventfully. Average flexion in this study was 105 degree with more than 65% patients having knee range of motion more than 110°. Average knee extensor lag in this study was 5.60 degrees. Out of 25 patients, 3 had shortening, 2 of them shortening of 15 mm and 1 patient had shortening of 10mm. In this study, very few patients had significant varus/valgus malalignment. The duration of follow-up ranged from 3 months to 18 months. Results are summarized in charts and tables below. (Table 1)

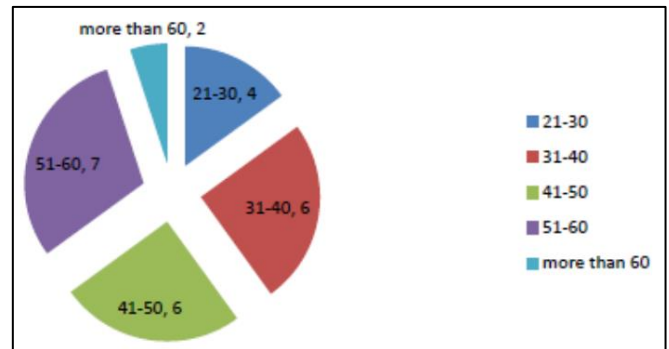


Table 1: Fracture lower end femur age distribution

Discussion

Present study comprised of twenty five patients with Distal end Femur Fractures who were treated by Locking Compression plate. Overall final outcome was assessed in terms of regaining the lost knee function using NEER'S Score. Out of 25 patients, 18 patients were males and 7 patients were females. This may suggest that RTA were most commonly seen in males when compared to females. Out of 25 patients, 18 were due to RTA which is attributable to the fact that fracture distal end of femur are associated with high velocity trauma. When seeing the relationship between age and mechanism of injury it was found that most of the vehicular accidents were seen in patients below the age of 50 years, and that of fall was not contributory. On seeing the relationship between sex and cause of fracture it was found that most of the vehicular accidents were seen in males rather than females, whereas it was not contributory in terms of fall from height. Maximum number of cases was of Muller type C-68%. 8 patients had associated injuries. 2 had comminuted fracture of contralateral tibia [8]. 2 had fracture of ipsilateral tibia and 1 had fracture of acetabulum. 1 had fracture distal end radius and 2 had ipsilateral patellar fracture. Internal fixation was considered after patients general and medical condition was stabilized. Average injury-surgery interval was 5.6 days. As we performed open reduction and internal fixation, the average operative time was 112 minutes. The

size of plate was selected based on the type of fracture. 5 to 12 hole plate were used most commonly^[7]. Radiological union was defined as presence of bridging callus across three cortices. Of 25 patients, 20(80%) showed radiological union within 18 weeks. 40% of the patients achieved weight bearing at the end of 14 weeks. Average flexion in this study was 120 degree with more than 64% patients having knee range of motion more than 110 degree. More than 60% patients were extensor lag less than 5 degree. Very few patients had varus/valgus malalignment. out of 25 patients, 3 had shortening. 2 had 15mm and 1 had 10mm shortening. Excellent results were seen in about 52% patients according to functional outcome—NEER'S scoring. 4 patients had superficial infection and 1 patient had delayed union^[9].

48 fractures were operated on within the first 24 hours. Revision operations were required for 2 cases of implant breakage. 4 cases of implant loosening and 7 debridments to deal with infections. The study showed clearly that when working with LISS, primary cancellous bone grafting was not necessary. The total follow up rate was 93%. 5% nonunion was observed. Our results are comparable to the study with similar rates of infection although no cases of implant breakages and nonunion were seen. Weight and Collinge⁶⁸ retrospectively evaluated the use of the LISS locked plating construct in 22 distal femur fractures in 21 patients. All fractures achieved union at a mean of 13 weeks (range, 7 to 16 weeks) without the need for secondary intervention. There were no implant failures in this patient cohort; at a mean of 19 months of follow-up, knee range of motion was 5 to 114 degrees.

In a similar retrospective evaluation of LISS plate fixation for 103 distal femur fractures, Kregor *et al.* 69 reported a 93% union rate without secondary bone grafting. The remaining 7 cases went on to uneventful union subsequent to bone grafting procedures^[10]. At a mean follow-up of 14 months, the mean knee range of motion in this cohort was 1 to 109 degrees. Implant failure in the form of proximal screw loosening occurred in 5 cases, each requiring revision surgery. In present study we treated 25 cases of distal femoral osteoporotic fractures with an average age of 44 years. The average union time was 18 weeks. In our study average time for union is slightly more when compared to the above studies this maybe in accordance with the fact that all our cases were treated with open reduction with incidence of infection (superficial) which is higher since we used open reduction and internal fixation, in about four cases and the relatively higher incidence of associated fractures in almost eight cases.

Conclusion

To conclude, Locking Compression Plate is an important armamentarium in treatment of fractures of distal end femur, especially when fracture is severely comminuted and in situations of osteoporosis. However a more comprehensive study with longer follow up periods is essential to throw more light into the advantages, complications and possible disadvantages of the use of Locking Compression Plate with special attention to the long term outcomes

Conflict of interest: No conflict of interest

References

1. Arneson TJ, Melton LJ 3rd, Lewallen DG, *et al.* Epidemiology of diaphyseal and distal femoral fractures

- in Rochester, Minnesota, 1965-1984. *Clin orthop.* 1988; 234:188-94.
2. Schandelmaier P, Partenheimer A, Koenemann B, *et al.* Distal femoral fractures and LISS stabilization. *Injury.* 2001; 32(1)3:SC55-63.
3. Martinet O, Cordey J, Harder Y, *et al.* The epidemiology of fractures of the distal femur. *Injury.* 2000; 31(3):C62-3.
4. Michael Z, Mohit B, *et al.* Operative treatment of acute distal femur fractures: systematic review of 2 comparative studies and 45 case series (1989-2005). *J Orthop Trauma.* 2006; 20:366-71.
5. Kregor PJ, Stannard J, Zlowodzki M, *et al.* Distal femoral fracture fixation utilizing the Less Invasive Stabilization System (L.I.S.S.): the technique and early results. *Injury.* 2001; 32:SC32-47.
6. Schutz M, Muller M, Regazzoni P, *et al.* Use of the Less Invasive Stabilization System (LISS) in patients with distal femoral (AO33) fractures: a prospective multicenter study. *Arch Orthop Trauma Surg.* 2005; 125(2):102-8.
7. Giles JB, DeLee JC, Heckman JD, *et al.* Supracondylar and intercondylar fractures of the femur treated with a supracondylar plate and lag screw. *J Bone Joint Surg* 1982;64-A:864
8. Hall MF. Two-Plane Fixation of acute supracondylar and intercondylar fractures of the femur. *South Med J.* 1978; 71:1474:111
9. Kregor PJ, Stannard JA, Zlowodzki M, *et al.* Treatment of Distal Femur Fractures Using the Less Invasive Stabilization System: Surgical Experience and Early Clinical Results in 103 fractures. *J Orthop Trauma.* 2004; 18(8):509-20.
10. Heather V, Theresa H, John S, *et al.* Failure of LCP condylar plate fixation in the distal part of the femur. *J Bone Joint Surg.* 2006; 88-A:846-53.