



ISSN Print: 2394-7500  
ISSN Online: 2394-5869  
IJAR 2015; 1(6): 21-23  
www.allresearchjournal.com  
Received: 01-04-2015  
Accepted: 29-04-2015

**Diguvinti. Sreeramulu**  
MD., Associate Professor of  
Medicine, Kurnool Medical  
College, Govt. General Hospital,  
Kurnool, Andhra Pradesh.

**Damam. Srinivasulu**  
MD., Assistant Professor of  
Medicine, Kurnool Medical  
College, Govt. General Hospital,  
Kurnool, Andhra Pradesh.

**Gundrathi. Vamshi Vihari**  
Resident in General Medicine,  
Kurnool Medical College, Govt.  
General Hospital, Kurnool,  
Andhra Pradesh.

**M. Sohail Malik**  
Resident in General Medicine,  
Kurnool Medical College, Govt.  
General Hospital, Kurnool,  
Andhra Pradesh.

**Correspondence:**

**Diguvinti. Sreeramulu**  
MD., Associate Professor of  
Medicine, Kurnool Medical  
College, Govt. General Hospital,  
Kurnool, Andhra Pradesh.

## A rare case of auto immune haemolytic anemia in anti-phospholipid antibody syndrome

**Diguvinti. Sreeramulu, Damam. Srinivasulu, Gundrathi. Vamshi Vihari, M. Sohail Malik**

### Abstract

A 24 years old female patient came to the causality with exertional breathlessness and jaundice, on examination she is gross pallor and blood is incompatible for blood transfusion on evaluation she diagnosed as auto immune haemolytic anemia. With history of recurrent pregnancy loss and on evaluation having retinal arteriolar thrombosis with laboratory support we diagnosed the case as Anti phospholipid antibody syndrome. Anti-phospholipid antibody syndrome is rare and its initial presentation with auto immune haemolytic anemia is rarer <sup>[1]</sup>, high level of suspicion is required to diagnose it.

**Keywords:** Auto Immune Haemolytic anemia, Anti Phospholipid antibody Syndrome, coomb's Test, Retinal Arterial Thrombosis

### 1. Introduction

Haemolytic anemia is due to several causes, commonly due to infections particularly malaria but in our case it is due to AIHA. On through evaluation patient having pregnancy loss and retinal artery thrombosis and laboratory conformed as aps. Where aps is less common with anti-pl (APL)-binding plasma protein antibodies occur only in 1–5% of general population <sup>[2]</sup>. We describe an incidental diagnosis of AIHA in a 24 yr old lady who is diagnosed as aps.

### 2. Case Proper

A 24 years old female patient came to the causality with exertional breathlessness and easy fatigability and discolouration of eyes since 10 days. She had previous history of two episodes first trimester abortions and her menstrual cycles were normal. On examination patient was severe anemic and jaundice present. Her cardiovascular and respiratory and nervous system examination was normal. There is no organomegaly per abdomen. Patient kept under diagnosis of severe haemolytic anemia for evaluation. Laboratory tests revealed complete blood picture showed haemoglobin 3.4 gr% white blood cells 5,000 per cmm (70% neutrophils, 20% lymphocytes) platelets 2,00,000 per cmm. MCV was 81 fl and MCH 31.4 pg. Reticulocyte count was 12 % with reticulocyte production index > 2.2. Peripheral smear revealed reticulocytes, macrocytes, polychromasia, and nucleated red cells. Fundus examination showed retinal arteriolar thrombosis. Urine examination showed red cells. Coombs test both direct and indirect were positive. All blood units kept for cross matching were incompatible. At this point we suspected APS and send antibodies against beta 2 glycoprotein I (2GPI), cardiolipin (CL), lupus anticoagulant (LA) and phospholipid/cholesterol complexes <sup>[3]</sup>. Results include serum phospholipid antibody 32.17U/ml, lupus anticoagulant 63.90 seconds which were elevated and cardiolipin antibodies are within normal limits. Anti-nuclear antibodies and anti-ds DNA ab were negative. By this patient conformed as acute episode of auto immune haemolytic anemia with primary APS. Blood sugar (random), urea and creatinine levels were 78 mg%, 22 mg% and 0.6 mg% respectively. Liver function test revealed total bilirubin of 4.8 mg% with indirect fraction 2.8 mg%, SGOT 28 IU/L, SGPT 18 IU/L, albumin 4.0 gm% and globulin 3.6 gm%. Prothrombin time was 14.0 seconds with INR of 1.21. Serum lactate dehydrogenase (LDH) was 2618 IU/L (normal 115-221 IU/L). Viral serology of hepatitis B and C was negative. Serum anti-nuclear factor was negative. Ultrasonography of abdomen normal. We kept patient on prednisolone 1 mg/kg body weight /day. Patient had drastic response within two days. Then we slowly tapered prednisolone. After 12 weeks we repeated serum phospholipid antibody, lupus anticoagulant which were elevated suggestive of APS.

### 3. Discussion

Antiphospholipid antibody syndrome (APS) is an autoantibody-mediated acquired thrombophilia characterized by recurrent arterial or venous thrombosis and/or pregnancy morbidity in the presence of autoantibodies against phospholipid (PL)-binding plasma proteins, mainly a plasma apolipoprotein known as beta 2 glycoprotein I (beta2GPI) and prothrombin. Trigger for the induction of antibodies to PL-binding proteins is not known. Preceding infections, however, have been proposed as the initiating event<sup>4</sup>. Antibodies are pathogenic since anti-beta2GPI/beta2GPI complexes inactivate natural anticoagulants such as protein C. Activated protein C (APC) binds the pro-coagulant factors VA and VIIIa and inactivates them. Anti-2GPI/2GPI complexes inhibit the APC activity in vivo by competing with the components of the APC/VA/VIIIa complexes for binding to a number of PL-binding sites, or by disrupting these complexes. Clinical manifestations represent mainly a direct or indirect expression of venous or arterial thrombosis and/or pregnancy morbidity.

Clinical criteria include:

- (1) Vascular thrombosis defined as one or more clinical episodes of arterial, venous, or small vessel thrombosis in any tissue or organ; and
- (2) pregnancy morbidity, defined as (a) one or more unexplained deaths of a morphologically normal fetus at or beyond the tenth week of gestation, or (b) one or more premature births of a morphologically normal neonate before the thirty-fourth week of gestation because of eclampsia, severe preeclampsia, or placental insufficiency; or (c) three or more unexplained consecutive spontaneous abortions before the 10th week of gestation. Laboratory criteria include (1) LA, (2) anticardiolipin (ACL) and/or
- (3) Anti-BETA2GPI antibodies, at intermediate or high titers on two occasions, 12 weeks apart. Differential diagnosis is based on the exclusion of other inherited or acquired causes of thrombophilia, Coombs positive hemolytic anemia, and thrombocytopenia.

#### Autoimmune haemolytic anaemia <sup>[5]</sup>

The incidence of warm autoimmune haemolysis is approximately 1/100 000 population per annum; it occurs at all ages but is more common in middle age and in females. Diagnosis is confirmed by the direct Coombs or antiglobulin test <sup>[5]</sup>

#### 4. Treatment

After the first thrombotic event, APS patients should be placed on warfarin for life aiming to achieve an international normalized ratio (INR) ranging from 2.5 to 3.5, alone or in combination with 80 mg of aspirin daily. Pregnancy morbidity is prevented by a combination of heparin with aspirin 80 mg daily. Intravenous immunoglobulin (IVIg) 400 mg/kg qd for 5 days may also prevent abortions, while glucocorticoids are ineffective. Patients with CAPS have recurrent thrombotic events despite appropriate anticoagulation. In these cases IVIg 400 mg/kg qd for 5 days or anti-CD20 monoclonal antibody 375 mg/m<sup>2</sup> per week for 4 weeks may be of benefit.

Apart from emergency blood transfusion, the first-line treatment of AIHA is by using corticosteroids. In at least one-half of the cases, prednisone (1 mg/kg per day) will produce a remission promptly <sup>[5]</sup>. Whereas some patients are then apparently cured, relapses are not uncommon.

Who do not respond and for those who have relapsed (or who require more than 15 mg/d of prednisone to prevent relapse), it

is highly recommended to consider a second-line treatment option, which might be either splenectomy <sup>[5]</sup> or rituximab (anti-CD20). Rituximab has emerged as a significant alternative to splenectomy because it can produce remissions in up to 80% of patients. And it is showing Sustained response to rituximab of autoimmune hemolytic anemia associated with antiphospholipid syndrome <sup>[6]</sup>

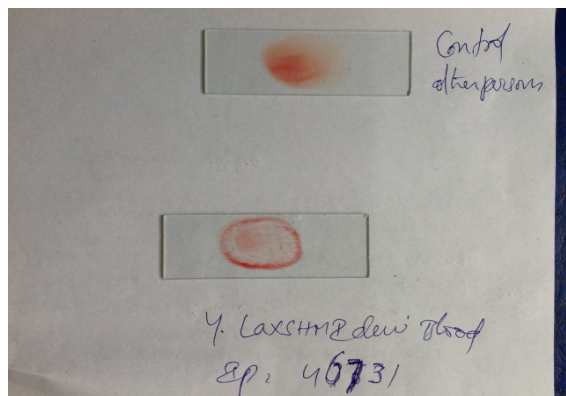


Fig 1: Showing comb's positive to patient in blood

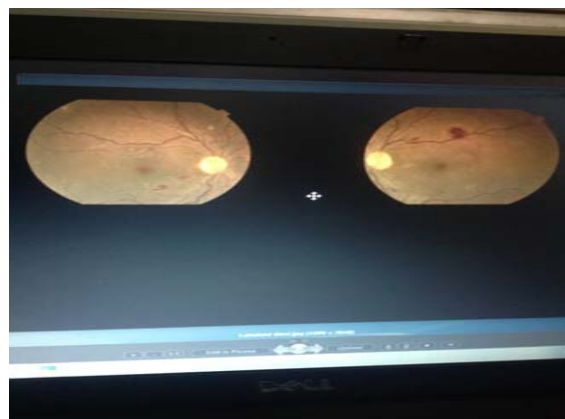

Fig 2: Showing Retinal Arterial thrombosis patient in Fundus examination

#### 5. Conclusion

Anti-phospholipid antibody syndrome is a rare auto antibody mediated acquired disorder characterized by recurrent arterial or venous thrombosis and pregnancy morbidity in the presence of autoantibodies against phospholipid. Occurrence of auto immune haemolytic anemia is very rare complication in APS. In our country where pregnancy morbidity is more and anemia is much more common need through evaluation to rule out APS, This patients also more predilection for thrombosis so need to search for thrombosis in various organs which need lifelong anti coagulation, by thorough evaluation we found that this patient having retinal vein thrombosis and AIHA.

#### 6. Reference

1. Suhail S<sup>1</sup>, Baig MS, Humail SM, Riaz A. Primary antiphospholipid antibody syndrome and autoimmune haemolytic anaemia--a rare combination J Pak Med Assoc 2009; 59(6):413-4.
2. Harrison's<sup>TM</sup>. Principles of Internal Medicine Eighteenth Edition, 2012, 320.
3. Rawat A<sup>1</sup>, Sikka M<sup>1</sup>, Rusia U<sup>1</sup>, Guleria K<sup>2</sup>. Lupus anticoagulants and anticardiolipin antibodies in Indian women with spontaneous, recurrent fetal loss. Indian J Hematol Blood Transfus 2015; 31(2):281-5.

4. Tadej Avčin, MD, PhD, Nataša Toplak, MD  
Antiphospholipid Antibodies in Response to Infection  
Current Rheumatology Reports 2007, 9:212-218.
5. Davidson's Practice of Principles & practice of Medicine  
22<sup>nd</sup> Edition 2014, 1029-1030.
6. Erdozain JG<sup>1</sup>, Ruiz-Iratorza G, Egurbide MV, Aguirre C.  
Sustained response to rituximab of autoimmune hemolytic  
anemia associated with antiphospholipid syndrome.  
Haematologica 2004; 89(9):ECR34.