



ISSN Print: 2394-7500  
ISSN Online: 2394-5869  
IJAR 2015; 1(6): 268-270  
www.allresearchjournal.com  
Received: 10-03-2015  
Accepted: 12-04-2015

**Dr. M. Nirmala**  
M.S. Ophthalmology,  
Assistant professor,  
Guntur Medical College,  
Guntur., India

**Dr. M. Vijaya Leela**  
M.S. Ophthalmology,  
Assistant Professor, Guntur  
Medical College,  
Guntur., India

**Dr. D. Udaya Kumar M.S. (Oph),**  
Professor of Ophthalmology,  
Guntur Medical College,  
Guntur., India

**Dr. V. Swapna Latha**  
PG in Ophthalmology,  
Guntur Medical College,  
Guntur., India

**Correspondence:**  
**Dr. V. Swapna Latha**  
PG in Ophthalmology,  
Guntur Medical College,  
Guntur., India

## **Kayser Fleischer ring in chronic liver disease, a case report and survey of literature**

**M. Nirmala, M. Vijaya Leela, D. Udaya Kumar, V. Swapna Latha**

### **Abstract**

A 16 yr old female presenting with bilateral Kayser Fleischer ring on slit lamp examination. There were coexisting neurological and hepatic symptoms. Her CT brain and MRI brain reports were abnormal. Ultrasound abdomen revealed coarse echotexture of liver, suggesting of chronic liver disease, and splenomegaly. Blood reports showing decreased serum ceruloplasmin and increased serum copper levels. We report an interesting case of Wilsons disease with coexisting neurological and hepatic symptoms, and characteristic ophthalmic manifestation, where the diagnosis of this condition plays a crucial role in the management and follow up.

**Keywords:** Kayser Fleischer ring, in a case of chronic liver disease.

### **Introduction**

Here we are presenting a case of Kayser Fleischer ring, in chronic liver disease.

**Case Report:** A 16 yr old female, second in birth order, born out of consanguineous marriage, presented with involuntary movements of both upper limbs, dragging of feet while walking, drooling of saliva, slurring of speech, since six months. Patient was apparently asymptomatic six months before, when she developed insidious onset of tremulousness of both hands which is present while trying to reach an object. She also developed episodes of stiffness of the body with abnormal posturing. Her speech had become slurred and lacked clarity. She however retained the ability to understand what has been told to her. She became euphoric and presented with a vacuous smile over her face. She has also become incapable of analyzing and understanding things as before. Her ability to perform activities of daily living also got impaired.

**On ocular examination:** Visual acuity in both eyes was 6/6, anterior chamber and pupil normal, and extraocular movements were normal.

**Slit lamp examination** revealed the presence of bilateral pronounced greenish brown Kayser Fleischer. Gonioscopy also showed the greenish brown pigmentation on trabecular meshwork extending upto schwalbe's line. Fundus examination: both eyes normal.

Investigations done include:

**CT Brain:** revealed extensive movement of artifacts noted, calcific dense focus noted in the left temporal region, suggestive of calcified granuloma. Irregular hypodense area noted in left frontoparietal region suggestive of edema.

**Plain and contrast enhanced MRI of brain:** revealed -Altered signal intensities in the bilateral capsuloganglionic regions and thalamic hypoxic old hypoxic injury sequelae. Focal non enhancing right frontal cortical and adjacent white matter altered signals, with mass effect on adjacent sulci. Moderate diffuse cerebellar atrophy.

**Ultrasound abdomen,** which revealed normal sized liver with altered echotexture, enlarged spleen of 13 cm size, others normal, giving the impression of chronic liver disease with splenomegaly.

Serum copper was 30 micrograms/ml, 24 hrs urinary copper excretion was 102 micrograms/ml, serum ceruloplasmin was 10 micrograms/ml.

**Renal functions tests:** Blood urea: 38 mg%, serum creatinine: 0.9 mg%,

**Liver function tests:** serum bilirubin: 0.9 mg%, SGPT: 32 IU, SGOT: 26 IU, total proteins 7.6 mg%, albumen 4.2 gm%, globulins 3.4 gm%, serum alkaline phosphatase: 11.0 KA.

RBS: 108 mg%,

HIV, HBsAg: also done.

### Discussion

**Wilson Disease:** Inherited as an autosomal recessive metabolic defect linked to chromosome 13q14.3- q21.1, Wilson disease, or *hepatolenticular degeneration*, is caused by multiple allelic substitutions or deletions in DNA are coding for an ATPase, Cu<sup>2+</sup>-transporting, ~-polypeptide.

**PATHOGENESIS** Copper is deposited in the liver, then in the kidneys, and eventually in the

### Brain and the cornea at Descemet's membrane

**Pathophysiology:** Wilson Disease is caused by mutation in the copper-transporting gene ATP7B on chromosome 13, which facilitates the transfer of copper into the Golgi apparatus where it combines with ceruloplasmin or other proteins like cytochrome oxidase. Failure of this process leads to instability and decreased half life of ceruloplasmin and paradoxical ceruloplasmin deficiency. The free circulating copper (which is toxic as it inhibits enzymatic processes) accumulates in liver cytosol resulting in hepatocyte degeneration and cirrhosis. When the sites for copper binding in the liver are saturated, free copper is released into the circulation and accumulates in other tissues like the eye, brain (basal ganglia) and kidneys amongst others leading to morphological changes, functional rearrangements and clinical manifestations. Wilson disease has variable presentations with hepatic or neuropsychiatric manifestations or sometimes presymptomatic patients present with Kayser Fleischer ring. Wilson disease has an incidence of 1 in 30,000.

### Kayser Fleischer Ring

The ring is reported more frequent in H1069Q (most frequent mutation in Wilson Disease in Hungary) homozygous patients, with higher mean age at diagnosis than patients heterozygous or negative for H1069Q. This may suggest a genetic predisposition. Kayser-Fleischer ring was first described by Bernhard kayser [1902] and Bruno Fleischer [1903]. It is present in 95% of patients with neurologic symptoms. It is seen in only 40% of pre symptomatic patients, and in 65-70% of patients with hepatic manifestations. In children presenting with liver disease, Kayser-Fleischer rings are usually absent.

The K-F ring is believed to be formed by the copper particles which infiltrate into Descemet's membrane through the endothelial cells from the aqueous humor. The smaller particles coalesce over a period of time to give rise to larger deposits, granules which may or may not be in zones. This 'corneal chelate' accounts for the K-F ring. It is seen simultaneously in both eyes, when associated with systemic disorders. However, Innes *et al.* have reported a case of unilateral K-F ring in a patient with Wilson Disease. This patient had a scarred eye (with low intraocular pressure and reduced aqueous production) which did not show the K-F ring. Hence they postulated that the copper deposition is through the

aqueous (which was markedly reduced in the scarred eye), rather than limbal circulation (which was normal in the scarred eye). Moreover, it may not be just due to passive diffusion, but may be attributed to cellular activity, the copper granule production being related to formation of the basement membrane by endothelial cells.

The density of Kayser Fleischer ring correlates with the severity of disease. They are not entirely specific for Wilson's disease, since they may be found in patients with chronic cholestatic diseases. K F ring could fade or disappear with chelation [80-90%] or liver transplantation. The ring tends to disappear in the reverse order of its formation. But it is not a good predictor of clinical improvement. It's reappearance while on therapy indicates noncompliance.

**Clinical Findings:** The disease usually manifests clinically after the age of six years, with hepatitis, cirrhosis, tremors, disturbance in gait, dysarthria, and/or psychiatric disturbance. Muscular rigidity increases, and tremor and involuntary movement, gradually occur in a fluctuating course resembling parkinsonism. Unintelligible speech and mild dementia usually occur concomitantly. Equal numbers of patients (40%) present with hepatic or nervous system symptoms. In the cornea, a golden brown, ruby red, or green pigment ring (Kayser-Fleischer ring) appears in peripheral Descemet's membrane. Not all patients with bonafide Wilson disease will manifest a Kayser-Fleischer ring, which appears first superiorly, gradually spreading and widening to meet deposits inferiorly. It consists of deposits of copper in the posterior lamella of Descemet's membrane.

Gonioscopy may assist in visualizing the ring. A "sunflower" cataract may be present.

**The differential diagnosis** includes primary biliary cirrhosis, chronic active hepatitis, exogenous chalcosis, and progressive intrahepatic cholestasis of childhood.

These and **other non-Wilsonian hepatic disorders can also be associated with Kayser-Fleischer rings, but only Wilson disease has decreased serum ceruloplasmin and neurologic symptoms.**

### Laboratory Evaluation Patients with Wilson disease can be differentiated from patients

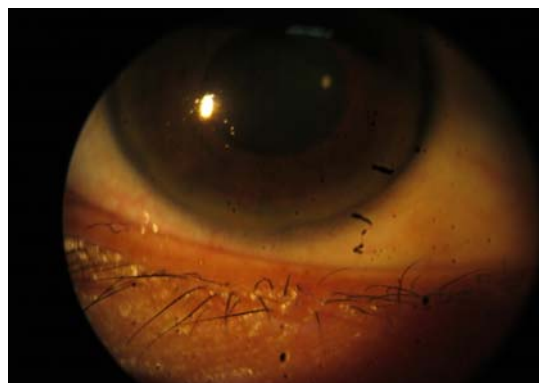
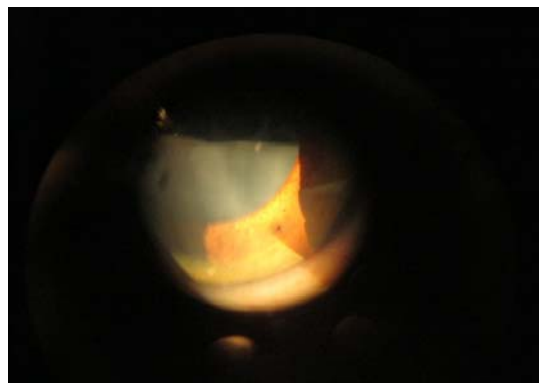
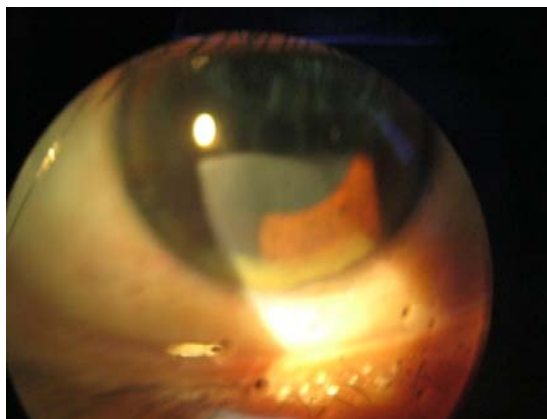
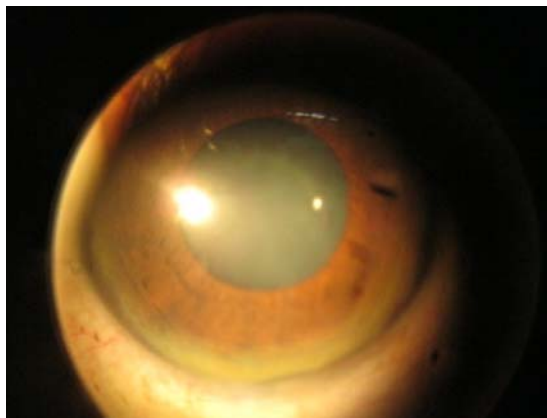
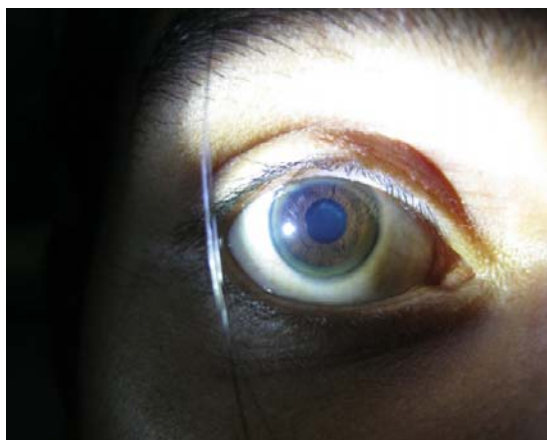With other diseases that show Kayser-Fleischer rings by their inability to incorporate **radioactive copper into ceruloplasmin. Low serum ceruloplasmin levels of less than 20mg/dl, high nonceruloplasmin bound serum copper, and high urinary copper** suggest the diagnosis, which can be established with liver biopsy. Nonspecific findings of proteinuria, aminoaciduria, glycosuria, uricaciduria, hyperphosphaturia, and hypercalciuria are seen.

### Importance of Kayser Fleischer Ring

Identification of the K-F ring in any patient with unexplained central nervous system disease, poorly categorized psychiatric disorder, abnormal liver function tests, chronic active hepatitis, cirrhosis of liver, rickets, renal tubular acidosis, unexplained Coomb's negative hemolytic anaemia, especially if there is a relation with WD or any of the conditions mentioned above should prompt the physician to undertake diagnostic workup for WD. At times, the K-F ring could be the first detectable manifestation of WD and in such rare instances, ophthalmologists play a critical role in the early recognition of WD. Larger K-F ring size may correlate with the severity of the disease, but not necessarily with the magnitude of urinary

copper excretion. It is one of the clinical parameters used in monitoring patients on therapy, although its reduction is not necessarily a good predictor of clinical improvement. Its reappearance while on therapy may indicate non-compliance. Kayser-Fleischer ring detection is one of the screening tests for first-degree relatives of a WD index case. Early detection and treatment of WD may prevent the associated morbidity and mortality of the disease.

**Management:** Wilson disease can be treated with penicillamine. Penicillamine or trientine is usually the first line of therapy and are replaced with zinc preparations later as maintenance therapy. The Kayser-Fleischer ring disappears gradually with therapy, including liver transplantation, and the disappearance of the rings can be used to help monitor therapy. Recently, electrophysiologic abnormalities from retinal dysfunction have been shown to reverse after disease treatment.



**4. Conclusion:** Wilson disease is a rare condition caused by deficiency of ceruloplasmin resulting in widespread deposition of copper in tissues. The characteristic pigmentation of the cornea in the form of Kayser-Fleischer ring, decreased serum ceruloplasmin levels and neurological symptoms, which were present in this case, clinch the diagnosis of Wilson's disease.

**5. References**

1. Parsons' diseases of the eye. Twenty first edition.
2. American academy of ophthalmology, 2011-2012.
3. Kim HB, Kim JC, Byan YJ. Kayser Fleischer ring in Wilson's disease. J Korean Ophthal Soc 1979; 20:129-31.
4. Innes JR, Strachan IM, Triger DR. Unilateral Kayser-Fleischer ring. Br J Ophthalmol 1986; 70:469-70.
5. Albert and Jakobiec's, principles and practice of ophthalmology, volume two, 2<sup>nd</sup> edition.
6. Krachmer Mannis Holland, volume two, 2<sup>nd</sup> edition.
7. Belkin M, Zeimer R, Chajek T, Friedman G, Melamed E. Non-invasive quantitation of corneal copper in hepatolenticular degeneration (Wilson's disease). Lancet 1976; 1:391-4.