



ISSN Print: 2394-7500
ISSN Online: 2394-5869
Impact Factor: 5.2
IJAR 2015; 1(7): 175-178
www.allresearchjournal.com
Received: 01-04-2015
Accepted: 02-05-2015

Rajesh Gupta

Sr. Lecturer, Department of Oral Medicine and Radiology, Swami Devi Dyal Hospital & Dental College, Haryana (India).

Preeti Gupta

Sr. Lecturer, Department of Public Health Dentistry, Swami Devi Dyal Hospital & Dental College, Haryana (India).

Shivani Gupta

Sr. Lecturer, Department of Oral Medicine and Radiology, Swami Devi Dyal Hospital & Dental College, Haryana (India).

Correspondence:

Rajesh Gupta

Sr. Lecturer, Department of oral medicine and radiology, Swami Devi Dyal Hospital & Dental College, Haryana-134118 India

Complications of Herpes Zoster: A review

Rajesh Gupta, Preeti Gupta, Shivani Gupta

Abstract

Herpes zoster, or shingles, is a localized disease characterized by unilateral radicular pain and a vesicular rash limited to the area of skin innervated by a single dorsal root or cranial sensory ganglion. Whereas varicella, or chickenpox, results from primary exogenous varicella-zoster virus (VZV) infection, herpes zoster is caused by reactivation of endogenous VZV that has persisted in latent form within sensory ganglia following an earlier episode of chickenpox. In contrast to recurrent herpes simplex, herpes zoster is commonly associated with severe pain: prodromal pain often precedes the rash by several days; pain usually accompanies the dermatomal rash of herpes zoster; and many debilitating complications like *postherpetic neuralgia* (PHN). The incidence and severity of herpes zoster and its complications increase with age in association with an age-related decline in cell-mediated immunity to VZV.

Keywords: Complications, Herpes Zoster.

1. Introduction

Complications of herpes zoster can be classified as [1]:-

- Post herpetic neuralgia
- Encephalitis
- Herpes ophthalmicus
- Myelitis
- Retinitis
- Post herpetic itch

1. Post Herpetic Neuralgia.

In some patients, the pain does not resolve even after the resolution of herpes zoster rash but rather it continues for months or years. This resisting pain is termed as post herpetic neuralgia and it is the most common complication of herpes zoster. Patients typically describe this pain with different characteristics including continuous burning or throbbing pain, intermittent sharp or electric shock-like pain and allodynia [1]. Although multiple definitions of post herpetic neuralgia have been used, the results of recent studies suggest that pain persisting for at least 120 days after the rash onset may be considered to be a validated definition of post herpetic neuralgia for research purposes [2, 3]. There have been no systematic attempts to investigate the prevalence of post herpetic neuralgia and estimates of such cases in the United States have ranged up to 1 million [4]. Numerous studies have established that older age is a potential risk factor for post herpetic neuralgia. It may also lead to exaggeration of acute pain intensity, severity of the rash and presence of greater severity of a painful prodrome preceding the rash [5, 6].

There is considerable agreement that both peripheral and central processes can contribute to post herpetic neuralgia. For example, the patients with prominent allodynia often have minimal sensory loss and report pain relief after local application of analgesics. This suggests that preserved and possibly sensitized primary afferent nociceptors that remain connected to the skin and their chronically sensitized central targets are responsible for initiating and maintaining pain and allodynia in these patients [7, 8].

Pathologic findings associated with post herpetic neuralgia include degeneration of affected primary afferent neuronal cell bodies and axons, atrophy of the spinal cord dorsal horn, scarring of the dorsal root ganglion and loss of epidermal innervations. All of these stated findings are more prominent on the affected side [9].

Post herpetic neuralgic pain has substantial effects on quality of life and physical disability. Such patient may lead to emotional distress ^[10]. The US Food and Drug Administration has approved 3 medications for the treatment of post herpetic neuralgia which are as follows:-

1. Gabapentin
2. Lidocaine patch
3. Pregabalin

The results of randomized controlled trials have also demonstrated the efficacy of tricyclic antidepressants (TCAs) and opioid analgesics in the treatment of post herpetic neuralgia ^[11, 12]. Nevertheless, a substantial percentage of patients are often refractory to these treatments used alone or in combination ^[13]. However those patients require treatment in the settings specialized in pain management.

2. Encephalitis.

Encephalitis is an acute inflammation of the brain (figure 1)

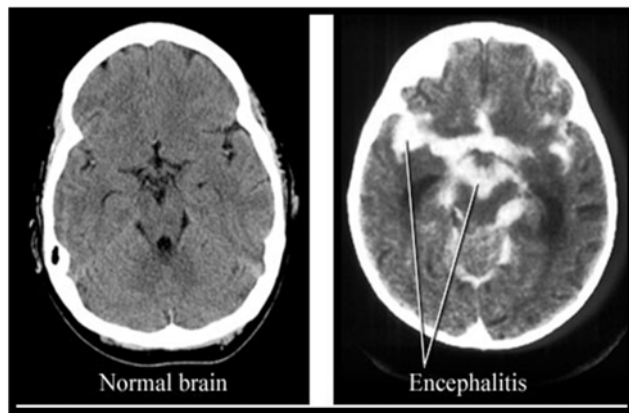


Fig 1: showing encephalitis

It is a rare complication of herpes zoster that usually occurs a few days after onset of rash ^[94]. Symptoms may include headache, fever, confusion, drowsiness and fatigue. More advanced and serious symptoms include seizures or convulsions. However, it should be recognized that cerebrospinal fluid pleocytosis is present in almost 50% of individuals with uncomplicated herpes zoster. This reflects the local leptomeningitis that regularly accompanies the disease. Encephalitis has occasionally been documented in the absence of apparent cutaneous herpes zoster and in patients who has received appropriate antiviral therapy during the acute episode of herpes zoster. The rates of death due to herpes zoster-associated encephalitis vary upto 25% depending upon the extent to which the patient is immunocompromised. The average mortality rate observed in such patients is 10% ^[14]. Henceforth, the immunocompromised patients are at an increased risk for the development of encephalitis ^[15].

Other markers of increased risk for CNS involvement include HZ in a cranial nerve dermatome or the presence of cutaneous dissemination.

Chronic varicella zoster virus encephalitis is seen almost exclusively in immunocompromised patients, especially patients with AIDS who have marked depletion of CD4+ T

cells ^[16]. The onset of encephalitis may occur months after an episode of herpes zoster. 30%– 40% of these patients have no recognized history of cutaneous varicella zoster virus infection which makes the diagnosis more difficult. The clinical presentation is usually subacute with headache, fever, mental status changes and seizures. Patients may have focal neurologic defects including aphasia, hemiplegia and visualfield cuts ^[17, 18, 19]. Patients often have a clinical course of progressive deterioration and death although anecdotal reports have suggested some benefit from high-dose intravenous acyclovir therapy ^[20].

3. Herpes Zoster Ophthalmicus

Herpes zoster ophthalmicus (HZO), or ocular shingles is caused by reactivation of the chicken pox virus. The condition produces a striking picture with a blistering and crusting rash confined to well-demarcated areas of the body (figure 2). Herpes zoster can occur anywhere in the body but is unfortunately common on the face and in and around the eye. Some serious complications can result if this occurs in the eye ^[21].

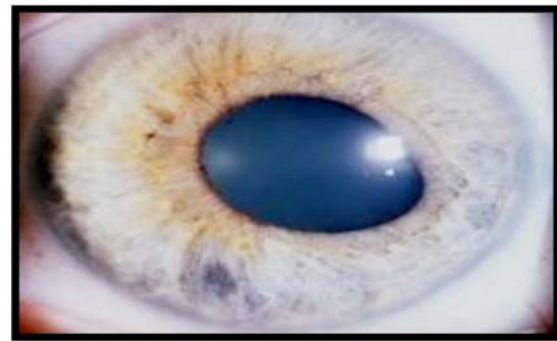


Fig 2: Showing herpes zoster ophthalmicus

HZO usually starts with pain or tingling feelings on the scalp, forehead and face on one side. Generally the rash appears within a few hours to days after the sensation of pain or tingling has begun. Rarely, there may be pain and tingling with ocular complications without a rash ever appearing (herpes zoster sine herpeticum). The rash of HZO begins as a reddening of the skin followed by the appearance of fluid-filled blisters that quickly rupture and crust over. These crusted lesions take days to weeks to resolve and may result in significant scarring ^[22, 23].

4. Herpes Zoster Myelitis.

Herpes zoster myelitis is thought to result from direct invasion of the spinal cord by varicella zoster virus, with virus spreading along central axons of infected primary sensory neurons (figure 3). As in the brain, there is close neuronal packing, this allows spread of virus to adjacent neurons. Involvement of descending spinothalamic tracts or of anterior horn can cause weakness while involvement of ascending sensory tracts (posterior column or lateral spinothalamic tract) causes sensory loss at levels below the affected dermatome ^[24].

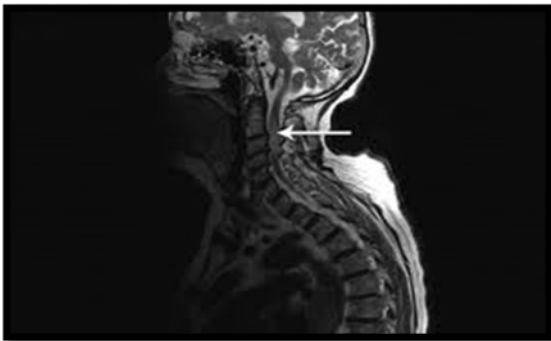


Fig 3: Herpes zoster myelitis is thought to result from direct invasion of the spinal cord by varicella zoster virus, with virus spreading along central axons of infected primary sensory neurons

In severe cases, the myelopathy can progress to a partial Brown-Se'quard syndrome or total cord transection. Myelitis most often follows thoracic herpes zoster with weakness developing in the same spinal cord segment as the rash. Neurologic symptoms begin to develop an average of 12 days after the onset of the rash [25]. However, varicella zoster virus myelitis in patients with no history of antecedent herpes zoster has also been reported [26].

Immunocompromised patients are at increased risk for post-herpes zoster myelitis and the syndrome is well described in patients with AIDS [27]. The most common initial manifestation is bladder dysfunction (e.g. urinary retention) which is often accompanied by weakness of the lower extremities, asymmetric reflexes and sensory disturbances. Magnetic resonance imaging has been useful in diagnosing myelitis, with abnormal signal evident in the cord at the level of inflammation [28].

5. Herpes Zoster Retinitis

Retinitis is inflammation of the retina in the eye, which may lead to blindness. The retinitis begins with multifocal necrotizing lesions involving the peripheral retina (figure 4).

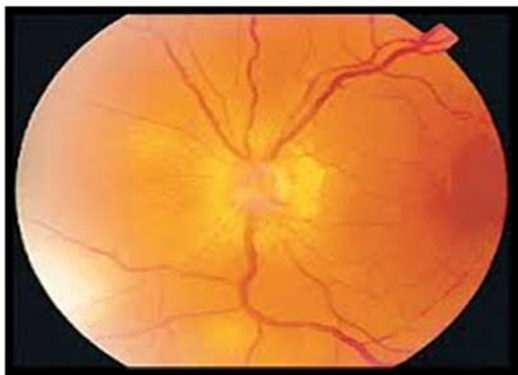


Fig 4: The retinitis begins with multifocal necrotizing lesions involving the peripheral retina

Acute retinal necrosis (ARN) caused by varicella zoster virus has been described in immunocompetent patients while more aggressive variants of this disease have been recognized in immunocompromised patients (eg AIDS). This may progress to outer retinal necrosis [29] and rapidly progressive herpetic retinal necrosis (RPHRN).

Patients with ARN usually complain of floaters, photophobia and decrease in visual acuity in one eye. Pain may be a

prominent feature but is often absent. If left untreated, within a month the eye may get involved in one-third of patients. Retinitis may appear several decades after the initial presentation of the disease. The goals of treatment of ARN are:-

1. To stop the retinal necrosis in order to avoid the late consequences of the disease (retinal detachment and optic atrophy)
2. To minimize the collateral damage caused by severe inflammation and vascular occlusions
3. To protect the fellow eye. Antiviral therapy should begin immediately after the clinical diagnosis is made [30, 31, 32].

6. Post Herpetic Itch (Pruritis)

Like pain, pruritis does not persist after the resolution of herpes zoster. [33] Postherpetic itch can occur along with postherpetic neuralgia. Patients with chronic pruritis report substantial disability not only because of the unpleasant sensations but also because of the disruptive need to scratch which is virtually impossible to ignore. The combination of chronic pruritis and profound sensory loss after herpes zoster leads to rare cases of severe self-injury when the protective pain sensations that deter prolonged scratching are lost [34].

References

1. Dworkin RH, Portenoy RK. Pain and its persistence in herpes zoster. *Pain* 1996; 67:241-51.
2. Arani RB, Soong SJ, Weiss HL. Phase specific analysis of herpes zoster associated pain data: a new statistical approach. *Stat Med* 2001; 20:2429-39.
3. Desmond RA, Weiss HL, Arani RB. Clinical application for change-point analysis of herpes zoster pain. *J Pain Symptom Manage* 2002; 23:510-6.
4. Bowsher D. The lifetime occurrence of herpes zoster and prevalence of postherpetic neuralgia: a retrospective survey in an elderly population. *Eur J Pain* 1999; 3:335-42.
5. McKendrick MW, Wood MJ. Acyclovir and post-herpetic neuralgia: two other participating centres report different results. *BMJ* 1995; 310:1005.
6. Dworkin RH, Schmader KE. The epidemiology and natural history of herpes zoster and postherpetic neuralgia. In: Watson CPN, Gershon AA, eds. *Herpes zoster and postherpetic neuralgia*. 2nd ed. New York: Elsevier Press, 2001, 39-64.
7. Fields HL, Rowbotham M, Baron R. Postherpetic neuralgia: irritable nociceptors and deafferentation. *Neurobiol Dis* 1998; 5:209-27.
8. Petersen KL, Fields HL, Brennum J, Sandroni P, Rowbotham MC. Capsaicin evoked pain and allodynia in post-herpetic neuralgia. *Pain* 2000; 88:125-33
9. Oaklander AL, Romans K, Horasek S, Stocks A, Hauer P, Meyer RA. Unilateral postherpetic neuralgia is associated with bilateral sensory neuron damage. *Ann Neurol* 1998; 44:789-95
10. Kashiwase M, Sata T, Yamauchi Y. Progressive outer retinal necrosis caused by herpes simplex virus type 1 in a patient with acquired immunodeficiency syndrome. *Ophthalmology* 2000; 107:790-4.
11. Dubinsky RM, Kabbani H, El-Chami Z, Boutwell C, Ali H. Practice parameter: treatment of postherpetic neuralgia: an evidence-based report of the Quality Standards Subcommittee of the American Academy of Neurology. *Neurology* 2004; 63:959-65.

12. Hempenstall K, Nurmikko TJ, Johnson RW, A'Hern RP, Rice AS. Analgesic therapy in postherpetic neuralgia: a quantitative systematic review. *PLoS Med* 2005; 2:164.
13. Gilron I, Bailey JM, Dongsheng T, Holden RR, Weaver DF, Houlden RL. Morphine, gabapentin, or their combination for neuropathic pain. *N Engl J Med* 2005; 352:1324-34.
14. Jemsek J, Greenberg SB, Taber L, Harvey D, Gershon A, Couch RB. Herpes zoster-associated encephalitis: clinicopathologic report of 12 cases and review of the literature. *Medicine* 1983; 62:81-97.
15. Hughes BA, Kimmell DW, Aksamit AJ. Herpes-zoster associated meningoencephalitis in patients with systemic cancer. *Mayo Clin Proc* 1993; 68:652-5.
16. Blanchardiere A, Rozenberg F, Caumes E. Neurological complications of varicella-zoster virus infection in adults with human immunodeficiency virus infection. *Scand J Infect Dis* 2000; 32:263-9.
17. Amlie-Lefond C, Kleinschmidt-Demasters BK, Mahalingam R, Davis LE, Gilden DH. The vasculopathy of varicella-zoster virus encephalitis. *Ann Neurol* 1995; 37:784-90.
18. Aygun N, Finelli DA, Rodgers MS, Rhodes RH. Multifocal varicellazoster virus leukoencephalitis in a patient with AIDS: MR findings. *Am J Neuroradiol* 1998; 19:1897-9
19. Kleinschmidt-DeMasters BK, Amlie-Lefond C, Gilden DH. The patterns of varicella zoster virus encephalitis. *Hum Pathol* 1996; 27:927-38.
20. Poscher ME. Successful treatment of varicella-zoster virus meningoencephalitis in patients with AIDS: report of 4 cases and review. *AIDS* 1994; 8:1115-7.
21. Moriuchi H, Rodriguez W. Role of varicella-zoster virus in stroke syndromes. *Pediatr Infect Dis J* 2000; 19:648-53.
22. Eidelberg D, Sotrel A, Horoupian DS, Neumann PE, Pumarold RW. Thrombotic cerebral vasculopathy associated with herpes zoster. *Ann Neurol* 1986; 19:7-14.
23. Reshef E, Greenberg SB, Jankovic J. Herpes zoster ophthalmicus followed by contralateral hemiparesis: report of two cases and review of literature. *J Neurol Neurosurg Psychiatry* 1985; 48:122-7.
24. Gilden DH, Beinlick BR, Rubinstein EMI. Varicella-zoster virus myelitis: an expanding spectrum. *Neurology* 1994; 44:1818-23.
25. Devinsky O, Cho ES, Petite CK, Price RW. Herpes zoster myelitis. *Brain* 1991; 114:1181-96.
26. Grant AD, Fox JD, Brink NS, Miller RF. Detection of varicella-zoster virus DNA using the polymerase chain reaction in an immunocompromised patient with transverse myelitis secondary to herpes zoster. *Genitourin Med* 1993; 69:273-5.
27. Manian FA, Kindred M, Fulling KH. Chronic varicella-zoster virus myelitis without cutaneous eruption in a patient with AIDS: report of a fatal case. *Clin Infect Dis* 1995; 21:986-8.
28. Hwang YM, Lee BI, Chung JW, Ahn JH, Kim KW, Kim DI. A case of herpes zoster myelitis: positive magnetic resonance imaging finding. *Eur Neurol* 1991; 31:164-7.
29. Engstrom RE, Holland GN, Maryolis TP. The progressive outer retinal necrosis syndrome: a variant of necrotizing herpetic retinopathy in patients with AIDS. *Ophthalmology* 1994; 101:1488-502.
30. Ormerod LD, Larkin JA, Margo CA. Rapidly progressive herpetic retinal necrosis: a blinding disease characteristic of advanced AIDS. *Clin Infect Dis* 1998; 26:34-45.
31. Batisse D, Eliaszewicz M, Zazoan L, Baudrimont M, Pialoux G, Dupont B. Acute retinal necrosis in the course of AIDS: study of 26 cases. *AIDS* 1996; 10:55-60.
32. Text Book of Dermatology, 7th Edition, By Tony Burns, Stephen Breathnaeb Nellcox, Christopher Griffith. *Zoster* 2, 25-27.
33. Oaklander AL, Bowsher D, Galer BS, Haanpa'a ML, Jensen MP. Herpes zoster itch: preliminary epidemiologic data. *J Pain* 2003; 4:338-43.
34. Oaklander AL, Cohen SP, Raju SV. Intractable postherpetic itch and cutaneous deafferentation after facial shingles. *Pain* 2002; 96:9-12.