



ISSN Print: 2394-7500  
ISSN Online: 2394-5869  
Impact Factor: 5.2  
IJAR 2015; 1(7): 310-311  
www.allresearchjournal.com  
Received: 11-04-2015  
Accepted: 15-05-2015

**Dr. D. Udayakumar M.S**  
Professor of ophthalmology,  
Guntur medical College,  
Guntur

**Dr. M. Nirmala M.S**  
Assistant professor of  
ophthalmology, Guntur  
medical College, Guntur, India.

**Dr. Bellamkonda silpa**  
Senior resident  
Ophthalmology, Guntur  
medical College, Guntur, India.

**Dr. Rajeshbabu konakanchi**  
Post graduate ophthalmology,  
Guntur medical College,  
Guntur, India.

**Dr. A. Hemalatha**  
Post graduate ophthalmology,  
Guntur medical College,  
Guntur, India.

## A case of Best's vitelliform macular dystrophy in an 11 year old male patient – A case report and study of literature

**Dr. D. Udayakumar M.S, Dr. M. Nirmala M.S, Dr. Bellamkonda silpa, Dr. Rajeshbabu konakanchi, Dr. A. Hemalatha**

### Abstract

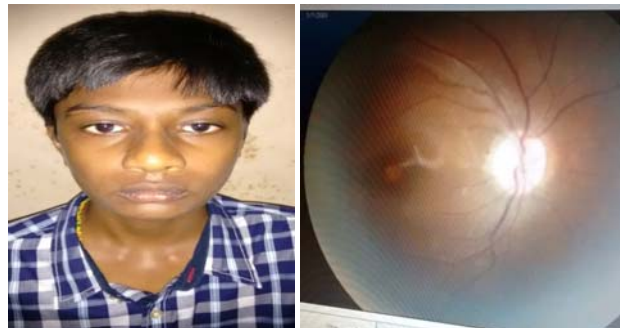A 11 yr old male, presented with defective vision in right eye from childhood and left eye from 3 years, which is non-progressive, not associated with any other symptoms. He had history of trauma to the left eye 3 years back. No similar complaints in the past. There is History of consanguineous marriage. No history of any surgeries. On examination visual acuity right eye – counting fingers 3 meters with pinhole 6/12, left eye 6/60 with pinhole 6/9. Extraocular movements normal in all directions. Pupils – normal size reacting to light. Fundus: Both eyes – media clear, optic disc oval, temporal pallor present, vessels normal, foveal reflex dull. OCT and EOG are done.

**Case report:** A 11 year male patient presenting with blurring of vision in right eye from childhood, left eye from 3 years.

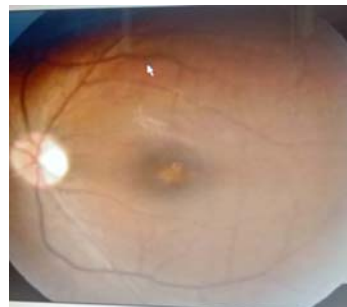**Keywords:** Defective vision, macular dystrophy, consanguineous marriage

### 1. Introduction

Here we are presenting a case of Best's vitelliform macular dystrophy in a 11 year old male.

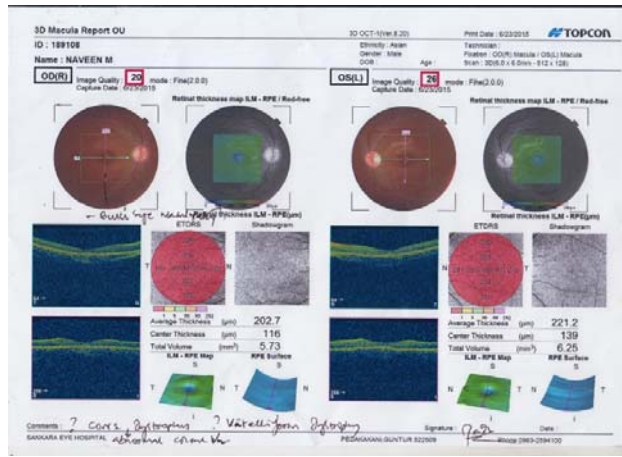


Right eye



Left eye

**Correspondence:**  
**Dr. D. Udayakumar M.S**  
Professor of ophthalmology,  
Guntur medical College,  
Guntur, India.



## 2. Discussion

- 1) Best (vitelliform) macular dystrophy is the second most common macular dystrophy. Inheritance is AD with variable penetrance and expressivity with the gene locus on 11q13. signs evolve gradually through the following stages *Pre-vitelliform* is characterized by a subnormal EOG in an asymptomatic child with a normal fundus. *Vitelliform* develops in infancy or early childhood and does not usually impair vision. A round, sharply-delineated ('sunny side up egg yolk') macular lesion within the RPE that varies in size between half a disc and two disc diameters. FA shows corresponding hypofluorescence due to blockage. OCT shows material within the RPE. The size of the lesions and stage of development in the two eyes may be asymmetrical and occasionally only one eye is initially involved. Occasionally the condition may be extramacular and multiple. *Pseudohypopyon* may occur at puberty when part of the lesion becomes resorbed. *Vitelliruptive* in which the egg yolk begins to break up ('scramble') and visual acuity drops. *Atrophic* in which all pigment has disappeared leaving an atrophic area of RPE. EOG is severely subnormal during all stages and also abnormal in carriers with normal fundi. Prognosis is reasonably good until the 5th decade after which visual acuity declines in one or both eyes due to CNV, scarring or geographic atrophy.
- 2) It is characterized by sharply delimited, usually bilateral orange yellow disc in foveal region resembling yolk of a fried egg. Visual acuity remains good and neuro epithelium is unaffected. Serious loss of vision occurs only after transition to an irregular pigmented lesion, after egg has become scrambled or after hemorrhages. This leads to a polymorphous foveal dystrophy. Visual fields are normal with exception of central scotoma. Dark adaptation ERG are normal but EOG is definitely pathological.
- 3) It presents a pleomorphic ophthalmoscopic picture. The central retinal lesion is often ophthalmoscopically evident several years before symptoms of visual loss are manifest. ruptured vitelliform lesion appears to simulate both glial and retinal pigment epithelial hyperplasia with scar formation and usually results in a more significant visual loss. fundus angiography of the egg yolk like macular lesion may show a minimal hyper fluorescence "window" defect from disruption of retinal pigment epithelium. Advanced scrambled lesions show more definite hyper fluorescent areas corresponding to the

retinal pigment epithelial defects.

- 4) Best's disease refers to a vitelliform dystrophy of the central retina with autosomal dominant inheritance but with variable penetrance and expressivity. The disease is characterized by large, yellow, yolk-like lesions of the central posterior pole, which usually appear during childhood. Later, the vitelliform cyst may disrupt and RPE atrophy causes central vision loss.

The lack of correspondence of NIR-AF and SW-AF distributions is particularly evident for the vitelliform lesion. NIR-AF is low at the site of high SW-AF accumulations of yellow lipofuscin like material. At the edge of the lesion, a rim of high NIR-AF is often observed.

Histologic examinations have shown that the vitelliform materials consisting of outer segment debris and debris from RPE cell disruption were lying anterior to the RPE. The material in the subretinal space had the cytochemical properties of lipofuscin. The RPE beneath the vitelliform material was flattened and revealed signs of atrophy.

## 3. References

1. Kanski clinical ophthalmology 7<sup>th</sup> edition page no:
2. Parsons eye disease 21<sup>st</sup> edition, 330.
3. Peyman principles and practice of ophthalmology, 2, 887.
4. Medical retina spaide, 73.