



ISSN Print: 2394-7500  
ISSN Online: 2394-5869  
Impact Factor: 5.2  
IJAR 2016; 2(1): 282-283  
www.allresearchjournal.com  
Received: 05-11-2015  
Accepted: 07-12-2015

**Patra S**  
Senior Resident, Dept of  
Anatomy, SCB MCH Cuttack.

**Nayak S**  
Senior Resident, Dept of  
Anatomy, SCB MCH Cuttack.

**Mohapatra C**  
Prof. & HOD Dept. of  
Anatomy SCB MCH Cuttack

## A case report on the coalition of cuneiforms with Navicula and second metatarsal

**Patra S, Nayak S, Mohapatra C**

### Abstract

**Introduction:** Tarsal coalition is a well-defined entity in paediatric as well as adult population. Tarsal coalition is an abnormal union between two or more bones which leads to restriction or limitation of the subtalar joint. The incidence of tarsal coalition is only 1-2%, out of which 90% affect the talocalcaneal or the calcaneonavicular bones.

**Aim:** This case report will be beneficial for anatomists, surgeons, orthopedicians, radiologists and podiatrists as it is the rarest of the rare case ever found in the literature.

**Observations:** In this case the lateral cuneiform is fused with the second metatarsal anteriorly and navicular posteriorly. We also found that the three cuneiforms are fused to the navicular bone. All the above coalitions are osseous and complete.

**Conclusion:** This case report will throw light on the possibility of occurrence of such rare cases which may be beneficial to the Surgeons, Anatomists, Radiologists, Podiatrists and Orthopedicians. Also this case might be a differential diagnosis for the orthopedicians while treating a case of flat foot.

**Keywords:** coalition, cuneiforms, navicular, second metatarsal

### 1. Introduction

Tarsal coalition also known as Tarsal synostosis/Peroneal spastic flatfoot is an abnormal bridge of tissue that connects two normally separate tarsal bones <sup>[1]</sup>. Cowell and Elener in 1983, defined tarsal coalition as an abnormal union between two or more bones which leads to restriction or limitation of the subtalar joint. The most reliable sign of coalition is the C-sign which is referred to as "Halo effect". The Halo effect is increased bone density or overlap secondary to stress along the talar dome, posterior facet and sustentaculum tali. Buchholz described a bar as a union between extra-articular bones and bridge as a union between intra-articular bones.

The frequency of tarsal coalitions is unknown, but the literature reports a range of 1% to 2%. Tarsal coalitions are rare, and 90% affect the talocalcaneal or the calcaneonavicular bones. The Talonavicular coalition being the third most commonly affected and is often bilateral. It is very rare for the calcaneocuboid and the naviculocuneiform coalitions to be affected. Normally, the first three metatarsals articulate with the three cuneiforms, the fourth and fifth with the cuboid <sup>[2]</sup>.

Tarsal coalitions have been associated with symphalangism, metatarsal anomalies and cuneiform colitions, Apert syndrome, small patella syndrome, congenital vertical talus etc. About 25% of children with tarsal coalition have a rigid flat foot <sup>[3]</sup>. A tarsal coalition may restrict or limit the movements of the foot and cause an abnormal gait pattern. Fibrous and cartilaginous coalitions may be asymptomatic with normal gait and athletics but ossification of these lesions may decrease available joint motion to the point that the onset of pain is accelerated. In the very young, this restricted motion can lead to accommodative supination and pronation of the ankle joint. In more mature bones, this may lead to bone spurring. Thus a sound knowledge of tarsal coalition is clinically important for Orthopedicians and Podiatrists.

**Observation:** This bone was procured from the department of Anatomy SCB MCH Cuttack which showed coalition of tarsals with the metatarsals. Normally, the first three metatarsals articulate with the three cuneiforms, the fourth and fifth with the cuboid. But here in this case

**Correspondence**  
**Patra S**  
Senior Resident, Dept of  
Anatomy, SCB MCH Cuttack.

the lateral cuneiform is fused with the second metatarsal anteriorly and navicular posteriorly. All the above coalitions are osseous and complete.

## 2. Discussion

There are several classifications of tarsal based on tissue type, etiology, anatomy, completeness of the coalition, surgical type and location. Buchholz describes the coalitions as fibrous (syndesmosis), cartilaginous (synchondrosis). Permanent classifies the coalition as congenital or acquired. Pfitzner in 1896 described the congenital type as an extension of an accessory ossicle into adjacent tarsal bone. Le Boucq in the same year proposed the theory of impaired segmentation and undifferentiation of primordial mesenchymal tissue which resulted in coalition. [3, 4, 5] Many studies have been conducted to investigate the genetic inheritance of coalitions. Leonard in 1974 concluded that hereditary transmission of tarsal coalitions is an autosomal dominant inheritance of varied penetrance. [6]

The onset of symptoms related to a tarsal coalition usually occurs at about nine to seventeen years of age, with a peak incidence occurring at ten to fourteen years of age. [3, 4] Symptoms do not occur until the bone has ossified to a degree. As far as the treatment is concerned, there are two types of treatment – conservative and surgery. The goal of non-surgical treatment of tarsal coalition is to relieve the symptoms by reducing the movement of the affected joint. This might include non-steroidal anti-inflammatory drugs (NSAIDs), steroidal anti-inflammatory injection, stabilizing orthotics or immobilization via a leg cast. At times, short term immobilization followed by long term orthotic use may be sufficient to keep the area free of pain.

Surgery is very commonly required. The type and complexity of the surgery will depend on the location of the coalition. Wherever possible the bone will be removed to restore normal motion between the two bones. If this is not possible, it may be necessary to fuse the affected joints together by using screws to connect them solidly at the cost of mobility. Cutting away the coalition is more likely to succeed in the younger patients.

## 3. Conclusion

Although coalition of metatarsal bones are uncommon relative to tarsal coalitions, this case report will throw light on the possibility of occurrence of such rare cases which may be beneficial to the Surgeons, Anatomists, Radiologists and Podiatrists. Also this case might be a differential diagnosis for the orthopedicians while treating a case of flat foot.

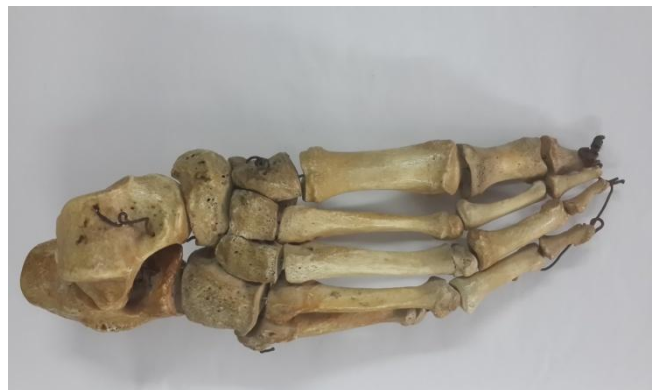

Fig 1: Showing a normal articulated Right foot.


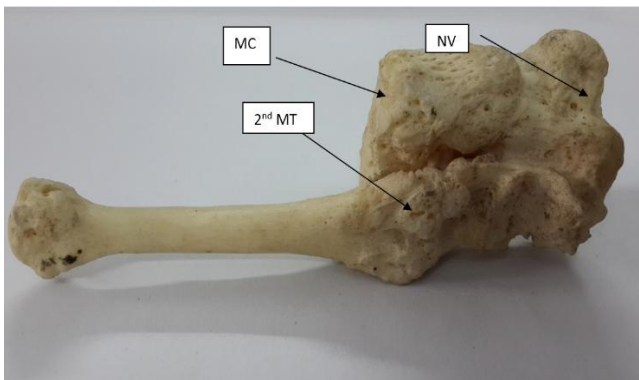


Fig 2 & Fig 3: showing the coalition of cuneiforms with navicular behind and 2<sup>nd</sup> metatarsal in front of a single specimen.

## 4. References

1. Debra Draves. Anatomy of the Lower Extremity, 1986, 101.
2. Anatomy for Surgeons: 832 W. Henry Hollinshead, Ph.D, 1958; 3:855.
3. Jack EA. Bone anomalies of the tarsus in relation to peroneal spastic flat foot. J. Bone Joint Surg. 36:3530-542, 1954.
4. Jayakumar S, Cowell HR. Rigid Flatfoot. Clin. Orthop., 22:77-84, \$977
5. Harris BJ. Anomalous structure in the developing human foot [Abstract]. Anat. Rec. 1955; 121:399.
6. Leonard MA. The inheritance of tarsal coalition and its relationship to spastic flat foot. J Bone Joint Surg. 56:520-526, 1974.