



ISSN Print: 2394-7500
ISSN Online: 2394-5869
Impact Factor: 5.2
IJAR 2016; 2(10): 160-162
www.allresearchjournal.com
Received: 27-08-2016
Accepted: 28-09-2016

Govindarajalu Ganesan
Associate Professor,
Dept. of General Surgery
Indira Gandhi Medical College
and Research Institute
Puducherry- 605009,
Tamil Nadu, India

A detailed study of the role of stool examination for whipworm ova in the diagnosis of whipworm infection

Govindarajalu Ganesan

Abstract

Objective: To study the role of stool examination for whipworm ova or eggs in the diagnosis of whipworm infection.

Methods: A study of 72 patients who had undergone colonoscopy for a period of 5 years from November 2009 to October 2014 was carried out in order to find out the presence of parasitic worms during colonoscopy in these patients.

Results: Out of these 72 patients, parasitic worm was found in the colon in only one patient. The parasitic worm found in this patient was identified as whipworm or trichuris trichiura by its characteristic whip like shape. It has a short posterior thick part resembling the short handle of the whip and a long, thin anterior part resembling the distal long, thin part of the whip. But the stool examination of the patient was negative for ova or cyst.

Conclusion: Usually whipworm infection is diagnosed by finding its ova or eggs in stool examination. But sometimes adult whipworms are found while doing colonoscopy even when the stool examination is negative for its eggs. Hence colonoscopy is a very useful investigation to diagnose whipworm infection especially when the stool examination is negative for its eggs.

Keywords: Adult whipworm, trichuris trichiura, stool examination, colonoscopy

1. Introduction

Whipworms are the most common nematodes or roundworms found in the large intestine of human beings while doing colonoscopy (2). Our patient was also found to have whipworm in the colon while doing colonoscopy. There has been also reports of finding whipworm in the large intestine of human beings while doing colonoscopy in many parts of the world. (1 to 14). Usually whipworm (trichuris trichiura) infection is diagnosed by finding its ova or eggs in stool examination [1, 8, 10, 11, 13]. But the patient who had whipworm in our study had negative stool examination for ova or cyst. Hence colonoscopy is a very useful investigation to diagnose whipworm infection especially when the stool examination is negative for its eggs.

2. Materials and Methods

This study was conducted in the department of general surgery, Aarupadai Veedu Medical College and Hospital, Puducherry. A study of 72 patients who had undergone colonoscopy for a period of 5 years from November 2009 to October 2014 was carried out in order to find out the presence of parasitic worms during colonoscopy in these patients. In each of these patients, presence of any parasitic worm was carefully looked for during the procedure of colonoscopy and the colonoscopic pictures of each patient were carefully studied and analysed. In patients found to have parasitic worms during colonoscopy, stool examination was done for ova or cyst.

3. Results

Out of these 72 patients, parasitic worm was found in only one patient. The parasitic worm found in this patient was identified as whipworm or trichuris trichiura by its characteristic whip like shape. This patient was an eighty year old male patient and one adult whipworm was found in the sigmoid colon of this patient while doing colonoscopy. His stool examination was negative for ova or cyst. The patient was treated with a single dose of 400mg of albendazole.

Correspondence
Govindarajalu Ganesan
Associate Professor,
Dept. of General Surgery
Indira Gandhi Medical College
and Research Institute
Puducherry- 605009,
Tamil Nadu, India

4. Discussion

4.1 Size of whipworm and its life cycle

The male whipworm is 3 to 4.5 cm and the female whipworm is 3.5 to 5 cm in length [11]. Adults can live for years and deposit thousands of eggs per day [8]. Infective eggs are ingested from eating contaminated soil [8, 13]. Upon ingestion the eggs hatch into larvae in the small intestine [8, 11, 13, 14]. The larvae eventually migrate to the large intestine and complete maturation to adult worms in 1 to 3 months [8, 11, 13, 14].

4.2 Negative stool examination in whipworm infection

In our patient, stool examination is negative for ova or cyst. In various other studies also, adult whipworms were found while doing colonoscopy even when the stool examination is negative for its eggs [2, 3, 5, 6, 7, 13].

4.3 Whitish colour of whipworm

Whipworms do not feed on blood and feed only on the tissue secretions of the large intestinal wall. Whipworm is

always whitish in colour [5] as it does not feed on blood (fig 1, 2).

4.4 Only a very small portion of the long anterior part of whipworm seen during colonoscopy

We can see only the short posterior thick part entirely in the lumen of the large intestine [13, 14] but only a very small portion of the long, thin anterior part while doing colonoscopy since most of the anterior part penetrates into the large intestinal wall in order to feed on the tissue secretions of the large intestinal wall [13, 14]. Hence in fig 1, we can see only the short posterior thick part of the whitish coloured whipworm entirely in the lumen of the sigmoid colon but only a very small portion of the long, thin anterior part since most of the anterior part penetrates into the large intestinal wall for feeding purpose. But in the highly magnified view in fig 2, we can see clearly both the short posterior thick part and also the anterior thin part clearly due to the higher magnification.

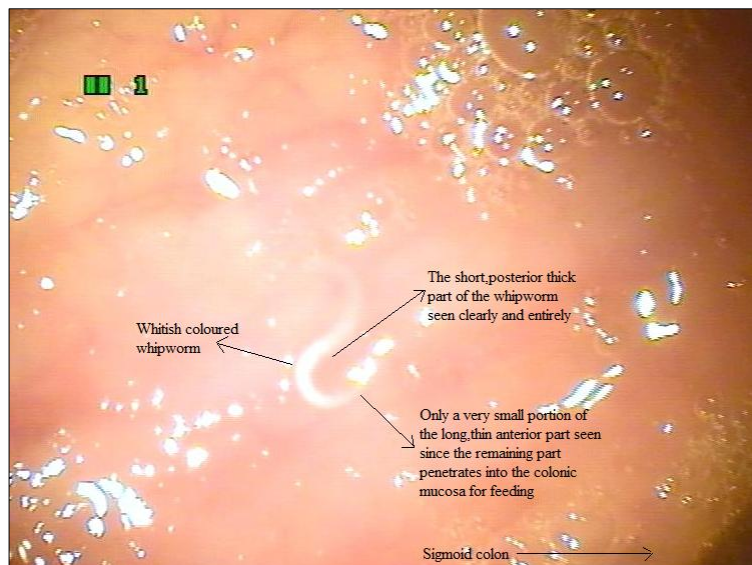


Fig 1: showing clearly and entirely only the short, posterior thick part of the whitish coloured whipworm and only a very small portion of the long, thin anterior part since the anterior part penetrates into the large intestinal wall for feeding purpose.

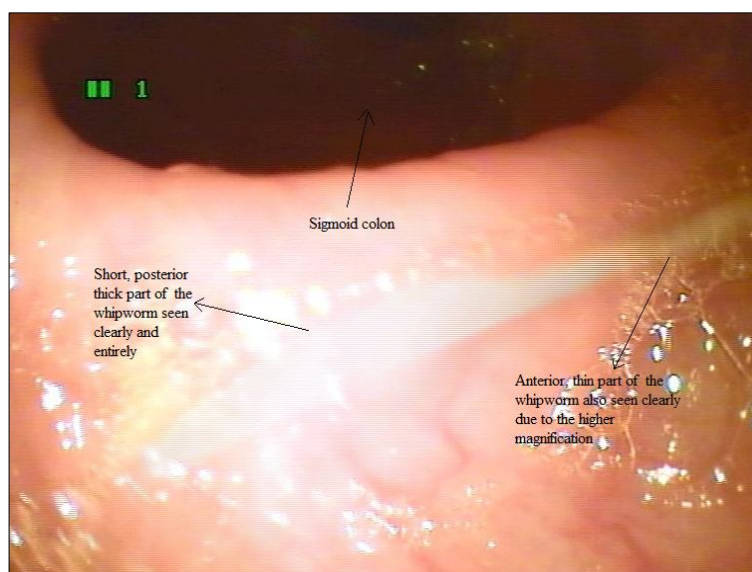


Fig 2: Magnified view showing clearly both the short, posterior thick part and also the anterior, thin part of the whipworm due to the higher magnification.

5. Conclusion

1. Usually whipworm (*trichuris trichiura*) infection is diagnosed by finding its ova or eggs in stool examination.
2. But adult whipworms are sometimes found while doing colonoscopy even when the stool examination is negative for its ova or eggs.
3. The patient who had whipworm in our study also had negative stool examination for ova or cyst.
4. Hence colonoscopy is a very useful investigation to diagnose whipworm infection especially when the stool examination is negative for its ova or eggs.

6. Acknowledgement

The author sincerely thanks the staff nurse Nithya who was assisting while doing colonoscopy and the staff nurses A.K. Selvi and Nithya for their immense help rendered to the author while conducting this work. The author acknowledges the immense help received from the scholars whose articles are cited and included in references of this manuscript. The author is also grateful to authors / editors / publishers of all those articles, journals and books from where the literature for this article has been reviewed and discussed.

7. References

1. Joo JH, Ryu KH, Lee YH, Park CW, Cho JY, Kim YS *et al.* Colonoscopic diagnosis of whipworm infection. *Hepatogastroenterology*. 1998; 45(24):2105-9.
2. Do KR1, Cho YS, Kim HK, Hwang BH, Shin EJ, Jeong HB. *et al.* Intestinal helminthic infections diagnosed by colonoscopy in a regional hospital during 2001-2008. *Korean J Parasitol*. 2010; 48(1):75-8.
3. Yoshida M, Kutsumi H, Ogawa M, Soga T, Nishimura K, Tomita S. *et al.* A case of *Trichuris trichiura* infection diagnosed by colonoscopy. *Am J Gastroenterol*. 1996; 91(1):161-2.
4. Khuroo MS, Khuroo MS, Khuroo NS. *Trichuris dysentery syndrome: a common cause of chronic iron deficiency anemia in adults in an endemic area (with videos)*. *Gastrointest Endosc*. 2010; 71(1):200-4.
5. Ok KS1, Kim YS, Song JH, Lee JH, Ryu SH, Lee JH. *et al.* *Trichuris trichiura* infection diagnosed by colonoscopy: case reports and review of literature. *Korean J Parasitol*. 2009; 47(3):275-80.
6. Wang DD, Wang XL, Wang XL, Wang S, An CL. *Trichuriasis diagnosed by colonoscopy: case report and review of the literature spanning 22 years in mainland China*. *Int J Infect Dis*. 2013; 17(11):1073-5.
7. Tuan Sharif SE, Ewe Seng C, Mustaffa N, Mohd Shah NA, Mohamed Z. *Chronic Trichuris trichiura Infection Presenting as Ileocecal Valve Swelling Mimicking Malignancy*. *ISRN Gastroenterol*, 2011. 105178. doi: 10.5402/2011/105178. Epub 2010 Oct 31.
8. Chang CW, Chang WH, Shih SC, Wang TE, Lin SC, Bair MJ. *Accidental diagnosis of Trichuris trichiura by colonoscopy*. *Gastrointest Endosc*. 2008; 68(1):154.
9. Diniz-Santos DR, Jambeiro J, Mascarenhas RR, Silva LR. *Massive Trichuris trichiura infection as a cause of chronic bloody diarrhea in a child*. *J Trop Pediatr*. 2006; 52(1):66-8.
10. Lorenzetti R1, Campo SM, Stella F, Hassan C, Zullo A, Morini S. *An unusual endoscopic finding: Trichuris*

- trichiura*. Case report and review of the literature. *Dig Liver Dis*. 2003; 35(11):811-3.
11. Tokmak N, Koc Z, Ulasan S, Koltas IS, Bal N. *Computed tomographic findings of trichuriasis* *World Journal of Gastroenterology*. 2006; 12(26):4270
12. Lee SH, Kwon JE, Cheong YS. *Two cases of Trichuris trichiura infection diagnosed by colonoscopy*. *Korean Journal of Family Medicine*, 2010; 31(8):622-629.
13. Herman MA, Ukawa K, Sugawa C. *CASE REPORT: Diagnosis and Removal of Cecal Whipworm Infection*. *Digestive diseases and sciences*, 2000; 45(8):1639-1643
14. Azira MS, Zeehaida M. *Severe chronic iron deficiency anaemia secondary to Trichuris dysentery syndrome-a case report*. *Trop Biomed*. 2012; 29(4):626-631.