



ISSN Print: 2394-7500
ISSN Online: 2394-5869
Impact Factor: 5.2
IJAR 2016; 2(3): 75-77
www.allresearchjournal.com
Received: 12-01-2016
Accepted: 14-02-2016

Dr. Anshuman Singh
Dr. D.Y. Patil Medical College
and Research Centre, Pimpri,
Pune 411018

Dr. Sharad Agarkhedkar
Dr. D.Y. Patil Medical College
and Research Centre, Pimpri,
Pune 411018

Dr. Kumar Gaurav
Dr. D.Y. Patil Medical College
and Research Centre, Pimpri,
Pune 411018

Correspondence
Dr. Anshuman Singh
Dr. D.Y. Patil Medical College
and Research Centre, Pimpri,
Pune 411018

Edward syndrome with hepatoblastoma: A case report

Dr. Anshuman Singh, Dr. Sharad Agarkhedkar, Dr. Kumar Gaurav

Abstract

Edward syndrome is a condition of developmental delay and dysmorphism caused due to trisomy 18 disrupting the normal course development, causing the characteristic features of Edward syndrome. The main characteristics of Edward syndrome are: intra- extra uterine growth retardation, mental retardation with typical facial dysmorphism, microcephaly and mid line defects.

When only some of the body's cells have an extra copy of chromosome 18, is called mosaic Edward syndrome and is a very rare form. Here we describe a female baby with mosaic trisomy 18, who had a majority of the main phenotypic feature.

Keywords: Edward syndrome, trisomy 18, dysmorphism

1. Introduction

Edward syndrome is the chromosomal disorder due to non disjunction of chromosome number 18 at the time of meiotic cell division.

Its Incidence is approximately 1 per 6500 live births [1]. Among live births, trisomy 18 is the second most common autosomal trisomy after trisomy 21 [2]. Approximately 5 percent of people with trisomy 18 have an extra copy of chromosome 18 in only some of the body's cells. In these people, the condition is called mosaic trisomy 18. Like full trisomy 18, mosaic trisomy is not inherited and is a random occurrence that takes place during cell division [2]. It is contagious gene syndrome with complex and variable variety of clinical features ranging from pre and postnatal growth retardation, microcephaly, low-set malformed ears, micrognathia, upturned nose, palpebral fissures, hypertelorism, ptosis, a short breast bone, clenched hands, choroid plexus cysts, underdeveloped thumbs and/or nails, absent radius, webbing of the second and third toes, clubfoot or rocker bottom feet, and in males undescended testicles. Associated congenital anomalies include midline defect (cleft lip/palate), renal anomalies, congenital heart disease, inguinal and umbilical hernia.

The Edward's phenotype is characterized by a severe malformation syndrome, almost always leading to intrauterine death and death in the early weeks of life [3]. The mean survival is two to three months for males and 10 months for females [4]. Few patients have survived to the age of 15 to 19 years [5]. Patients with mosaicism have prolonged survival rate.

2. Case Report: A term female baby born of 2nd degree consanguineous marriage to a primigravida mother to an uneventful pregnancy and vaginal delivery in a primary health centre. Baby was apparently asymptomatic for first 48 hours of life but then developed respiratory distress and was admitted in a neonatal intensive care unit and was given supportive care. The investigations revealed positive TORCH titres and was started on antibiotics. She was hypertensive and 2 D echo revealed acyanotic congenital heart disease with VSD (left to right shunt) with large PDA, was started on antifailure drugs and was weaned off. As the child had not passed urine since 36 hours renal function test were done and was found that child had acute kidney failure. For further management child was referred to our NICU.

The examination revealed dysmorphic features such as microcephaly, hypertelorism, micrognathia, clenched hands with overlapping fingers, "rocker bottom foot: convex rounded bottom to the foot" and pansystolic murmur with normal for age BP in right upper and lower limbs.

Initial management in NICU included oxygen therapy, stabilisation of temperature and maintenance of optimal blood glucose with inotropic support.

Front line investigations were suggestive of anemia (Hb 9.6 gm%), acute kidney failure with blood urea of 151mg% and serum creatinine of 4.18mg%, as per pediatric nephrologist advice peritoneal dialysis was started. A positive urine culture for enterococcus spp. was isolated and antibiotics were started as per sensitivity. During course of treatment she had electrolyte disturbances which were managed accordingly. Patient responded well to treatment and was discharged on day 32 of life with supportive therapy, was advised cardiac operation but due to unaffordability they took the child home and asked to follow up in high risk OPD. Based on clinical suspicion a Chromosomal study was advised. Chromosome analysis showed female karyotype with Mosaic Edward Syndrome.

She was being regularly followed up in high risk clinic. The child had having poor weight gain and repeated respiratory tract infection. At 5 months of age she was diagnosed to have hepatoblastoma and advised chemotherapy. Unfortunately the child died within one month.

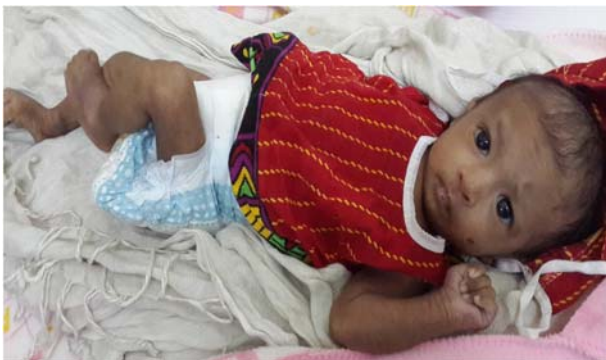

Fig 1: Features like microcephaly, hypertelorism, micrognathia, clenched hands with overlapping fingers and rocker bottom foot can be seen.

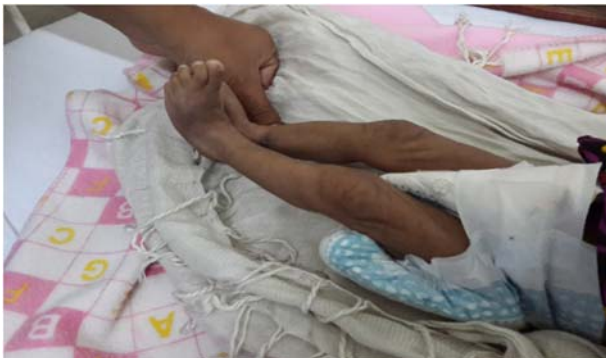

Fig 2: rocker bottom foot can be seen

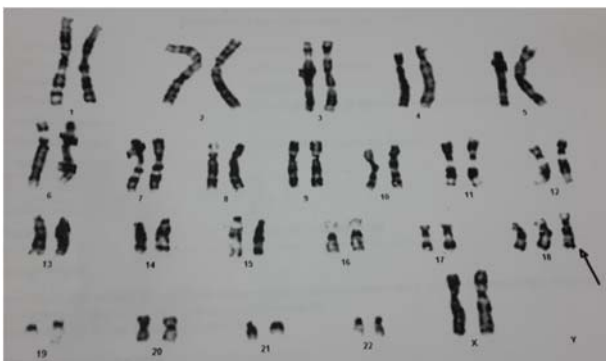


Fig 3: 25 metaphases show female karyotype with trisomy of chromosome no. 18 and another 5 metaphases show 46, XX.

3. Discussion

Edward syndrome is considered to be a fatal congenital disorder with mean survival of 1-3 months [6]. About 95% die in utero, among live born infants, only 50% live up to 2 months and only 5-10% would be able to complete their first birthday [7, 8]. The longest survival time reported till date is 50 years [9]. 80% of the cases were reported to be female.

Its incidence is approximately 1 per 6500 live births [1]. Among live born children, trisomy 18 is the second most common autosomal trisomy after trisomy 21 [10].

Edward syndrome occurs because of non-disjunction of the 18th chromosome during meiosis of the reproductive cells of the mother and the father.

Advanced maternal age, environmental factors and low socioeconomic level play a role in the incidence of Edward Syndrome [11]. Advanced maternal age was not present in this case but socio economic status was falling under lower class of modified Kuppaswamy scale.

There are hallmark features present in a majority of trisomy 18 patients. These features include mental and developmental delay, growth deficiency, abnormal craniofacial profile, clenched hands with overlapping digits, internal organ malformations including inguinal or umbilical hernias, and multiple congenital heart defects [6, 12].

Many structural defects associated with Trisomy 18 have been reported. In 97% of cases with trisomy 18, structural disorders are found in at least three organs.

In Edward's syndrome [13] VSD - 67%, underdevelopment of reproductive organs - 50%, horseshoe kidney -32%, omphalocele - 14%, diaphragm hernia - 11%, oesophageal atresia in 11% and only two cases accompanied by meningocele and 1 case of Mesocardia with ASD have been reported [13, 14].

The major causes of death in Edward syndrome are sudden death due to central apnea, cardiac failure due to cardiac malformations and respiratory infections due to hypoventilation, aspiration, upper airway obstruction or combination of these factors.

4. Conclusion

Edward syndrome presents with a constellation of signs and symptoms which include mental retardation, feeding difficulties and a range of midline fusion defects. A high index of suspicion should be present in babies with congenital anomalies, phenotypic dysmorphism, mid line defects with multi system involvement. Genetic testing is available for diagnosis and antenatally can be diagnosed by FISH.

Its association with profound mental retardation and severe morbidity underscores the importance of prenatal diagnosis. Prognosis is poor, with no definitive treatment; patients can be managed with multidisciplinary support.

5. References

1. Crider KS, Olney RS, Cragan JD. Trisomies 13 and 18: population prevalences, characteristics, and prenatal diagnosis, metropolitan Atlanta, 1994-2003. *Am J Med Genet A*. Apr 1 2008; 146(7):820-6.
2. Smith DM, Jones KL. In: Recognizable patterns of human malformations. Genetic, Embryologic and Clinical aspects. 4th ed. W.B. Saunders Company: Philadelphia; 1988, 16-9.
3. Weber WW. Survival and sex ratio in trisomy 17-18. *Am J Hum Genet*. 1967; 19:369-77.

4. De Grouchy J, Turleau C. 18 trisomy In: Clinical Atlas of Human Chromosomes. 2nd ed. A Wiley Medical Publication. New York, 1984, 292-7.
5. Young ID, Cook JP, Mehta L. Changing demography of trisomy 18. Arch Dis Childhood 1986; 61:1035-6.
6. Kenneth Lyons Jones, Smiths recognizable Patterns of human malformation, Elsevier Saunders 6th edition, 2009, 13.
7. Morallo LM, Rosenblum H, Esterly KL, Johnson WD, Storlazzi JJ, Narvaez AC *et al.* Trisomy 18(Edward Syndrome) in Delaware. Del Med J. 1983; 55:27.
8. Bundy AL, Saltzman DH, Pober B, Fine C, Emerson D, Doubilet PM. Antenatal sonographic findings in trisomy 18. J ultrasound Med. 1986; 55:27.
9. Bhanumathi B, Neelam AG, Mishro ZA. Trisomy 18 in a 50 year old female. Indian J Hum Genet. 2006; 12:146-7.
10. Crider KS, Olney RS, Cragan JD. Trisomies 13 and 18: population prevalences, characteristics, and prenatal diagnosis, metropolitan Atlanta, 1994-2003. Am J Med Genet A. Apr 1 2008; 146(7):820-6.
11. Naguib KK, Al-Awadi SA, Bastaki L. Clustering of trisomy 18 in Kuwait: genetic predisposition or environmental. Ann Saudi Med 1999; 19:197-200.
12. Van Dyke DC, Allen M. Clinical management considerations in long term survivors with trisomy 18. Pediatrics 1990; 85:753-9.
13. Steffensen TS, Opitz JM, Gilbert-Barness. Congenital perineal hernia in a fetus with trisomy 18. Fetal Pediatric Pathol 2009; 28:95-9.
14. Bick D, Markowitz RI, Horwich A. Trisomy 18 associated with ectopia cordis and occipital meningocele. Am J Med Genet. 1988; 30:5-10.