



ISSN Print: 2394-7500
ISSN Online: 2394-5869
Impact Factor: 5.2
IJAR 2016; 2(3): 257-259
www.allresearchjournal.com
Received: 02-01-2016
Accepted: 05-02-2016

Dr. SR Agarkhedkar
Head of the Department and
Professor, Department of
Pediatrics, Dr. DY Patil
Medical College, Pimpri, Pune,
India.

Dr. Sudhir Malwade
Associate Professor,
Department Of Pediatrics, Dr.
DY Patil Medical College,
Pimpri, Pune, India.

Dr. Ruchi Chiripal
Resident, Department Of
Pediatrics, Dr. DY Patil
Medical College, Pimpri, Pune,
India.

Dr. Katyayni Singh
Resident, Department Of
Pediatrics, Dr. DY Patil
Medical College, Pimpri, Pune,
India.

Correspondence
Dr. SR Agarkhedkar
Head of the Department and
Professor, Department of
Pediatrics, Dr. DY Patil
Medical College, Pimpri, Pune,
India.

Subgaleal hematoma as a presentation of hemophilia a

Dr. SR Agarkhedkar, Dr. Sudhir Malwade, Dr. Ruchi Chiripal, Dr. Katyayni Singh

Abstract

Hemophilia as an underlying cause of ICH is still under recognized even in tertiary pediatric institutions and associated with diagnostic and management delays. Bleeding disorders may present during the neonatal period, however, absent patient history along with unique physical signs render any diagnosis difficult to establish. Haemophilia in the newborn period is challenging; it may present rarely as ICH with significant long term morbidity. Traumatic deliveries may lead to early presentation of haemophilia with specific types of extracranial and intracranial bleeds in newborn period. Therefore, an awareness of the natural history of neonatal haemophilia is crucial for early diagnosis and optimal management. We report a case of neonatal hemophilia a that presented with a rare presentation of subgaleal hematoma with uneventful vaginal delivery.

Keywords: hemophilia, ICH, icterus, anemia, subgaleal hematoma, factor VIII.

Introduction

Hemophilia occurs in approximately 1: 5,000 males. Out of these, 85% have factor VIII deficiency. Factor IX deficiency is seen in approximately 10-15% of the hemophiliacs. Obvious symptoms such as easy bruising, intramuscular hematomas, and hemarthrosis begin when the child begins to cruise. Even in patients with severe hemophilia, only 90% have evidence of increased bleeding by 1 yr of age. Intracranial hemorrhages which is a devastating complication of hemophilia presents only in 2% of neonates, whereas 30% of male infants with hemophilia bleed with circumcision. ICH in newborns is often associated with an extracranial haemorrhage after trauma, such as prolonged and/or instrumental delivery. The clinical signs of ICH in hemophiliac newborn are sometimes vague, with anaemia and pallor as the most frequent symptoms followed by neurological symptoms such as seizures, apnea, lethargy and paresis. The severity of hemophilia is classified on the basis of the patient's baseline level of factor VIII or factor IX, because factor levels usually correlate with the severity of bleeding symptoms. Reduced clotting factor protein is seen in majority of patients with hemophilia. If a bleed is diagnosed in hemophilia it must be treated with FVIII or FIX as appropriate. In Hemophilia, a prophylactic FVIII or FIX could be administered to offset labour trauma and limit neurological damage in affected individuals. In patients with haemophilia without family history, high index of suspicion is required for diagnosis and in patient with family history, antenatal counseling with good perinatal care is needed. This approach can potentially change the course of disease by limiting the neurological damage in affected infants.

Case Report

A full-term male newborn was born to a 21 year old primigravida mother with nonconsanguineous marriage through vaginal route with uneventful postnatal event. APGAR score was 9 at 1 and 5 minutes of life. Patient had received prophylactic vitamin K at birth. After 72 hours of life the baby looked off colour and also had icterus. The child was brought to NICU for the same. The child was hemodynamically unstable and admitted in NICU. The child was kept NBM and started on oxygen, fluids and inotropes.

The investigations done were as follows

	Day 1 (asymptomatic)	Day 3 (symptomatic)	Day 4 (after PCV and before factor VIII)	After factor VIII transfusion
Hb	12.4	7.4	11.2	11.4
Platelet count	2.2 lac/cmm	2.0 lac/cmm	2.0 lac/cmm	
PCV	36%	20.8%	34.2%	34.3%
s. Bilirubin total	8.7 mg %	12.0mg%	17.5mg%	14mg%
aPTT			65 sec	34 sec
PT			14 sec	14 sec

The above table shows that when the neonate was brought to NICU on day 3, he had anemia with normal platelets. There was also hyperbilirubinemia at that time. On day 4 after giving PCV, Hemoglobin was 11.2mg/dl and bilirubin 12.0mg%. APTT was 65 seconds. After giving Factor VIII the APTT came to 34 seconds which is normal.

The child was resuscitated for acute blood loss by PCV transfusion and phototherapy for hyperbilirubinemia. We noticed a gradually increasing scalp swelling, pitting in nature extending up to nape of neck and behind the ears with bluish discoloration over it. Patient improved hemodynamically after transfusion and oxygen was weaned off slowly. But the swelling and bilirubin continued to increase, and the baby also developed swelling and bruising over eyelids and dorsum of left foot. Neuroimaging of swelling was done which was indicative of high parietal region swelling suggestive of subgaleal hematoma. The other parameters were as follows: Peripheral Blood Smear showed normocytic normochromic cells with anisocytosis and no membrane defects. APTT was 65 sec (control: 30-45 sec) with normal PT, LDH, G6PD, osmotic fragility and LFTs. With this deranged APTT and abnormal imaging, suspicion of hemophilia was done and detailed family enquiry was done when it was known that the baby’s maternal uncle was a known case of Hemophilia A which was unrevealed before due to some cultural beliefs. Thereafter the baby was prophylactically given factor VIII for total period of 11 days. After treatment, there was resolution of swelling and bruising and no new lesions appeared. The neurological condition was satisfactory. Patient was discharged and asked to come for follow-up after one and half months for further necessary investigations.

After one and half months the child’s factor VIII assay was done which was consistent with diagnosis of Hemophilia A. Since then the child regularly follows up with hematologist and in our high risk OPDs. At present the child is on regular treatment, thriving well, achieving all age appropriate milestones and neurologically normal and healthy at 6 months of life with no signs of focal neurological deficits No adverse report of factor VIII was reported.

Discussion: ICH occurs in 2-2.5/1000 babies which may be asymptomatic or symptomatic. Bleeding neonate may present with cord bleeding, cephalohematomas, injury related bleeding – following invasive procedures, facial purpura following birth –that is usually associated with severe platelet dysfunction or thrombocytopenia. Hemophilia in neonate presenting as a subgaleal hematoma is a rare phenomenon. The prolonged PT in neonates the interpretation of haemostatic investigations reflects decreased plasma concentrations of vitamin K dependant factors, whereas the prolonged PTT stems from decreased plasma levels of contact factors as well. The levels of FVIII, FV and FXIII correlate well with adult boundaries.

According to the case series published in 1990, there were 2 cases of hemophilia which presents as subgaleal hematoma. However they both had a family history known prior to birth. According to the European cohort study which encompassed 12centres, head bleeds occurred in 3.5% children within the first 28 d of life with one presenting as subdural hematoma. Assisted delivery (forceps/vacuum) was the only risk factor for neonatal head bleeding according to that study. Intraparenchymal ICH did not result in any fatalities, long term neurological sequelae occurred in 0.4%. In the Swedish series with 117 consecutive cases of severe and moderate haemophilia, of the 12 infants with sub-galeal/cephalic haematoma (ECH), 10 were delivered by vacuum extraction. As discussed, our case was Hemophilia A with subgaleal hematoma as a clinical presentation. It was a full term male child with features consistent with the description of neonatal Hemophilia in literature. The presentation was unusual however occurring after uneventful vaginal delivery emphasizing the importance of high index of suspicion needed in every case. Thus a bleeding neonate should be investigated on the following to ease the diagnosis

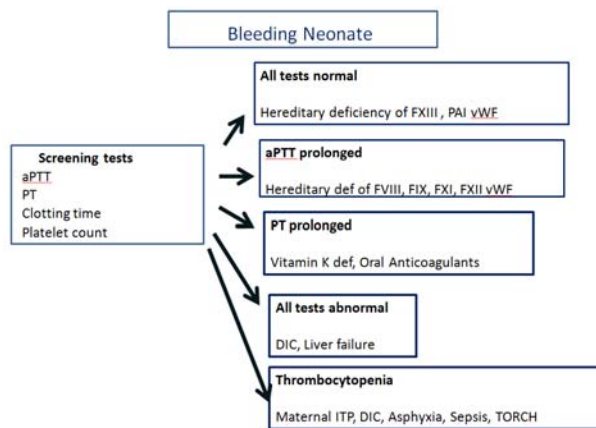


Fig 1: Approach to A Bleeding Neonate




Fig 2: Subgaleal Hematoma extending to nape of the neck

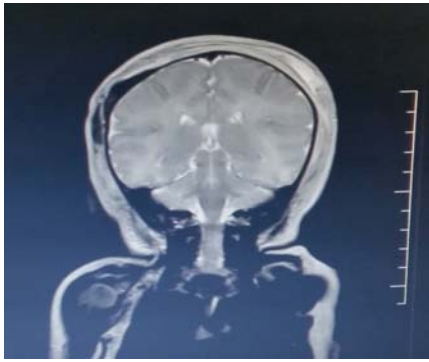


Fig 3: MRI showing subgaleal hematoma

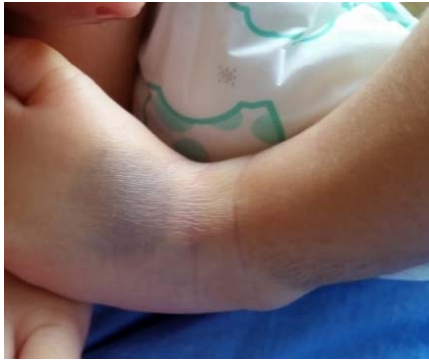

Fig 4: Bruising over the dorsum of foot

Conclusion: We thus confirm that patients with haemophilia are at a significant risk of severe bleeding, including ICH, in the neonatal period; ICH after the neonatal period is a significant problem that affects 3–10% of the haemophilia population mainly treated on demand. The death rate from ICH may be as high as 20% and the majority of patients will suffer future sequelae. The risk of ICH has to be considered when discussing choice of therapy in patients with haemophilia.

As a large proportion of mothers lack knowledge of the carrier status, efforts should be addressed at improving genetic counseling practices. This will not, however reduce the risk of ICH in those neonates with haemophilia consequent on a spontaneous mutation. Thus there is no definite consensus on management of neonatal hemophilia and high index of suspicion is required for its diagnosis and management. Hence, in a male child with jaundice and anemia, family history should be thoroughly investigated and a high index of suspicion is required.

References

1. Motta M, Tincani A, Lojaco A. Neonatal outcome in patients with rheumatic disease. *Lupus* 2004; 13:718-23.
2. Hancock JF, Wieland K, Pugh RE. A molecular genetic study of factor XI deficiency. *Blood* 1991; 77:1942-8.
3. Hall GW. Kasabach-Merritt syndrome: pathogenesis and management. *Br J Haematol.* 2001; 112:851-62.
4. Andrew M, Vegh P, Johnston M. Maturation of the hemostatic system during childhood. *Blood* 1992; 80:1998-2005.
5. Neonatal bleeding in haemophilia: a European cohort study; *British Journal of Haematology.* 2012; 156(3):374-382.

6. Ljung R. The optimal mode of delivery for the haemophilia carrier expecting an affected infant is vaginal delivery. *Haemophilia*, 2010; 16:415-419.
7. Kulkarni R, Lusher JM. Intracranial and extracranial hemorrhages in newborns with hemophilia: a review of the literature. *Journal of Pediatric Hematology and Oncology.* 1999; 21:289-295.
8. Bleeding disorders in neonates Kenet G, Chan AKC, Soucie JM, Kulkarni R. *Haemophilia. Special Issue: State of the Art XXIX International Congress of the World Federation of Hemophilia Buenos Aires, Argentina, 10-14 July, 2010 Issue Supplement s5, 2010; 16:168-175.*
9. MacLean PE, Fijnvandraat K, Beijleveldt M, Peters M. The impact of unaware carrier ship on the clinical presentation of haemophilia. *Haemophilia* 2004; 10:560-564.
10. Neonatal subgaleal hemorrhage: Clinical presentation, treatment, and predictors of poor prognosis, *Pediatrics International* 2007; 49(6):903-907.