



ISSN Print: 2394-7500  
ISSN Online: 2394-5869  
Impact Factor: 5.2  
IJAR 2016; 2(5): 322-326  
www.allresearchjournal.com  
Received: 27-03-2016  
Accepted: 28-04-2016

**Heba E Essa**  
Thoracic Medicine  
Department, Mansoura  
University, Egypt.

**Sayed A Abdelhafez**  
Thoracic Medicine  
Department, Mansoura  
University, Egypt.

**Mohammad E Abu Shehata**  
Thoracic Medicine  
Department, Mansoura  
University, Egypt.

**Fatma E Mostafa**  
Pathology Department,  
Mansoura University, Egypt.

**Amal Fathy**  
Thoracic Medicine  
Department, Mansoura  
University, Egypt.

**Bassma Hamed**  
Zoology Department, Medical  
Experimental Research Center,  
Mansoura University, Egypt.

**Mohamed A Sobh**  
Urology & Nephrology Center,  
Mansoura University, Egypt.

**Correspondence**  
**Amal Fathy**  
Thoracic Medicine  
Department, Mansoura  
University, Egypt.

## Evaluation of different time courses of bleomycin to induced interstitial pulmonary fibrosis in C57BL/6 mice

**Heba E Essa, Sayed A Abdelhafez, Mohammad E Abu Shehata, Fatma E Mostafa, Amal Fathy, Bassma Hamed, Mohamed A Sobh**

### Abstract

**Background and objectives:** Animal models for human pulmonary fibrosis ideally should reflect detailed characteristics of human disease including inflammation and abnormal epithelial repair with the induction of fibrotic foci. In addition, animal models should be highly reproducible, inexpensive to maintain, easy to perform and accessible. The aim of this study to evaluate the ability of bleomycin to induce pulmonary fibrosis in animal model by different time courses and the best time for its occurrence.

**Material and methods:** This study was conducted in Medical Experimental Research center (MERC) in Mansoura University on C57BL/6 mice. Group (A) C57BL/6 mice (n=6) received 0.25 ml normal saline intraperitoneal twice weekly for 8 weeks and sacrificed two days after last saline dose injection. Group (B) C57BL/6 (n=10) mice received intraperitoneal injection of 0.5mg bleomycin twice weekly for 6 weeks only 6 mice completed the study and sacrificed two days after last bleomycin dose similarly. Group (C) C57BL/6 (n=10) received intraperitoneal injection of 0.5mg bleomycin twice weekly but for only 8 weeks only 6 mice completed the study and sacrificed two days after last bleomycin dose. After scarification histopathological examination of prepared slides and computerized imaging analysis were done. Weight recorded once weekly.

**Results:** Bleomycin induced fibrosis in the C57BL/6 mice after six and eight weeks with no significance difference between groups.

**Conclusion:** Bleomycin in a dose of 0.5mg for six and eight weeks induces pulmonary fibrosis in C57BL/6 mice and the six weeks model could substitute the eight weeks one.

**Keywords:** Bleomycin intraperitoneal injection interstitial pulmonary fibrosis

### Introduction

Idiopathic pulmonary fibrosis (IPF) is a crippling disease for which no effective therapy exists. It includes groups of diseases characterized by decrease of lung compliance and impairment of gas exchange [1]. These include diversity in their etiology and pathogenesis, which is reflected in their lack of responses to existing therapies [2].

Animal models for human pulmonary fibrosis ideally should reflect detailed characteristics of human disease including inflammation and aberrant epithelial repair with the induction of fibrotic foci. It also should be accessible, highly reproducible, inexpensive to maintain, and easy to perform [3].

Rats and Mice are the most widely used experimental animals have been studied, due to their ease of manipulation and low cost. The conventional methods used to induce pulmonary fibrotic reactions include direct instillation of fibrogenic agents and exposure to thoracic irradiation [4].

Bleomycin animal model is one of the best characterized murine model of pulmonary fibrosis presently in use [5], and this is because pulmonary fibrosis induced by bleomycin exhibits pathology similar to that found in human IPF [6], and produces different patterns of fibrotic lesions depending on the dose and route of application [7].

Bleomycin can be used through different routes like intratracheal route or systemic administration such as intravenous (IV), intraperitoneal (IP), or subcutaneous (SC) [8]. Therefore, reviews of the pulmonary fibrosis model induced by bleomycin have been increasing in popularity [9].

The dose response and time course experiments have determined the amount of drug required to consistently produce a pulmonary fibrotic response when instilled [4]. Intravenous or intraperitoneal routes of administration characteristically induce sub pleural scarring. This versatility in modulating the location of fibrotic lesions offers advantages for studying pulmonary fibrosis with its heterogeneous topography [4].

### Materials and methods

This experimental controlled study was carried out at the Medical Experimental Research Center (MERC) in Mansoura University.

### Materials

**Animals** ; Twenty six C57BL/6 mice with weight ranging between 20–25 gm and ages ranging between 12-16 weeks were maintained under specific pathogen free condition in animal facility of MERC in Mansoura University.

### Chemicals

- Bleomycin hydrochloride vial 15 mg (BLEOCIN 15 mg vial - Nippon Kayaku Co, Ltd). Dry powder of bleomycin hydrochloride dissolved in 7.5 ml sterile sodium chloride 0.9 so each 0.25ml was contained 0.5 mg of active ingredient (Every time prepared fresh and the remaining amount discarded).
- Thiopental sodium vial 1gm dry powdered dissolved in 100 ml normal saline so each 0.5 ml contained 5mg).
- Formalin formaldehyde 10%

### Methods

#### 1. Mice treatment

##### Group (A): Negative control group:

Six C57BL/6 mice (12-16 weeks old) (20-25gm) were included.

Mice were injected intraperitoneal by 0.25ml of sterile saline (0.9 sodium chloride) under complete aseptic conditions twice weekly for eight weeks. At the end of eighth week mice sacrifice was done.

##### Group (B): positive six weeks control group

Every mouse was injected intraperitoneal by 0.5mg bleomycin hydrochloride under complete aseptic conditions twice weekly for six weeks at the end of the sixth week mice sacrifice were done.

##### Group (C): positive eight weeks control group

Every mouse was injected intraperitoneal by 0.5mg bleomycin hydrochloride under complete aseptic conditions twice weekly for eight weeks at the end of the eighth week mice sacrifice were done.

### Mice sacrifice

Mice sacrifice to obtain lungs for histopathological examination

- a. mice received over dose of sodium thiopental (20 mg /kg) through Intraperitoneal injection to kill mice.
- b. Thoracotomy with exposure of trachea were done.
- c. inflation of both lung lobes through trachea with 1ml of 10% formalin formaldehyde, then tracheal ligation and dissection of both lung lobes from thoracic cavity.
- d. Both lung lobes post fixed in formalin, dehydrated and embedded, 2 lobes per block.

### Histopathological examination

3-µm sections were stained with hematoxylin-eosin (HE) and Masson trichrome stain and slides were prepared for examination by pathologist.

### Computer assisted digital image analysis

Slides were photographed by using Olympus digital camera that was installed on Olympus microscope. The result images were analyzed with a specific built-in routine for stain analysis and quantification. Two areas were defined as area of interest the Masson trichrome percent area as indicative for fibrosis and the air percent area as indicative for fibrotic secondary changes. Percent (%) area of the region of interest was calculated and exported to .XLS sheet from which all statistical analysis was done.

### Statistical analysis

Data were tabulated, coded then analyzed using the computer program SPSS (Statistical package for social science) version 17.0 to obtain descriptive data: Descriptive statistics were calculated in the form of Mean and Standard deviation (±SD).

### Analytical statistics

In the statistical comparison between the different groups, the significance of difference was tested using one of the following test:-

Student's t-test:-Used to compare between mean of two groups of numerical (parametric) data.

A P value <0.05 was considered statistically significant in all analyses.

### Results

#### A) Histological analysis

Figure (a) slides prepared from lung specimen of control negative group stained with Masson trichrome show normal lung parenchyma with no collagen deposition or increased with interstitial cellular infiltration on the contrast of figure.

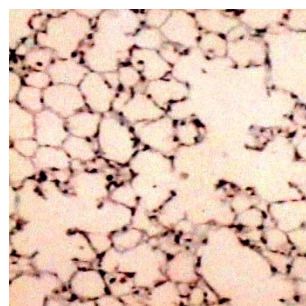
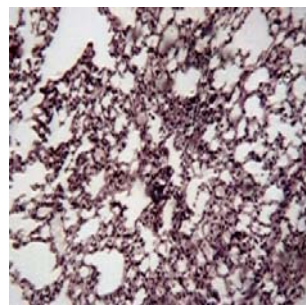


Figure (b) slides prepared from lung specimen of control positive group there is increased area stained with Masson trichrome indicating for lung fibrosis and increased cellular parenchymal infiltrate



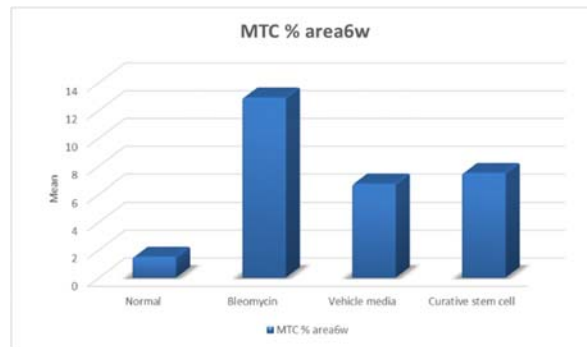
**Results**

**A) Computer assisted digital image analysis results**

**Table 1:** Masson trichrome (MTC) percent area in normal group and other groups at six weeks

		Groups				ANOVA P value
		Normal (n=6)	Bleomycin (n=6)	Vehicle media (n=5)	Curative stem cell (n=6)	
MTC % area6w	Mean	1.50	12.92	6.73	7.49	<0.001
	±SD	0.01	5.06	1.00	1.54	
	P1		<0.001	<0.001	<0.001	
	P2			<0.001	<0.001	
	P3				0.8(N.S)	

N.S=Non significant



**Table 2:** Air percent area in normal group and changes after six weeks bleomycin injection and post treatment by vehicle media and stem cell.

		Groups				ANOVA P value
		Normal (n=6)	Bleomycin (n=6)	Vehicle media (n=5)	Curative stem cell (n=6)	
Air % area 6w	Mean	63.37	8.18	21.86	31.03	<0.001
	±SD	17.06	2.51	5.04	4.79	
	P1		<0.001	<0.001	<0.001	
	P2			<0.001	<0.001	
	P3				0.01	

*Test used:* ANOVA followed by post hoc tukey *SD:* Standard deviation

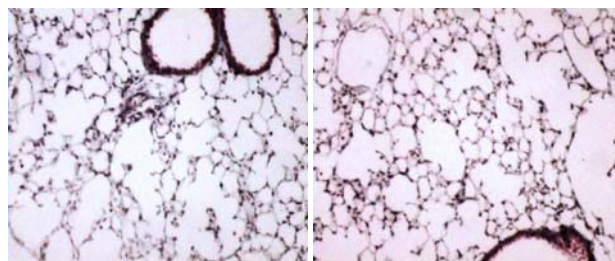
*P1:* Significance of other groups relative to Normal group

*P2:* Significance of Vehicle media and Stem cell groups relative to Bleomycin group

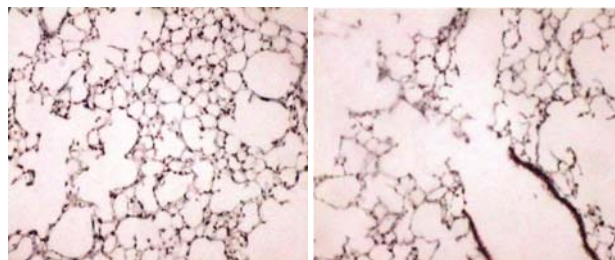
*P3:* Significance of Stem cell group relative to Vehicle media group

**Histological results**

**Negative control group (Normal)**

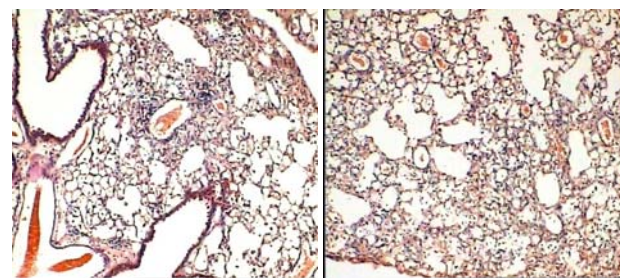
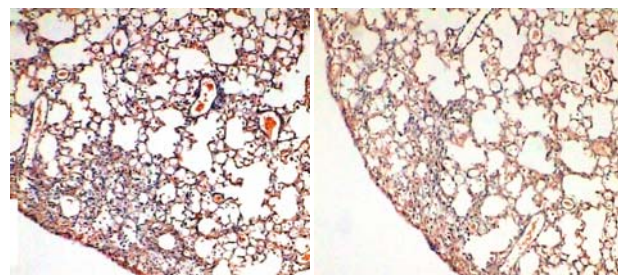


**Fig 44:** Normal thin walled alveolar spaces with no fibrosis (HX&E x100)

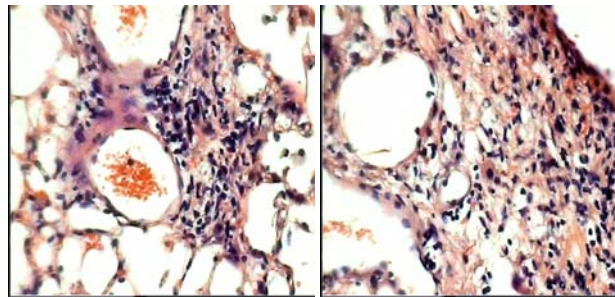


**Fig 45:** Terminal bronchiole ending with alveolar duct budding with thin wall alveoli with no fibrosis (HX&E x100)

**Positive control group (animal model of interstitial pulmonary fibrosis)**

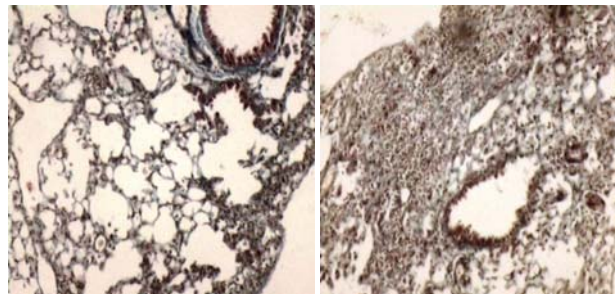


**Fig 46:** The lesion is solidified zones of immature fibrous tissue & inflammatory cells situated mainly in the subpleural area (Masson trichrome x40)

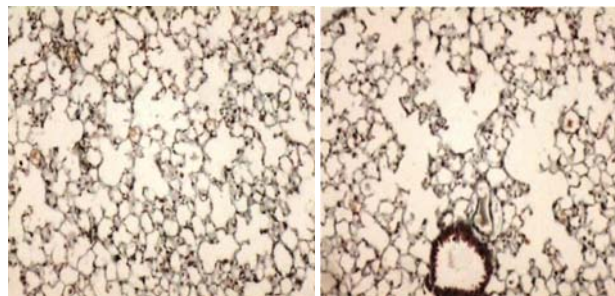
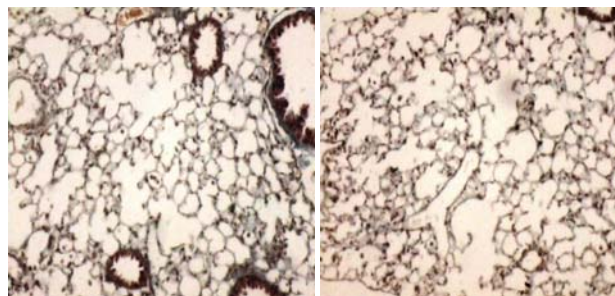


**Fig 47:** Aggregates of ovoid fibroblasts & loose immature fibrous matrix (H&E x100)

**Treated group (Six weeks vehicle media treated group)**



**Fig 54:** Focal subpleural solidification by fibrosis and chronic inflammatory cells (Masson Trichrome stain X100)



**Fig 55:** Non fibrotic well aerated areas with thin alveolar walls. (Masson Trichrome stain X100)

**Table 2:** Air percent area changes in normal group and its changes in eight weeks group

		Groups		P
		Normal	Eight weeks Bleomycin	
Air % area	Mean	63.37	7.12	<0.001
	±SD	17.06	2.27	

The result show that Air percent area was significantly decreased after eight weeks bleomycin injection in comparison with normal group (P1<0.001).

**Table 3:** MTC percent area differences at the six weeks groups and eight weeks groups.

		MTC% area	Bleomycin
6w	Mean		12.92
	±SD		5.06
8w	Mean		15.08
	±SD		6.04
		P	0.2 (N.S)

Test used: T-test SD: Standard deviation P: Probability

There was non-significant difference in MTC percent area between the bleomycin model at six weeks and eight weeks (p=0.2).

**Table 4:** comparison of air percent area in after six and eight weeks

		Air % area	Bleomycin
6w	Mean		8.18
	±SD		2.51
8w	Mean		7.12
	±SD		2.27
		P	0.16 (N.S)

Test used: T-test SD: Standard deviation P: Probability

There was non-significant different in air percent area in groups injected by bleomycin for six weeks compared to those injected for eight weeks (P=0.16).

**Discussion**

Interstitial pulmonary fibrosis includes a group of crippling diseases that associated with a reduction of lung compliance and impairment of the vital gas exchange function as result of excess accumulation of collagen in the interstitium due to inflammatory changes of the lung [14].

In our study we used repeated intraperitoneal bleomycin injection in C57BL/6 mice which resulted in interstitial fibrosis and collagen deposition. Bleomycin has been widely used in inducing pulmonary fibrosis animal models [15]. Repetitive administrations of bleomycin by intraperitoneal or intravenous injection induce pleural and subpleural fibrosis, which is similar to what is seen in human interstitial pulmonary fibrosis [11]. We chose repeated intraperitoneal injection because intratracheal instillation of bleomycin, results in bronchocentric accentuated fibrosis, whereas intravenous or intraperitoneal administration induces subpleural scarring similar to human disease and this was described in review by Chua et al., 2005 [16].

Single doses of bleomycin induce subchronic lesions, but more lasting fibrosis can result from repeated drug dosing (17). In this study we made a model by repeated intraperitoneal injection of bleomycin in C57BL/6 mice twice weekly for six weeks in six weeks group and for eight weeks in eight weeks group and mice were sacrificed at end of the duration. The success of the model was demonstrated by increased collagen deposition as primary outcome which illustrated by Masson trichrome percent area and decrease in air percent area as secondary outcome in comparison with the normal group who receive intraperitoneal saline by the same dose and same duration.

The results were statistically significant (p1<0.001) as illustrated in tables (1-2) and figures (3-4).

These results were in agreement with Izbicki et al., 2002 (18) who used single dose of intratracheal injection of bleomycin followed by mice sacrificing on days 3, 6, 14,

and 21 following intratracheal bleomycin or saline instillation. The degree of fibrosis was quantified by the image analysis computer program. The difference between bleomycin- and saline-treated mice was significant on days 3 ( $P < 0.05$ ), 14 ( $P < 0.001$ ) and 21 ( $P < 0.05$ ).

There was significant histological changes after repeated intraperitoneal injection of bleomycin in comparison with the control negative as evident by Solidified subpleural areas due to early fibrosis and inflammatory cells aggregates. This was supported by the non subjective computer assisted digital image analysis as there was increase in Masson trichrome percent area as illustrated in tables (1) and decrease in air percent area as illustrated in tables (2).

In our study we used two different durations for induction of pulmonary fibrosis by bleomycin injection for six weeks and for eight weeks and there was non- significant difference between them as illustrated in table (3) with ( $P=0.2$ ) for MTC percent area and in table (4) with ( $P=0.16$ ) for air percent area. Fibrosis was more evident at eight weeks group than six weeks group as Mean $\pm$  SD for Masson trichrome percent area was 15.08 $\pm$ 6.04 and 12.92 $\pm$ 5.06 respectively but with no statistical difference. This was supported by what was found earlier by Adamson and Bowden, 1974 they described that the longer the duration the more evident fibrosis but their analysis was none automated and was subjective.

The use of the six weeks model as evident in table (3, 4) can substitute eight weeks model with sparing more effort, time and cost.

### Conclusion

Bleomycin induces fibrosis in C57BL/6 mice by repeated intraperitoneal injection and can be used as a useful tool for studying interstitial pulmonary fibrosis. There is two time courses the six and eight weeks with no statistical difference.

**Conflict of Interest:** no conflict of interest

### References

1. Qingjian Wang, Yinjin Wang, Dallas M Hyde, Philip J Gotwals, Victor E Koteliensky, Sarah T Ryan and Shri N Giri Reduction of bleomycin induced lung fibrosis by transforming growth factor  $\alpha$  soluble receptor in hamsters. *Thorax* 1999; 54:805-812.
2. Wilson MS, Wynn TA. Pulmonary fibrosis: pathogenesis, etiology and regulation. *Mucosal Immunol* 2009; 2:103-121.
3. Soo Nam Kim, Jinsoo Lee, Hyo-Seon Yang, Jae-Woo Cho, Soonjin Kwon, Young-Beom Kim *et al.* Dose-response Effects of Bleomycin on Inflammation and Pulmonary Fibrosis in Mice. *Toxicol Res* 2010; 26(3):217-222.
4. Chua F, Gauldie J, Laurent GH. Pulmonary fibrosis: searching for model answers. *Am J Respir Cell Mol Biol.* 2005; 33:9-13.
5. Moore BB, Hogaboam CM. Murine models of pulmonary fibrosis. *Am. J Physiol Lung Cell Mol Physiol.* 2008; 294:152-160.
6. Chaudhary NI, Schnapp A, Park JE. Pharmacologic differentiation of inflammation and fibrosis in the rat bleomycin model. *Am. J Respir Crit Care Med.* 2006; 173:769-776.

7. Moeller A, Rodriquez-Lecompte JC, Wang L, Gauldie J, Korb M. Models of pulmonary fibrosis. *J Drug Discov Today.* 2006; 3:243-249.
8. Moore BB, Cory MH. Murine models of pulmonary fibrosis. *Am J Physiol Lung Cell Mol Physiol.* 2008; 294:152-160.
9. Scriabine A, Rabin DU. New developments in the therapy of pulmonary fibrosis. *Adv. Pharmacol* 2009; 57:419-464.
10. Briggs AD, Chandler DB, Jackson RM, Fulmer JD. The effect of endotoxin on bleomycin-induced lung fibrosis in the rat. *Toxicol. Lett* 1985; 27:91-96.
11. María Molina-Molina, Javier Pereda, Antoni Xaubeta. Experimental Models for the Study of Pulmonary Fibrosis: Current Usefulness and Future Promise. *Arch Bronconeumol* 2007; 43(9):501-507.
12. Louise Walkin, Sarah E Herrick, Angela Summers, Paul E Brenchley, Catherine M Hoff, Ron Korstanje *et al.* The role of mouse strain differences in the susceptibility to fibrosis: a systematic review *Fibrogenesis & Tissue Repair* 2013, 6:18.
13. Filderman AE, Lazo JS. Murine strain differences in pulmonary bleomycin metabolism. *Biochem Pharmacol* 1991; 42:195-198.
14. Adamson IY, Bowden DH. The pathogenesis of bleomycin-induced pulmonary fibrosis in mice. *Am J Pathol.* 1974; 77(2):185-197.
15. Adamson IY, Bowden DH. Origin of ciliated alveolar epithelial cells in bleomycin-induced lung injury. *Am J Pathol.* 1977; 87(3):569-580.
16. Ashcroft T, Simpson JM, Timbrell V. Simple method of estimating severity of pulmonary fibrosis on a numerical scale. *J Clin Pathol.* 1988; 41:467-470.
17. Chen Li-Jun, Hong Ye, Qian Zhanga, Feng-Zhi Li, Lin-Jie Song, Jie Yang *et al.* Bleomycin induced epithelial-mesenchymal transition (EMT) in pleural mesothelial cells *Toxicology and Applied Pharmacology*, 2015.
18. MJ Segel G, Christensen TG, Conner MW, Breuer R. Time course of bleomycin-induced lung fibrosis. *Int J Exp Pathol.* 2002; 83(3):111-119.