



ISSN Print: 2394-7500  
ISSN Online: 2394-5869  
Impact Factor: 5.2  
IJAR 2017; 3(2): 158-162  
www.allresearchjournal.com  
Received: 26-12-2016  
Accepted: 27-01-2017

**Mane Vijaykumar**  
B.V.D.U. Medical College,  
Sangli, Maharashtra, India

**Mane Shailaja**  
Professor, Department of  
Pediatrics, Dr. D Y Patil  
Medical College, Pune,  
Maharashtra, India

**Mujawar Nilofar**  
P.G. Student in Radiology,  
B.V.D.U. Medical College,  
Sangli, Maharashtra, India

**Namrata Kulkarni**  
Assistant Professor in PSM,  
Govt. Medical College, Miraj,  
Maharashtra, India

**Correspondence**  
**Mane Shailaja**  
Professor, Department of  
Pediatrics, Dr. D Y Patil  
Medical College, Pune,  
Maharashtra, India

## Detection of structural fetal anomalies in third trimester which usually remains undetected in second trimester

**Mane Vijaykumar, Mane Shailaja, Mujawar Nilofar and Namrata Kulkarni**

### Abstract

**Background:** Birth defects are common in human development. Approximately % of newborns have recognizable congenital anomalies in India. Ultrasonography is most useful and widely used tool for antenatal diagnosis of birth defects. Main aim of antenatal ultrasonography is early detection of major fetal anomalies which affect viability or quality of life.

**Keywords:** Structural fetal anomalies, detection rate, third trimester

### 1. Introduction

#### 1.1 Background

Sonographic examination is a commonly performed test during pregnancy in second trimester for detection of structural anomalies in fetus. If major structural anomaly is detected in fetus, medical termination of pregnancy is done after proper counseling with relatives. When anomaly scan is normal, pregnancy is continued. Ultrasonography in third trimester is generally considered as growth scan. Some anomalies might be overlooked if sonography is not done in view to detect anomalies.

Some anomalies can manifest in third trimester as the developmental process continues. The organs are large enough to show structural details in third trimester even those which can be missed in previous examinations due to small fetal size, adverse position or poor resolution of machines.

**1.2 Aim:** Detection of structural fetal anomalies in third trimester and its importance which remains undetected in second trimester usually.

The purpose of study is to know the structural fetal anomalies which are revealed in third trimester first time. Importance of it in planning delivery, perinatal care and parental counseling. It has medico legal significance also.

### 2. Materials and methods

This study includes 10,000 antenatal women who underwent sonography in third trimester in a diagnostic centre, of western part of India which is a semi urban area.

These women underwent anomaly scan in second trimester but no any anomaly was detected in previous scans. The study included women in the third trimester between 24 to 40 weeks (n- 10000) after their informed written consent. Trans abdominal sonography was performed with Acuson 150 Siemens machine with probe having 3.5 MHz transducer for detection of structural anomalies. The sonographic examinations were performed by an experienced radiologist having 10 years' experience in sonography at the beginning of study. The examinations were performed by same radiologist with same machine to minimize the error. Patients in whom one or more anomalies were detected, were followed after delivery to confirm the diagnosis. Most of the neonates with structural anomalies were followed and details were collected.

All data was recorded in database system of sonodoc software and statistical analysis was done with the help of statistician.

**2.1 Exclusion criteria**

The patients who came for sonography first time in third trimester were not included in this study. The patients who

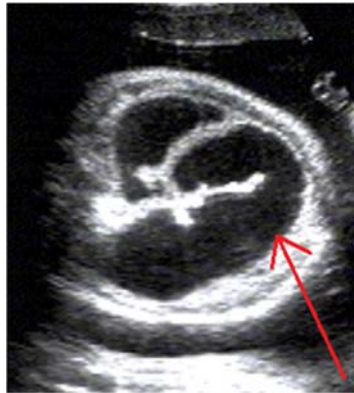refuse to give written consent were not considered for the study. The patients who lost follow up after delivery were also not included in the study.

**Table 1:** Total Structural anomalies detected and diagnosis.

System	Cases (n)	Anomalies
Urogenital	6	hydronephrosis (5) polycystic disease of kidneys (1)
Cardiac	1	V.S.D.
Gastrointestinal	5	Diaphragmatic hernia (1) Oesophageal atresia (1) Bowel atresia (1) Gastric outlet bstruction(1) Intestinal obstruction (1)
Central nervous system	15	Hydrocephalous (5) OND (7) A.C. malformation (1). Aneurysm of vein of Galen (1), Encephalocele (1)
Musculoskeletal	6	Achondroplasia ( 2) CTEV (4)
Others	4	Cleft lip (2 ) Eventration of diaphragm (1) Multiple anomalies (1)

**Table 2:** Total Structural anomalies detected and diagnosis.

Hydronephrosis	Cases	Renal Pelvic AP Diameter
Mild	1	7-9.9 mm
Moderate	2	10-14.9 mm
Severe	2	equal to or > 15 mm



Dilated Small Bowel Loops-Intestinal Obstruction

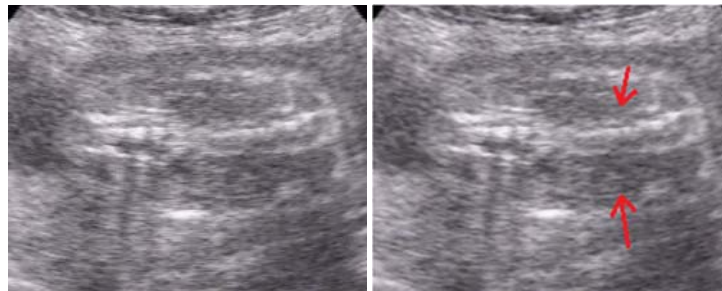
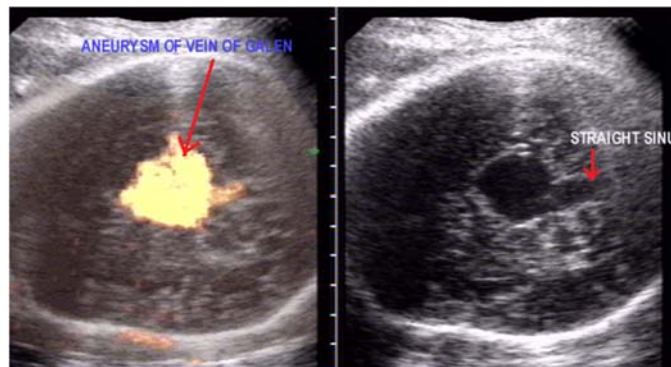


Image at Second Trimester Show Normal P.C. System and Ureters

Image at Third Trimester Show Dilated Ureters



Aneurysm of Vein of Galen

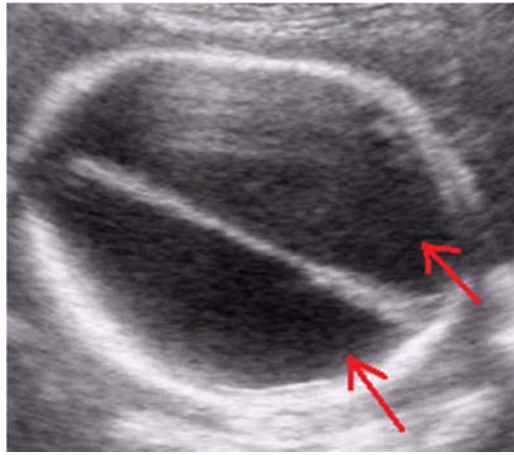


Image Shows Dilated Lateral Ventricles

### 3. Results

The structural fetal anomalies were detected in 37 out of ten thousand patients during ultrasonography in third trimester, which were not detected in earlier antenatal scans. That means detection rate of anomalies in third trimester was 0.37%.

Anomalies of Central nervous system were predominantly detected [15] which include Hydrocephalous [5], open neural tube defect [7], Arnold Chiari malformation [1], Aneurysm of vein of Galen [1] and a small frontal encephalocele [1].

Structural anomalies of urogenital system [6] were detected which includes five cases of hydronephrosis and one case of polycystic disease of kidneys.

The grading of hydronephrosis by Cheng *et al* was followed in this study [28]. We detected 6 cases of hydronephrosis, include mild [1], moderate [2] and severe [3]. Co relate data in this study????

Various anomalies of gastrointestinal tract were seen in five cases Diaphragmatic hernia, Oesophageal atresia, Bowel atresia, Gastric outlet obstruction, Intestinal obstruction one case each.

Achondroplasia was detected in two cases while club foot in four. Small ventricular septal defect was detected in one case.

There were other cases include eventration of dome of diaphragm and one case with multiple anomalies include Combination of limb (dwarf) and CNS (hydrocephalous) anomalies.

Anomalies were detected in three neonates whose antenatal sonographic examination was unremarkable, one case of small open neural tube defect, one case of cleft lip and one case of club foot (one of twins).

This study shows additional detection of anomalies in third trimester (0.37% of cases) while performing anomaly scanning during last trimester. Detection of structural anomalies in third trimester is useful for antenatal and post-natal management of newborns. It is of great help in prenatal parental counselling. It is also important in medico-legal view. There are few anomalies (0.03%) which can be missed in third trimester anomaly scan also.

### 4. Discussion

Due to development of technology and state of the art sonography machines, high resolution probes, the majority of structural anomalies are now days detected at 11 to 14

weeks of gestation. The detection rate of structural anomalies at 11 to 14 weeks is 84% [3].

In study of Srisupundit K, the detection rate by first ultrasound at 11-14 wk scans was 58% (14 from 24 cases) and the most common detected structural anomaly was cystic hygroma and exencephaly [1].

In the study by Eurocat, 50% fetal anomalies were detected prior to 24 weeks, while 53% of the malformations were detected later or remain undetected [2].

So the examination at 11-14 weeks is the anomaly scan which detect Major lethal structural anomalies [4].

Fetal development is a dynamic developmental process. The size of various internal organs increases with gestational age which might help in detection of various anomalies in last trimester. Functions of various systems also increases as gestational age progresses so some anomalies related to function (e.g. urogenital) can be detected in third trimester.

This study shows detection of additional 37 structural anomalies during anomaly scan of third trimester. In this study all anomalies are considered which include cleft lip, cleft palate and club foot.

More than 50% (n -21) anomalies detected belong to central nervous system and urogenital system in this study. In central nervous system, hydrocephalous (n-5) and open neural tube defect (n-7) predominated. Diagnosis of open neural tube defects is possible earlier due to technical development and addition of new signs than previous times. Most of the times, detection of neural tube defect earlier is difficult due to the small defect and lack of classical signs.

The audit of prenatal and postnatal diagnosis of isolated open spina bifida in the Netherlands proved that an ultrasound screening policy based on indications will only detect 22% of all cases before 24 weeks of gestation in contrast to the 66% detection rate in the second trimester reported by the Eurocat study [5]. The growth of fetal brain continues after second trimester and the minor findings like ventricular prominence becomes a significant finding like grossly dilated ventricles in third trimester. Varied pathologies are responsible for the dilatation like aqueduct stenosis, Chiari II malformation, Dandy-Walker complex, corpus callosum agenesis and isolated ventriculomegaly etc.

One case of aneurysm of vein of Galen was first diagnosed in the third trimester which was later delivered in a well-equipped institute which was having all resuscitation facilities. {Till the neonate died due to cardiac failure}

Vein of Galen malformation is a developmental anomaly that usually appears late in pregnancy. Anomaly scan by sonography in the third-trimester is still not done routinely in most of the centres. Many cases of such anomalies are detected only in the neonatal period when clinical symptoms appear [6].

In urogenital system, hydronephrosis is the commonly detected abnormality [7]. Renal tract anomalies are better predicted by foetal hydronephrosis which is detected in the third trimester than second trimester. It is recommended to screen for renal dilatation during incidental antenatal scans in the third trimester, even if prior scans are normal [20].

In this study, three cases of obstruction at pelvi ureteric junction (PUJ) were seen. In one case there was mild, non-significant calyceal fullness in second trimester. But grossly dilated and tortuous ureters (megaureters) were seen in third trimester in the same case.

The cases with hydronephrosis, need post natal follow up as complications like infection are known [24]. One case was having small bladder dystrophy which was missed antenatally. Persistent non-visualisation of urinary bladder is a clue for bladder dystrophy. In such cases, genitalia and pubic symphysis must be seen in detail. In the study by Ranjiv Mathews, prenatal hydronephrosis is secondary to primary ureteropelvic junction obstruction in 65.6%, multicystic kidney in 9.4%, vesicoureteral reflux in 7.0%, duplex system in 5.4%, ureterovesical junction obstruction in 4.0% and posterior urethral valves in 3.0%. [8].

Patients with persistence or worsening hydronephrosis in the third trimester need follow up as higher rates of postnatal pathology are common (9). Postnatal surgery is required in cases with moderate to severe hydronephrosis persisting in the third trimester (10).

In a study by Shipp, a new renal abnormality was detected in 77 (1.8%) of the third-trimester scans when second trimester sonographic examination was normal [23].

Most renal abnormalities first identified in the third trimester after normal findings on a detailed second-trimester structural fetal survey were hydronephrosis and after birth 1/3 rd resolves. 1/3 rd cases which has persistent hydronephrosis were of reflux which were not detected on the second-trimester anomaly scan [11].

Achondroplasia was detected in four cases. Out of it, three cases lost post -natal follow up. One neonate continued with unremarkable abnormality for few years, but malignancy was detected later and undergone surgery for it. Achondroplasia is a non-lethal condition and usually found after 27 wks [12]. Rossi AC *et al* found highest detection rate in neck anomalies (92%), whereas limbs (34%), face (34%), and genitourinary anomalies (34%) were associated with the lowest detection rate [13].

The cases of CTEV are correctable abnormalities but need detection. Prenatal detection of isolated CTEV is important and it helps to to plan postnatal surgery with less complications. Survival is low in complex CTEV which depends on associated anomalies [14].

We found one case of eventration of diaphragm with unremarkable postnatal period. There are many conditions which mimic eventration and having different postnatal management and prognosis [15].

One case of diaphragmatic hernia underwent surgery immediately after birth in the institution. One case of intestinal obstruction, delivered in the institute and underwent surgery post natively without complications. This

emphasize the importance of antenatal detection of structural anomalies in third trimester [16] which helps parents and doctors to arrange delivery and further management of the newborn in a proper institute.

One detected case of esophageal atresia, operated immediately post natively but died due to complications.

One case of cardiac mass in third trimester was detected but case was lost for post natal follow up.

Some fetal malformations remain undetected by early ultrasonography because of late development of some organs and systems [13]. And these abnormalities are not labelled as missed abnormalities on first trimester scan as these appear late due to developmental changes. In study of Rossi AC *et al* its incidence was 64% (28/44).

Even though the result of routine ultrasound in mid trimester is normal, fetal anomalies can be additionally detected in about 20% of cases during the third trimester. S. Lee *et al* detected about 50% anomalies of central nervous system or heart anomalies in third trimester [17].

The third trimester sonography is not beneficial to the mother or baby according to the study by Shipp TD *et al* [22]. Hence a routine third trimester ultrasound scan is not offered in Canada to low-risk pregnancy population [26].

In study of Manegold *et al*, an additional 44 (15%) structural abnormalities were found in the 3 rd trimester include abnormalities of the urogenital system (n = 18), anomalies of the cardiovascular system (n = 9), the gastrointestinal system (n = 6) and the central nervous system (n = 4) [18].

Overall incidence of fetal malformations was 1.9% in R. Gonzalez's study (n=326), of which 31.9% (n=104) were diagnosed at 11-14 weeks. 120 (36.8%) new fetal malformations were found in second trimester and additional 102 (31.3%) structural abnormalities were found in the routine third trimester ultrasound screening which include urogenital system (n=39), followed by congenital heart diseases (n=28) and central nervous system (n=12). Third trimester ultrasound is useful for detection of urogenital anomalies [19] and similar detection rate of the second trimester scan for congenital heart diseases and gastrointestinal system. In study by Hassib NARCHI, 5 cases (4.1%) of anomalies were diagnosed in the third trimester which require termination of pregnancy [20].

These studies justify third trimester sonographic examination for anomaly detection.

A routine ultrasound during the third trimester is therefore justified for study of fetal morphology for detection of anomalies especially anomalies of GI tract, urinary tract and CNS [25].

In Italy, the law (D.M. September 10, 1998) recommends 3 ultrasounds for all pregnant women in first, second and third for all pregnant woman and uses the criteria defined by SIEOG guidelines [21]. The routine ultrasound scan in the third trimester is needed to increase the detection rate of previously unknown structural abnormalities [19] and also useful for perinatal management and postnatal follow-up [18].

Although the rate of detection of structural anomalies in this study is low and statistically insignificant, it is of importance for post-natal management. When these anomalies are diagnosed prenatally, optimal perinatal and postnatal care can be planned. The delivery can be advised in a multi-speciality hospital with a neonatal intensive care unit. It helps for planning of immediate postnatal surgery or close follow-up by team of specialists [18].

To conclude, an additional ultrasound examination, for detection of fetal malformations in the third trimester appears to be justified. But further multicentric, larger studies are recommended.

### 5. References

1. Srisupundit K, Tongsong T, Sirichotiyakul S, Chanprapaph P. *J Med Assoc Thai.* 2006; 89(5):588-93
2. Boyd PA, Devigan C, Khoshnood B *et al.* Survey of prenatal screening policies in Europe. *BJOG.* 2008; 115:689-696.
3. Becker R, Wegner RD. Detailed screening for fetal anomalies and cardiac defects .... *Ultrasound Obstet Gynecol.* 2006; 27:613-618
4. Souka AP, Pilalis A, Kavalakis I *et al.* Screening for major structural abnormalities .... *Am J Obstet Gynecol.* 2006; 194:393-396.
5. Boyd PA, Wellesley DG, De Walle HE *et al.* Evaluation of the prenatal diagnosis of neural tube defects. Europe. *J. Med. Screen.* 2000; 7:169-174. Cohen-Overbeek TE. Rotterdam, 2008.
6. Waldo Sepulveda MD, Tina Vanderheyden, MD, Jayshree Pather *et al.* American Institute of Ultrasound in Medicine, *J Ultrasound Med.* 2003; 22:1395-1398. 0278-4297/03/\$3.50).
7. Aksu N, Yavascan O, Kangin M *et al.* Postnatal management of infants *Pediatr Nephrol.* 2005; 20:1253-9.
8. Ranjiv. Mathews *Indian Journal of Urology Year.* 2006; 22(1):10-14.
9. *Indian Nephrol J.* Mar-Apr; 2013; 23(2):83-97. Sinha A, Bagga A, Krishna A,<sup>1</sup> Bajpai M,<sup>2</sup> Srinivas M,<sup>2</sup> Uppal R,<sup>3</sup> and Agarwal I<sup>4</sup>
10. Sairam S, Al-Habib A, Sasson S, Thilaganathan B. Natural history of fetal hydronephrosis diagnosed on mid-trimester ultrasound. *Ultrasound Obstet Gynecol.* 2001; 17:191-6.
11. Shipp TD, Nguyen HT, Bromley B, Lyons JG, Benacerraf BR. *J Ultrasound Med.* 2011; 30(11):1567-72.
12. Schramm T, Gloning KP, Minderer S *et al.* Prenatal sonographic diagnosis of skeletal dysplasias. *Ultrasound Obstet Gynecol.* 2009; 34:160-170.
13. Rossi AC<sup>1</sup>, Prefumo F. *Obstet Gynecol.* 2013; 122(6):1160-7. doi: 10.1097/AOG.0000000000000015.)
14. Cohen-Overbeek TE(1), Grijseels EWM(1), Lammerink EAG (1), Hop WCJ(2), Wladimiroff JW(1), Diepstraten AFM(3). Rotterdam, 2008.
15. Iskender C<sup>1</sup>, Tarım E, Yalcinkaya C. *J Obstet Gynaecol Res.* 2012; 38(5):858-62. doi: 10.1111/j.1447-0756.2011.01831.x.)
16. Even a Single Third Trimester Antenatal Fetal Screening for Congenital Anomalies can be Life Saving Monika Bawa and Narasimhan Laksmi Kannan *Indian Journal of Pediatrics.* 2010, 77.
17. Lee1 2 S, Jun1 JK, Jung1 J, Kim1 S2, Lee1 J, Kim1 2 B. *et al.* Syn1 22nd World Congress on Ultrasound in Obstetrics and Gynecology. P 30, 19.
18. Manegold G<sup>1</sup>, Tercanli S, Struben H, Huang D, Kang A. *Ultraschall Med.* 2011; 32(4):381-6. doi: 10.1055/s-0029-1245799. Epub 2011 Feb 3.)
19. Gonzalez-Aguero R, Oros D, Tajada *et al.* Splenent: Abstracts of the 24th World Congress on Ultrasound in Obstetrics and Gynecology, Barcelona, Spain, 2014; 44(154):14-17.
20. Hassib NARCHI. Rosamund DONOVAN *Journal of Pediatric Sciences.* 2010; 2(2):e34.
21. Narchi H, Donovan R. Foetal Hydronephrosis and Urinary Tract Anomalies: Third Trimester Versus 20-week Scan. *Journal of Pediatric Sciences.* 2010; 2(2):e34.
22. Carla Verrotti, Eleonora Caforio, Dandolo Gramellini. Giovanni Battista Nardelli *Acta Biomed.* 2007; 78:229-232
23. Ugeskr Laeger. US National Library of Medicine National Institutes of Health Bakketeig LS, 2001; 15:163(42):5813-4.
24. *Ultrasound Med J.* Shipp TD<sup>1</sup>, Nguyen HT, Bromley B, Lyons JG, Benacerraf BR, 2011; 30(11):1567-72.
25. *Ultrasound Obstet Gynecol.* 2005; 25:483-488. Published online in Wiley Inter Science (www.interscience.wiley.com). DOI: 10.1002/uog.1879 A. Wollenberg\*, T. J. Neuhaus†, U. V. Willis and J. Wisser\*
26. Carla Verrotti, Eleonora Caforio, Dandolo Gramellini. Giovanni Battista Nardelli *Acta Biomed.* 2007; 78:229-232.
27. *Obstet Gynaecol Can J,* Le Ray C<sup>1</sup>, Lacerte M, Iglesias MH, Audibert F, Morin L, 2008; 30(2):118-22.
28. Tschudin S, Holzgreve W, Conde N *et al.* Pregnant women's assessment and level of knowledge of prenatal counseling. *Ultraschall in Med.* 2009; 30:157-162.
29. Cheng AM, Phan V, Geary DF, Rosenblum ND. Outcome of isolated antenatal hydronephrosis. *Arch Pediatr Adolesc Med.* 2004; 158:38-40.