



ISSN Print: 2394-7500
ISSN Online: 2394-5869
Impact Factor: 5.2
IJAR 2017; 3(2): 381-383
www.allresearchjournal.com
Received: 29-12-2016
Accepted: 30-01-2017

Eti Mantri
PG student, Dr S.N. Medical
College, Jodhpur, Rajasthan,
India

Sushma K Kataria
Senior Professor and Head of
Department Anatomy, Dr.
S.N. Medical College, Jodhpur,
Rajasthan, India

Mukesh Kumar
Department of Anatomy, Dr.
S.N. Medical College, Jodhpur,
Rajasthan, India

Leena Raichandani
Professor, Department of
Anatomy, Dr. S.N. Medical
College, Jodhpur, Rajasthan,
India

Ritu agarwal
Assistant Professor,
Department of Anatomy, Dr
S.N. Medical College, Jodhpur,
Rajasthan, India

Anoop Gujar
Assistant Professor,
Department of Anatomy, Dr
S.N. Medical College, Jodhpur,
Rajasthan, India

Correspondence

Eti Mantri
PG student, Dr S.N. Medical
College, Jodhpur, Rajasthan,
India

Study of luminal cast plastination in Western Rajasthan

Eti Mantri, Sushma K Kataria, Mukesh Kumar, Leena Raichandani, Ritu Agarwal and Anoop Gujar

Abstract

Aims and objective: To study luminal plastination for seeing the internal of lung which is well known to tracheobronchial tree it is done on goat lung.

To study odorless, easy to demonstrate, 3 dimensional structures in anatomy, best material and easily affordable.

Material and method: Dow corning GP silicone sealant was injected into tracheobronchial tree of goat after thoroughly cleaning the lungs with saline. After the sealant solidified the surrounding lung tissue was destroyed by boiling. Thus a luminal cast was prepared.

Result: The result was sumptuous luminal cast of the Goat lung showing its tracheobronchial pattern.

Conclusion: Plastinated specimens are an excellent alternative to formalin fixed specimens. The plastinated internal Organ are dry odorless, easy to demonstrate the gross morphological details and internal structures. Plastination has a great future in all fields of teaching and research.

Keywords: Luminal plastination, Dow corning GP sealant, tracheobronchial tree, internal structure

1. Introduction

There has always been a quest for knowledge about the interior of human body. Preservation of cadaver play important role in medical education, scientific research of tissue transportation. It can be further used as artistic displays in the museum and educatory exhibitions. For many centuries scientists have tried to create effective and health safe method of conservation and long lasting preservation. The main drawbacks of fixation and preservation of tissues in formalin are that they suffer from easy breakage when handled (brittle), and transportation is tedious process with problem of spillage. Toxicity of formalin is also a major health concern. For reducing health Hazardous Dr Guther Von Hagens, began experimenting on a new technique of preservation of specimens. He mentioned about plastics, and experimented voraciously on diffusing various plastics into large specimens and ultimately succeeded and coined the term "Plastination" in 1977. There are three types of plastination whole organ, sheet and Luminal cast plastination. Luminal plastination can be used to enrich the knowledge of internal structure of anatomy which is of profound importance in present era of advances in therapeutic science.

2. Material and method

The present study was conducted in Department of Anatomy, Dr S.N. Medical College, Jodhpur Rajasthan. Here we used GP sealant and Dow Corning^R GP Silicone Sealant for luminal cast plastination. Fresh organ of animal (lung of goat) were taken from slaughter house.

Material should be

1. Easy to handle
2. Low viscosity
3. Curing should not be inhibited by the presence of tissue.
4. After curing, it should have appropriate mechanical properties i.e Rubber -like- to stimulate a natural state.
5. Should be affordable

Method

- Fresh organ is preferred, because alternations during preservation give a wrong picture of the interior.
- Lumen is cleaned
- Mucus, blood secretion etc will be cleared. Repeatedly 10 – 13 wash with lots of patience.
- After that the excessive amount of water in lumen can be cleaned by tilting the organ and draining towards the gravity.
- The Plastination material used in one of lung is Dow Corning GP silicone sealant and another GP silicone Sealant, both are available as ready packed gel which is injected gently with help of silicone gun.
- Blocking or trying of entry port may be needed to prevent escape of material.
- Kept for 24 hrs.
- Next day dissection of larger easily removable structures and boiling for half to one hour dissolves most of tissues, leaving the beautiful luminal cast materials.
- The Rubber silicone produces an excellent, soft, flexible cast showing an unimaginable 3-Dimensional orientation of cavity.

3. Result

This technique is useful to study the dimensions and architecture of different cavities of organs and to study the tubular- arterial, venous, ductal branches & their variations. The principle involves filling up of the lumen with material and dissolving the surrounding tissue.

The finally plastinated specimens were compared

The responses were recorded as Yes/No (Y/N) as regards to the criteria which were under evaluation. A response of ‘Yes’ was considered as satisfactory.

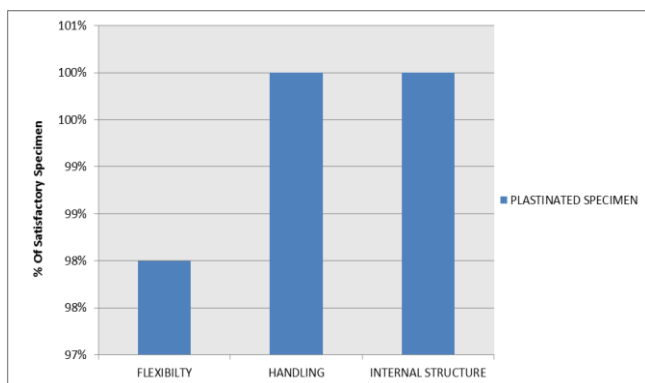
Graph 1: For plastinated specimen

- A) Color Y/N: - Did the specimen maintain Color?
- B) Flexibility Y/N: - Was the specimen Flexible?
- C) Handling Y/N: - Is it easy to Handle?

Graph 2: Material of best luminal plastination

- A) Dow Corning GP silicone sealant Y/N
- B) GP silicone Sealant Y/N

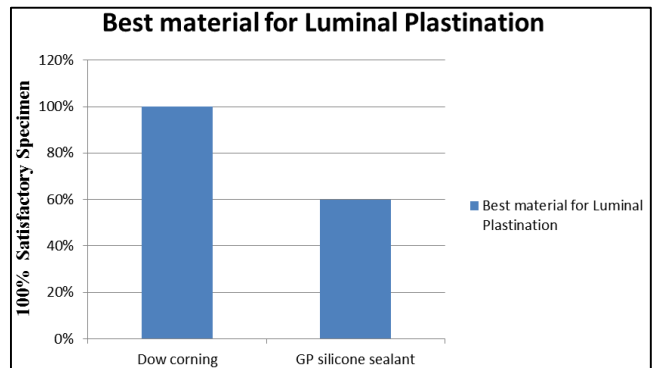
Graph and Explanation is given below



Graph 1: For Plastination Specimen

Specimen was evaluated on the basis of its morphological criteria:-

- 1) Flexibility: - Most of the specimen remained flexible.
- 2) Handling: - Specimen are easy to handle during demonstrate in class room and museum, passed to students without gloves.
- 3) Internal Structure: - In plastinated specimen we obtained best internal structure with 3-Dimensional view



Graph 2: Material Best for Luminal Plastination

Evaluation based on material used in luminal Plastination:- Dow Corning^R GP silicone sealant are resilient flexible, maintain the mechanical property of Post curing i.e. Rubber like consistency and given splendid Luminal Cast Where as in GP silicone Sealant it lost their property after curing it become soften and fragile.



Fig 1: Shown tracheobronchial tree with alveoli, Luminal plastination done with Dow Corning^R silicone sealant

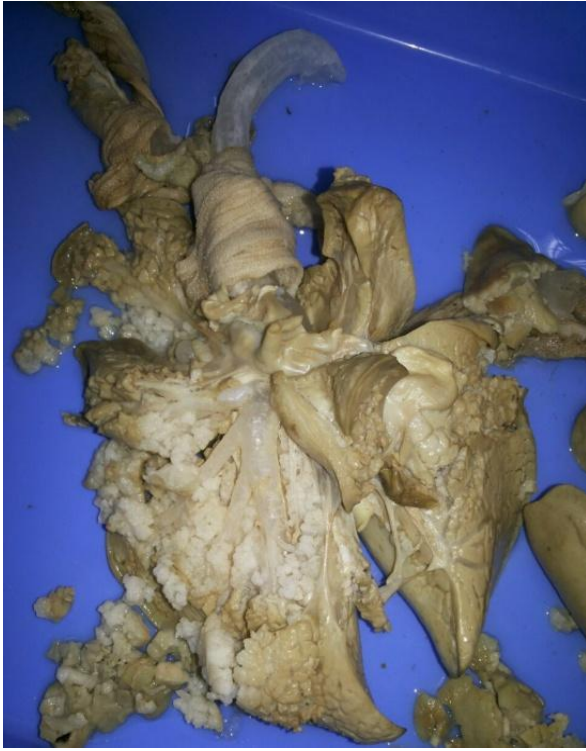

Fig 2: Luminal plastination with GP sealant in which post curing mechanical properties lost.

4. Discussion

In present study we stated that luminal Cast Plastination is best for study Lumen and Unimaginable 3-Dimensional structure in anatomy it can be best obtained by Dow Corning^R GP silicone sealant it is economically affordable. So the institutes can be used for teaching and research purpose. This process is simple, inexpensive and can be carried out in any laboratory to produce dry, odorless, durable, maintenance free and nonhazardous specimens.

Els N.Meeusen *et al* 2009 studied on branching pattern similarity between the two species makes the sheep lung an ideal experimental model to study human airway diseases and effect of medication on diseases like asthma ^[1].

Lee *et al* stated that tracheobronchial cast by injecting the trachea with ERTV silicone. After the injection the trachea was allowed to cure for twenty four hours. The parenchyma was then removed by maceration and boiling and then bleached in 10% solution of hydrogen peroxide, the result was an anatomical replica that illustrated the branching pattern of tracheobronchial tree.

Silva *et al* have described a technique for study of vascular anatomy for liver by injection and erosion methods. The vascular anatomy of liver of rat was demonstrated by injecting a solution of acrylic into portal vein and inferior vena cava. The surrounding soft tissues were then eroded using hydrochloric acid. A vascular cast of liver vasculature was thus prepared.

Steinke *et al* described light – weight plastination using Xylene along with silicone. The resulting plastinates were light-weight, dry and robust. The technique requires less resin making it cost-effective.

Venkatesh G Kamath *et al* was observed that the tracheobronchial division pattern showed significant similarities and a single variation. Therefore the sheep lung is an ideal experimental model and luminal plastination can be applied to comparative anatomical study to identify more such models.

5. Conclusion

Plastinated specimens are an excellent alternative to formalin- fixed specimens. Plastinated specimen can be handled with bare hand. The plastinated internal organs are dry odorless, easy to demonstrate the gross morphological details and internal structures. Plastination has a great future in all fields of teaching and research. The Luminal casts of gastrointestinal system and tracheobronchial system, if well prepared can be used to practice endoscopic procedures. It is good replacement for formalin as a preservative and there are no health hazards. Plastinated specimens can serve as an excellent educational tool for undergraduate and postgraduate students of anatomy, radiology and orthopedics.

6. Acknowledgement

This work was supported by the institution. I am thankful to all.

7. References

1. Meeusen Els N, Snibson Kenneth J, Hirst Stuart J, Bischof Robert J. Sheep as a model species for the study and treatment of human asthma and other respiratory diseases. *Drug discovery Today: Disease Models*. 2009; 6(4):101-106.
2. Prasad Ganesh, Karkera Bhavana, Pandit Siddharth, Desai Dinkar, Rahul Tonse G. Preservation of Tissue by Plastination: A Review, *International Journal of Advanced Health Sciences*. 2015; 1(11):27-31.
3. AC Lee. Tracheobronchial cast production and use in an undergraduate human anatomy course. *Anat Sci Ed*. 2007; 1:23-26.
4. Silva VA, Miranda JS, Brito MVH. Preparation technique for angioarquitectonic liver models in rats *Acta Cir Bras*. 2000; 15:3.
5. Steinke H, Rabi S, Saito T, Sawutti A, Miyaki T, Itoh M *et al*. Light weight plastination *Ann Anat*, 2008; 190(5):428-31.
6. Kamath Venkatesh G, Shetty Radhakrishna K, Asif Muhammed, Ramakrishna A. A comparative study of tracheobronchial Pattern using Luminal Plastination. *Int J Anat Res*. 2013; 03:161-64.
7. Von Hagens G, Tiedemann K, Kriz W. The current potential of plastination *Anat Embryol (Berl)* 1987; 175:411-21.
8. AH weiglein. Preservation of biological tissue: Yesterday-today tomorrow *J Int Soc Plastination*. 2001; 16:31-41.