



ISSN Print: 2394-7500
ISSN Online: 2394-5869
Impact Factor: 5.2
IJAR 2017; 3(2): 98-99
www.allresearchjournal.com
Received: 14-01-2017
Accepted: 15-02-2017

Dr. Sagar Lalani
Junior Resident, Dr. D.Y.
Patil Medical College, Pimpri,
Pune, Maharashtra, India

Dr. Bhargav Yogesh Kaipa
Junior Resident, Dr. D.Y.
Patil Medical College, Pimpri,
Pune, Maharashtra, India

Dr. V Pande
Professor, Dr. D.Y. Patil
Medical College, Pimpri, Pune,
Maharashtra, India

Dr. Shailaja Mane
Professor, Dr. D.Y. Patil
Medical College, Pimpri, Pune,
Maharashtra, India

Dr. Sharad Agarkhedkar
Hod Dept of Pediatrics, Dr.
D.Y. Patil Medical College,
Pimpri, Pune, Maharashtra,
India

Correspondence
Dr. Sagar Lalani
Junior Resident, Dr. D.Y.
Patil Medical College, Pimpri,
Pune, Maharashtra, India

Case report on biliary atresia with CMV infection

Dr. Sagar Lalani, Dr. Bhargav Yogesh Kaipa, Dr. V Pande, Dr. Shailaja Mane and Dr. Sharad Agarkhedkar

Abstract

Human cytomegalovirus (CMV) infection is related to biliary disease, being cholestatic in its own right. It has also been associated with intrahepatic bile duct destruction and duct paucity, indicating a possible role in extrahepatic biliary atresia pathogenesis and progression. When related to biliary atresia CMV IGM positive patients appear to have more liver damage thus affecting outcome.

Keywords: CMV, Biliary Atresia, Kasai Operation, Liver Transplantation

Introduction

Cytomegalovirus (CMV) is known to cause intrahepatic bile duct destruction and paucity, its role as a cause of biliary atresia has been a topic of much debate. It has been suggested that neonatal hepatitis and biliary atresia represent two ends of a spectrum of a single disease process, described by Landing as 'infantile obstructive cholangiopathies' [1].

In congenital and perinatal cytomegalovirus infections 90% of infected infants are asymptomatic in newborn period [2].

We report a 4 month old fch brought with compliant of yellowish discoloration of skin, abdominal distention since 2 months

Case Report

A 4 month old fch brought with compliant of yellowish discoloration of skin & abdominal distention since 2 months

On exclusive breast feeding since birth

H/O abdominal distention progressively increasing since 2 months

H/O passing pale colour stools

H/O passing high coloured urine

No h/o fever, vomiting, loose stool

H/O 3rd degree consanguineous marriage

No significant family history for TB, hepatitis

Full term / NVD / BCIAB, NO H/O Nicu admission, h/o vaccination appropriate for age

General examination

Vitals are stable

Hr: 134, RR: 32, CRT < 3sec, peripheral pulse well felt

Icterus ++, no lymphadenopathy

Systemic examination

CNS: CONCSIOUS, GCS 15/15

CVS: S1 S2 +, NO MURMUR +

RS: AEBE, B/L Clear, No Adventitious Sounds Heard

PA: DISTENDED, Massive Hepatomegaly +, Liver Span: 16 Cm, Liver Size: 9cm

Shifting Dull Ness + For Ascites

Investigations

CBC: HB: 11.9, TLC: 3800, DLC: P 55 L 40 E 02 M 03

Sr. electrolyte: Na 135, K 3.2

CRP – Negative

LFT: total bilirubin: 13.2 direct bilirubin: 11.4

Sgot: 84, sgpt: 102, alp: 178

Pt: 17 sec INR: 1.3

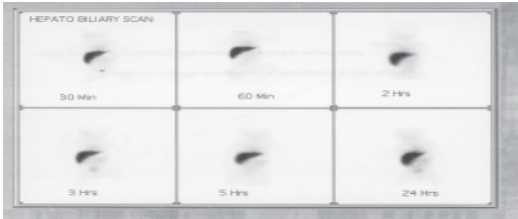
Urine shows positive for bile salts and bile pigments

TFT – with in normal limits

USG ABDOMEN & PELVIS shows streaky gallbladder s/o biliary atresia

Hida Scan (Nuclear Hepato Biliary Study) Shows

- Impaired Liver Function
- No Drainage Is Seen To Intestines



Gamma Glutamyl Transferase is raised

Serum Torch Study Shows: Cmv Igm Positive

Liver Biopsy: shows severe cholestatic liver disease suggestive of biliary atresia with impending liver cirrhosis

Management

Vitamins A D E K

TAB. Vangancyclovir @ 15 Mg /Kg Bd for 6 Weeks

Urosodeoxycholic Acid @ 15 Mg /Kg Bd

Planned for kansai surgery (portoduodenostomy)

Initially patient shown improvement, but due to delay ascites was increased (s/o liver cirrhosis)

So patient referred to higher center for liver transplant

Discussion

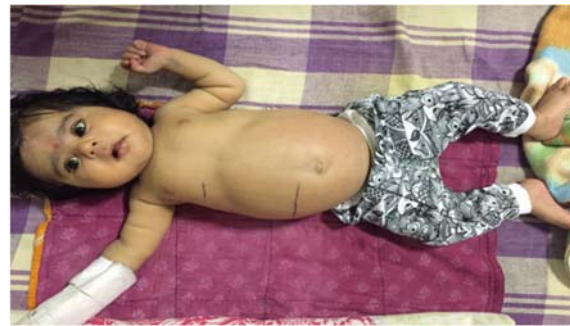An association between cytomegalovirus infection and intrahepatic and extrahepatic forms of neonatal cholestasis has been reported in literature [3]. Whether CMV triggers mechanisms that lead to pathogenesis of biliary atresia remains unproven [4]. CMV replicates in both hepatocytes and cholangiocytes during infection and liver damage may be related to direct cytopathic effect or the immune response of the host [1].

Chang, *et al.* have reported that CMV DNA was detected in 46% of babies with neonatal hepatitis and suggested that CMV could play a major role in pathogenesis of neonatal hepatitis [5]. Fischler, *et al.* [1] found that in patients with biliary atresia and CMV, IgM deposits were significantly higher on liver biopsies than in biliary atresia patients without CMV, suggesting that CMV may be triggering immunologic processes causing biliary atresia.

However, treatment of CMV in patients with biliary atresia has not been studied much and its effect on outcome is not known. Increasing number of studies indicate the necessity of treatment, especially in cases with symptoms of acute or chronic cholestatic hepatitis or proven histopathological findings [4]. Currently, there are four antivirals available for treatments of CMV infection are ganciclovir, valganciclovir, foscarnet and cidofovir [1].

CMV is common cause of biliary atresia

Biliary atresia is most common cause of liver transplantation.



References

1. Fischler B, Svensson JF, Nemeth A. Early cytomegalovirus infection and the long-term outcome of biliary atresia. *Acta Paediatr.* 2009; 98:1600-2.
2. Rauschenfels S, Krassmann M, Al-Masri AN, Verhagen W, Leonhardt J, Kuebler JF *et al.* Incidence of hepatotropic viruses in biliary atresia. *Eur J Pediatr.* 2009; 168:469-76.
3. Sanghai S, Shah I, Bhatnagar S, Murthy A. incidence and prognostic factors associated with biliary atresia in western India. *Annals Hepatol.* 2009; 8:120-2.
4. Miiler A, Eis-Hubinger AM, Brandhorst G, Heep A, Bartmann P, Franz AR. Oral valganciclovir for symptomatic congenital cytomegalovirus infection in an extremely low birth weight infant. *J Perinatol.* 2008; 28:74-6.
5. Chang MH, Huang HH, Huang ES, Kao CL, Hsu HY, Lee CY. Polymerase chain reaction to detect human cytomegalovirus in livers of infants with neonatal hepatitis. *Gastroenterology.* 1992; 103:1022-5.