



ISSN Print: 2394-7500  
ISSN Online: 2394-5869  
Impact Factor: 5.2  
IJAR 2017; 3(4): 518-520  
www.allresearchjournal.com  
Received: 16-02-2017  
Accepted: 17-03-2017

**Dr. Vipin Garsa**  
Associate Professor,  
Department of Anatomy,  
Pandit Bhagwat Dayal  
Sharma PGIMS, Rohtak,  
Haryana, India

**Dr. Ravi Kant Narayan**  
Junior Resident, Department  
of Anatomy, Pandit Bhagwat  
Dayal Sharma PGIMS,  
Rohtak, Haryana, India

**Dr. Neeru Gahlawat**  
Senior Resident, Department  
of Anatomy, Pandit Bhagwat  
Dayal Sharma PGIMS,  
Rohtak, Haryana, India

**Dr. Sanjay Gupta**  
Assistant Professor,  
Department of Anatomy,  
Pandit Bhagwat Dayal  
Sharma PGIMS, Rohtak,  
Haryana, India

## Teaching anatomy with atlas & coloured specimen

**Dr. Vipin Garsa, Dr. Ravi Kant Narayan, Dr. Neeru Gahlawat and Dr. Sanjay Gupta**

### Abstract

Being the foundation stone in the medical curriculum, the comprehensive knowledge of anatomy plays a vital role in the proper understanding of any other branch of medicine. But, learning anatomy has become a rite of passage rather than an educationally valid process and clearly, requires reform. This reform has to be from teaching aspect, regarding which this study was structured to evaluate the response of undergraduates to the methodology of teaching anatomy with the combination of an anatomical atlas and coloured prosections.

**Keywords:** Teaching methodology, anatomical atlas, coloured prosections

### 1. Introduction

Studying anatomy has been the foundation stone in the medical curriculum. The comprehensive knowledge of anatomy plays a vital role in the proper understanding of any other branch of medicine [1]. Regardless of the fact, there has been squeezing of the time and resources being devoted to anatomy. This has resulted in the decrease of knowledge of the subject below an acceptable level in qualifying doctors, which as a fact has been supported by some studies [2].

Anatomy as a subject has suffered due to its failure to evolve and adapt quickly enough. Learning anatomy became a rite of passage rather than an educationally valid process and clearly, requires reform. It is debatable whether this decline of anatomy is a result of reductions in time and resources allocated to anatomy teaching or is it a result of the changes in teaching methodology [2].

Teaching methodologies have evolved from routine dissection to web-based study. This transition was gradual with methodologies like textbooks, anatomical atlas, coloured live body demonstrations, plastinated prosections, clay models, pre-dissected specimens, radiological techniques and among the recent one is digital simulations of different parts of human body [1,3].

Among these methodologies, using the combination of an anatomical atlas and coloured prosections can be one of the chief methods in present day scenario to overcome the issues of dissection and web-based simulation techniques.

This study was aimed to evaluate the response of undergraduates to the teaching methodology of the combination of an anatomical atlas and coloured prosections.

### 2. Material and Method:

The present study was done during the teaching curriculum of undergraduate medical students in the Department of Anatomy, Pt. B. D. Sharma PGIMS, Rohtak. Here, we did stepwise dissection and colouring of the specimen of vascular structures related to the hilum of the lung. After drying, the coloured prosections were photographed and explained.

Dissection was done in a sequential manner so as to preserve the vascular structure of hilum, aorta, superior vena cava, arch of azygous vein and brachiocephalic vein. After completing dissection, the specimen was dried by exposing to air in absence of sunlight. We used fabric colours for features of the structures to be expressed accurately. Rohmehtra M *et al* made the models using enamel colour which was an innovative way of making the structures attractive [4].

**Correspondence**  
**Dr. Vipin Garsa**  
Associate Professor,  
Department of Anatomy,  
Pandit Bhagwat Dayal  
Sharma PGIMS, Rohtak,  
Haryana, India

A Proper colouring of the structures was done simultaneously by using cotton blocks between coloured specimen to avoid mixing. This proved to be time-saving compared to the coloured dissections in which structures were coloured individually and then whole day was devoted to dry the same.

A batch of 30 students was taught about the vascular structure of hilum, aorta, superior vena cava, arch of azygous vein and brachiocephalic vein with the help of

Frank H. Netter's atlas of human anatomy [5]. Then they were first asked to identify structures on uncoloured dissection and later, on coloured dissection as shown in Fig. 1 to 8. The response of the students was observed and subjected to statistical analysis, where Group A was the response of students in coloured dissections while Group B indicates their reply to uncoloured dissections.

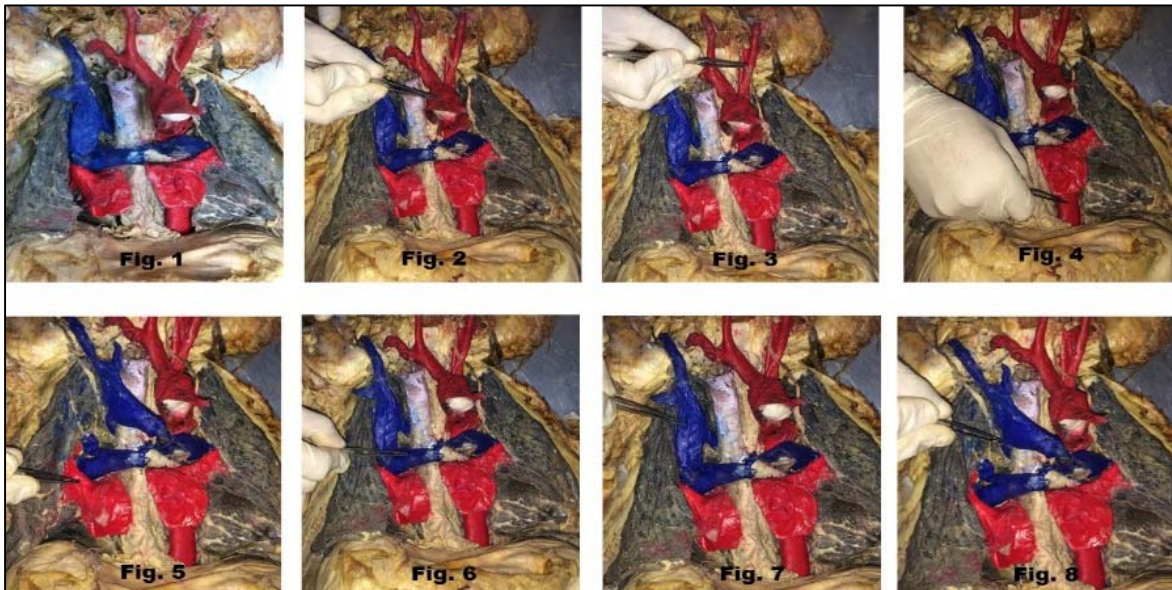


Fig 1 to 8: Showing vascular structure of hilum, aorta, superior vena cava, arch of azygous vein and brachiocephalic vein.

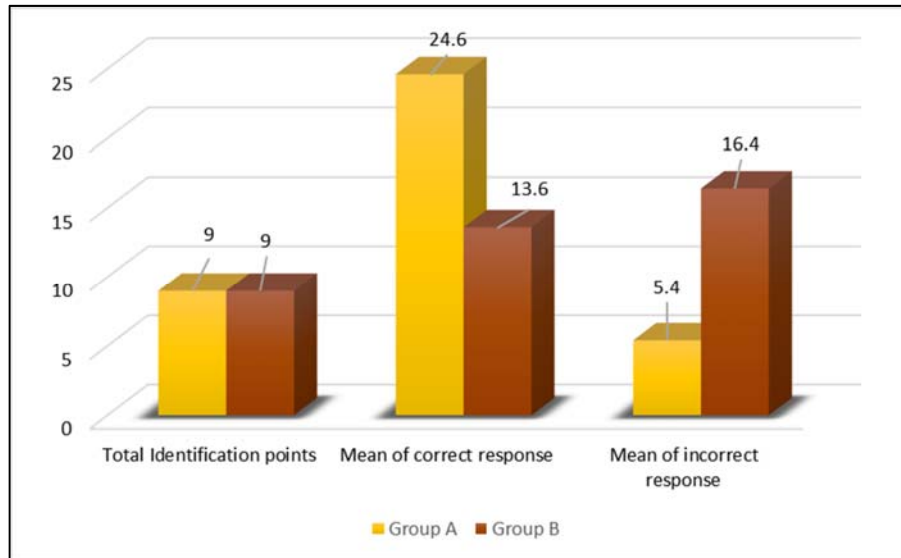
## 2. Results & Discussion

Table 1: Student's response to structure identification

Students identification	Group A		Group B	
	Correct	Incorrect	Correct	Incorrect
Arch of Aorta (Fig. 2)	27	3	26	4
Branches of Arch of Aorta (Fig. 3)	26	4	17	13
Ascending Aorta	28	2	27	3
Descending Thoracic Aorta (Fig. 4)	26	4	19	11
Pulmonary Veins (Fig. 5)	25	5	7	23
Pulmonary Artery (Fig. 6)	24	6	9	21
Superior Vena Cava (Fig. 7)	22	8	5	25
Arch of Azygous Vein (Fig. 8)	22	8	4	26
Brachiocephalic Vein	21	9	8	22
Total	221	49	122	148

Table 2: Statistical Analysis of Student's Response

	Group A	Group B
Total Identification points	9	9
Mean of correct response	24.6	13.6
Mean of incorrect response	5.4	16.4
Standard Deviation	2.5	8.9



**Fig 1:** Graph Showing Statistical Analysis of Student's Response

Table 1 shows the comparison of response given by students in identification of 9 structures on coloured (Group A) and uncoloured (Group B) specimens. Group A accounted for better results as compared to Group B.

The colours of dissected specimen vary from various shades of pink, yellow to white. Some veins appear dark in colour due to the presence of clotted blood. When the 1<sup>st</sup> year MBBS students try to identify different structures, they usually refer to coloured diagrams of an atlas of anatomy. But the dissected specimens are not of the same colour as represented in the atlas. This creates difficulty for the untrained mind of 1st-year students to sort out different structures as reflected in Group B results with a mean of incorrect identifications ( $16.4 \pm 8.9$ ) being higher than the same for Group A ( $5.4 \pm 2.5$ ) as shown in Table 2.

With coloured specimens, the mean of correct identification ( $24.6 \pm 2.5$ ) was observed to be almost twice the value seen with the uncoloured specimen ( $13.6 \pm 8.9$ ) as can be seen in Table 2 and the graph.

#### 4. Conclusion

Anatomy teaching methodologies have varied with time. But the simultaneous use of an anatomical atlas and coloured prosection has statistically proven to be efficient in understanding the orientation of the human body. Hence, the incorporation of colours in dissected prosections for training the undergraduates makes the understanding of the subject a bit easy.

#### 5. Reference

1. Benly P. Teaching Methodologies on Anatomy- A Review, J. Pharm. Sci. & Res. 2014; 6(6):242-243.
2. Turney BW. Anatomy in a Modern Medical Curriculum, Ann R Coll Surg Engl. 2007; 89:104-107.
3. McNulty JA, Sonntag B, Sinacore JM. Evaluation of Computer-Aided Instruction in a Gross Anatomy Course: A Six-year Study. Anat Sci Ed. 2009; 2(2):1-8.
4. Rohmeotra M, Kazi SN. An innovative method of making anatomy teaching mode – Kidney. J Anat Soc India. 2007; 55(1):123.
5. Netter FH. Atlas of Human Anatomy. 6<sup>th</sup> ed, Elsevier, Philadelphia, 2011, 330-350.