



ISSN Print: 2394-7500
ISSN Online: 2394-5869
Impact Factor: 5.2
IJAR 2017; 3(4): 885-890
www.allresearchjournal.com
Received: 22-02-2017
Accepted: 25-03-2017

Dr. Sasmita Parida
Associate Professor, SCB
Medical College, Cuttack,
Odisha, India

CT Evaluation of gastric neoplasm with Histo-pathological correction

Dr. Sasmita Parida

Abstract

Introduction: Gastric carcinoma is the seventh most common cause of cancer related death in the United States and it also has an increased prevalence in Eastern Europe as well as in Asian countries. Early diagnosis and staging of gastric cancer always remains as a challenge for the clinician to do the best treatment planning for the patients.

Aim: The aim of this present study was to find out the distribution, feature, localization, extent and tissue characteristics of gastric neoplasm by computed tomography and to correlate with the histo-pathological features.

Material and methods: It was a prospective study conducted in the department of radio diagnosis of S.C.B medical College, Cuttack, Odisha during September 2011 to September 2013 (2 years). Patients with provisional diagnosis of gastric neoplasm were subjected to contrast enhanced CT scan of abdomen and upper gastrointestinal endoscopic biopsy.

Result: Out of 60 patients 40 patients were male and 20 patients were female with median age group of 51 to 60 years (mean age 56.9 years). Pyloric antrum was involved in 33.3% of cases followed by body of stomach (31.7%). Concentric wall thickness was seen in 86.7% of cases. Average wall thickness was 1.8cm. Lymphadenopathy was observed in 81.7% cases. Contiguous structure involvement was seen most commonly as fat stranding and involvement of gastro-oesophageal junction and pancreas. Metastasis to liver and ovary were also noted.

Conclusion: CT evaluation of stomach is helpful in detection and evaluation of variety of benign and malignant neoplasms with adjacent structure involvement in a non-invasive way. It also helps in detection of distant metastasis.

Keywords: Abdominal Pain, Adenocarcinoma, Computed Tomography, Lymphadenopathy, Neoplasm Staging

Introduction

Gastric carcinomas represents the most common neoplasm accounting for 95% of all gastric tumors ^[1]. It represents an aggressive tumor with a 5 year survival rate less than 20% ^[2]. In Japan the prevalence of gastric carcinoma is very high with mortality rate about 110 per 100000 inhabitants. Alcohol and smoking do not influence the incidence of gastric carcinoma like oesophageal carcinoma but hot and salty foods do have an impact ^[3]. Epigastric pain syndrome, dyspepsia, anemia, weight loss and weakness are the most common presenting symptoms. Stage of the disease at the time of presentation determines the treatment and the prognosis of the patient ^[3]. Proper therapeutic approach depends on early diagnosis and accurate staging of the disease. It also affects the survival rate of the patients ^[4].

Surgery is the choice of treatment in most cases which is planned by preoperative staging of the disease. Because CT can identify the primary tumor, assess the local spread, detect the nodal involvement and distant metastasis, it is currently the staging modality of the choice ^[5]. Multi detector CT with its multi planar reconstruction has improved the depth evaluation of gastric carcinoma with its high spatial resolution and faster examination time. It is commonly used as the modality of choice for the preoperative staging of the gastric cancer. It has less motion artifacts so gives better image quality, better reconstruction with an overall greater diagnostic accuracy. Depth of the tumor invasion is a good therapeutic and prognostic factor which is best evaluated by MDCT. So role of computed tomography is becoming stronger for these patients as technology improves ^[6].

Correspondence
Dr. Sasmita Parida
Associate Professor, SCB
Medical College, Cuttack,
Odisha, India

MDCT helps in preoperative staging of gastric carcinoma, post therapeutic follow up and detection of recurrences. In some cases it also detects new cases incidentally. Detailed CT examination of stomach is performed with water as an oral contrast agent along with a rapid intravenous contrast material bolus and thin collimation which is the advantage of newer technology. This is helpful in detection of various conditions of stomach including gastric neoplasm. CT angiography is especially helpful for identification of perigastric vasculature. Multiplanar reconstruction (MPR) gives significantly better overall accuracy than transverse images for tumor staging but not for lymph node staging [7].

In conjunction with endoscopic biopsy (UGIE biopsy) MDCT is the modality of choice for treatment planning and provides useful information for comparison during chemotherapy in patients with inoperable carcinoma [8].

The aim of the present study was to study the demographic profile of the patients with gastric neoplasm and to assess the distribution, feature, localization and extent of the neoplasm. This study also correlates the tissue characterization by computed tomography with that of the histo-pathological examination.

Materials and methods

This was a prospective study done in the department of radio diagnosis SCB Medical College from September 2011 to September 2013.

Inclusion criteria:

Patients with either sex and all age groups with relevant clinical signs and symptoms of upper gastro intestinal tumor and with positive ultra sonographic finding of the same were included in the study. The patients with positive USG findings were subjected for CECT of abdomen, upper GI endoscopic biopsy and histopathological correlation. All the obtained data were tabulated and expressed in percentage.

Exclusion criteria

All cases of pancreatitis, traumatic and drug induced gastric pathologies were excluded from the study. Non cooperative, claustrophobic patients and pregnant ladies with upper gastro intestinal mass on ultrasound were also excluded.

CT protocol

Patients were advised overnight fasting and nil orally in the morning prior to the investigation. Thorough history of allergy to any food or medication where taken. Blood urea and serum creatinine levels were checked. Routine blood counts and hemoglobin percentage were checked for any abnormality.

The patients were given water approximately 30 to 45 minutes prior to the study. An additional 250 ml of water was given just before the scanning. Non-ionic contrast material, 100 ml of ultravist 300 [Iopromide; Bayer Pharma AG, Germany] was routinely injected at the rate of 3 ml per second. Arterial phase images were acquired 25 seconds after the beginning of contrast injection. Venous phase images were obtained 50 seconds after the start of the injection. For detailed imaging of stomach and 3D reconstruction, we utilized our 16 slice MDCT scanner (GE, Bright Speed, 16 slice MDCT) to obtain 0.5mm slices, acquired at the rate of 32 slices per second. These thin slices acquired at a fast rate resulted in high resolution data sets with minimal artifacts. This dual-phase protocol produces

angiographic quality delineation of gastric artery and vein as well as visualization of liver metastasis.

Statistical analysis

The findings of clinical examination, CT and histo-pathological study were tabulated. The descriptive analysis was done for the collected data. All the data were expressed in percentages.

Results

In our study out of 60 patients three cases were less than 40 years (5%), 15 cases were between 41 to 50 years (25%), 26 cases are within 51 to 60 years (43.3%) and 16 cases were above 60 years (26.7 %). The most common median age group in our study was 51 to 60 years. The male to female ratio was 2:1. Loss of weight was observed in 75% of cases followed by dyspepsia/ epigastric pain (58.3%) and loss of appetite (50%). Majority of our cases belonged to lower socio economic status (93.3%). Among risk factors GERD (Gastro oesophageal reflux disease) was the highest (48.3%), followed by smoking (35%), obesity (6.7%), family history (1.7%), 4 cases (6.7%) were found to have no definitive risk factors. We found the most common site of involvement in gastric carcinoma was pyloric antrum region (33.3%) followed by body of stomach (31.7%) (Table/figure 1, Table/figure 2). Diffused pattern were found in 11.7% of cases.

In our CT findings most common finding was the concentric variety (86.7%) followed by polypoidal (3.3%) and exophytic/ globular variety (3.3%). (Table/figure 3, Table/figure 4)

In the concentric variety wall thickness varies from 1.1cm to 4cm with average wall thickness being 1.8cm. Wall thicknesses more than 1 centimeter were associated with malignancy. (Table/figure 5)

In CT most of the lesions were hypodense (80%), among them 97.9% were malignant. 10 cases were isodense out of which 70% were malignant. Two cases were hypodense with calcification and came out as mucinous adenocarcinoma (Table/figure 6). After IV contrast study 46 cases were moderately enhanced and found out to be malignant, 1 intensely enhancing lesion came out as carcinoid out of 4 minimally enhancing lesions one was lymphoma and other 3 were inflammatory, 9 cases were heterogeneously enhancing out of which 8 were malignant and 1 benign GIST. (Table/figure 7, Table/figure 8, Table/figure 9, Table/figure 10)

We found involvement of perigastric node in 97.9% cases. All were associated with malignancy. Most common range of transverse diameter was 1-1.5cms. All nodes were hypodense and 3 cases showed necrosis within. (Table/figure 11, Table/figure 12)

Most common adjacent structure extension was peri-lesional fat stranding (30%) GEJ (Gastro oesophageal junction) (23.3%), pancreas (18.3%). Out of 60 patients in our study UGIE (Upper gastro intestinal endoscopy) biopsy showed 57 cases of gastric tumor and 3 cases as inflammatory wall thickening. Among 57 cases of gastric neoplasm 54 cases (90%) were adenocarcinoma out of which two cases were of mucinous variety and one case each of lymphoma, carcinoid and GIST. (Table/figure 13, Table/figure 14)

CT shows metastasis to liver in 21 cases, ovary in 2 cases, bone in one case (Table/figure 15). Ascites was associated in 35% cases, pleural effusion in 16.7% of cases. (Table/figure 16)

Table 1: site of lesions according to CT findings.

Location	Number	Percentage
Cardia/ cardia fundus	14	23.3
Body/Body-Antrum/Body-Antrum-Pylorus	19	31.7
Antrum/pylorus/both	20	33.3
Diffused	7	11.7
Total	60	100

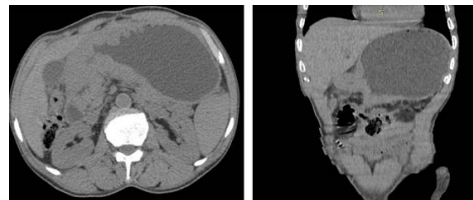


Fig 2: CT scan showing gastric carcinoma involving antrum and pylorus. A. axial, B. Coronal.

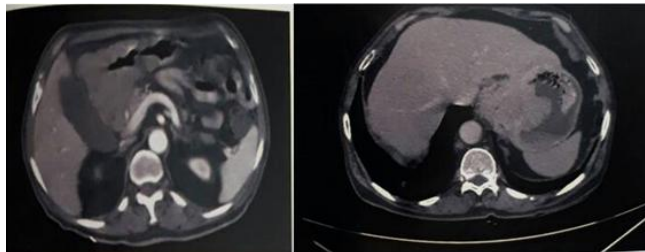


Fig 3: CT scan showing different pattern of gastric carcinoma: a. Concentric b. Polypoidal.

Table 4: types of lesions in ct with histopathology correlation.

Ct Findings			Histopathology	
Type of Mass	Number	%	Malignant	Benign
Concentric	52	86.7	51-Adenocarcinoma	0
			1-Lymphoma	
Nodular	1	1.7	1-Adenocarcinoma	0
Polypoidal	2	3.3	1-Adenocarcinoma	0
			1-Carcinoid	
Exophytic/Globular	2	3.3	1-Adenocarcinoma	1-Gastro Intestinal Stromal Tumor
Focal	3	5	0	Inflammatory

Table 5: distribution of concentric wall thickening with histo-pathological correlation.

Thickening	Number	Histo pathology	
		Benign	Malignant
<1cm	3	3(infilm)	0
1-2cm	34	0	34
>2cm	18	0	18

Table 6: CT finding showing distribution of cases according to density.

Density	Number	Malignant	Benign
Hypodense	48	47(97.9%)	1
Isodense	10	7(70%)	3(inflammatory)
Hypodense with CA+2	2	2	0

Table 7: CT finding showing distribution of cases according to enhancement.

Enhancement	Number	Malignant	Benign
Minimum	4	1	3
Moderate	46	46	0
Intense	1	1	0
Heterogeneous	9	8	1

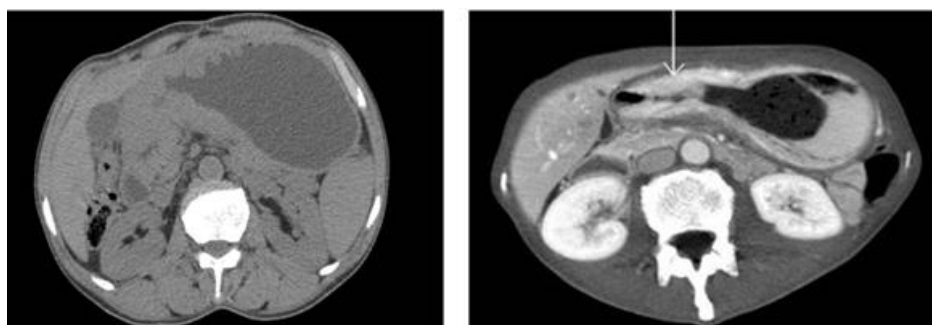


Fig 8: CT showing low density mural thickening with wall enhancement. A. NCCT, B. CECT.

Table 9: Histopathological Types of Gastric Carcinoma.

Type	Number	%
Adenocarcinoma	54	90
Lymphoma (Maltoma)	1	1.7
Carcinoids	1	1.7
Gist (Benign)	1	1.7
Inflammatory	3	5

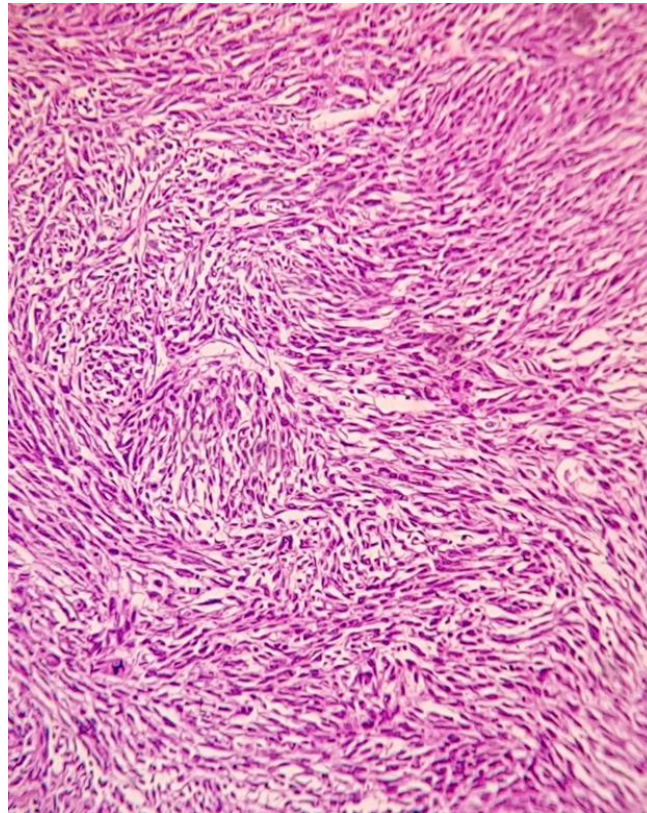


Fig 10: Histopathology showing spindle cell GIST.

Table 11: CT showing involvement of lymph nodes.

Lymphadenopathy Groups	Number	% (Out Of 49 Cases)
Perigastric	48	97.9
Peripancreatic	28	57.1
Celiac	9	18.3
Splenic	6	12.2
Hepatic	14	28.5
Para-Aortic	3	6.1

Table 12: size of lymph nodes in CT (mean transverse diameter).

Diameter	Number	%	Density	
			Hypo	Hypo with necrosis
<1cm(0.9cm)	1	2.04	1	
1-1.5cm	47	95.92	44	3
>1.5cm	1	2.04	1	

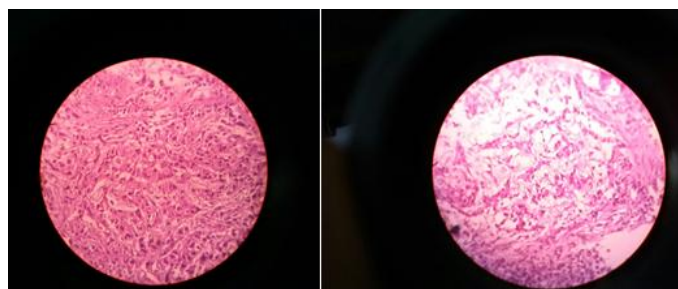


Fig 13: Poorly differentiated adenocarcinoma of stomach in diffused pattern.

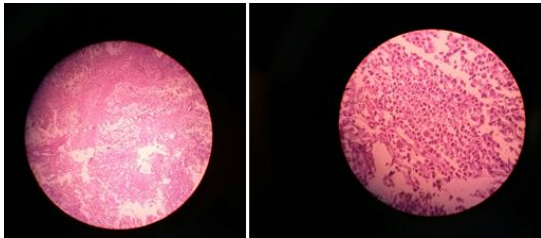


Fig 14: Low and high power view showing mucin secreting adenocarcinoma of stomach.

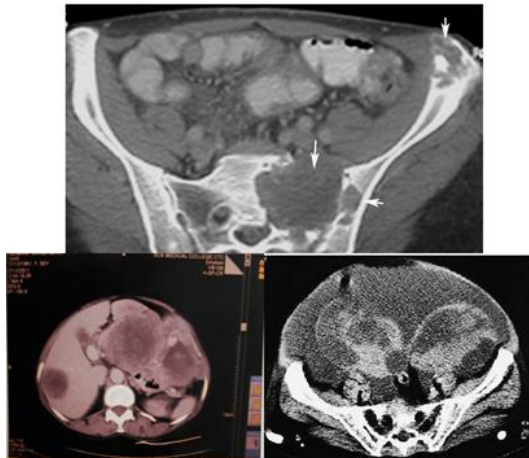


Fig 15: gastric carcinoma with metastasis to: a. bone, b. liver, c. bilateral ovary.

Table 16: Ct Showing Metastatic Lesions.

Findings	Number	%
Lymphadenopathy	49	81.7
Ascites	21	35
Effusion	10	16.7
Metastases To Liver	21	35
Metastases To Bone	1	1.7
Krukenberg Tumor (Metastasis To Bilateral Ovary)	2	3.3

Discussion

Water can distend the stomach optimally and is well tolerated by all the patients. It has no cost and no complications and does not interfere with data manipulation because of its low CT density. So water is preferred as low density contrast material in case of CT Staging of gastric carcinoma. MDCT with IV contrast enhancement and distension of stomach with low density contrast material can give detailed visualization of gastric wall in the site of involvement. Multi planar reconstruction of coronal and sagittal planes can give accurate diagnosis and Staging of primary lesions. The arterial phase helps in Staging because it gives maximum enhancement of gastric wall [9, 10]. Our study showed that gastric carcinoma in male is twice as common as in females. A study conducted by Hye Seong Ahn *et al.* showed similar result where the male to female ratio was 1.78:1 [9]. Main clinical presentation being anorexia and weight loss followed by abdominal pain which was insidious and vague in nature [10]. Infiltrative and obstructive tumors cause nausea, vomiting and early satiety. Low socio-economic status, obesity, chronic atrophic gastritis are the risk factors for gastric carcinoma [11]. It was also studied that cigarette smoking causes two to three fold increase risk of gastric malignancy [12].

Common site of involvement of stomach in descending order are: antrum (30%), body (30%), fundus (30%) and diffused type (10%). A study done by Ba-Ssalamah showed similar pattern of distribution of gastric carcinoma [13]. In CT diffused wall thickening was seen in 95% of cases where as polypoidal mass in 6% of cases [14].

Gastric wall thickness of malignant neoplasms are in the range of 6mm-4cm with an average being 2cm which was comparable with the findings of Fishman EK *et al.* [15]. Neoplastic tissue is usually hypodense in NCCT and takes good enhancement after iv contrast injection. In rare cases tumor can appear iso-dense to the stomach wall [16]. Mucinous variety of adenocarcinoma is a rare entity and characteristically it shows calcification within the tumor. Study done by Cyan *et al.* was well correlated with the finding of our study [17]. Lymph node involvement depends on the site of tumor but most common is the perigastric node involvement [18].

Criteria for lymph node involvement were size more than 5mm, round shape, hypodense pattern and smooth border. If two or more criteria are present it suggests nodal metastasis [19]. Because of lymphatic vessels of the stomach lymph node was involved in 74-88% cases of gastric malignancy [20]. Apart from lymph nodes other site involved in decreasing frequency are liver (40%), peritoneum (30%), lungs (20%), pancreas (17%), retroperitoneum (12%), adrenal gland (10%), ovaries (5%) and diaphragm (5%) [21]. Among all neoplasms of stomach 90% cases are malignant and adenocarcinoma was the most common malignant tumor of stomach (95%) [22]. Histopathology also showed adenocarcinoma as 90-95% from which mucinous type was 1.3% [23]. It was followed by lymphoma (1-5%), GIST (2%), carcinoid (1%), adenocarcinoma (1%), and squamous cell carcinoma. According to Schwartz G *et al.* 90% of all tumors of the stomach are malignant and gastric adenocarcinoma comprises 95% of the total number of malignancies [24].

Limitations

As in this study less number of cases had been observed, future studies should include a large sample size to obtain more precise result. Follow up studies should be conducted to observe the prognosis of the cases.

Conclusion

Recent advances in CT technology with 3D imaging have increased the diagnostic details of gastric cancer. Use of water as an oral contrast agent with a good IV contrast bolus and thin collimation with MDCT makes a remarkable improvement in the diagnosis of gastric neoplasm. Correlation of UGIE biopsy gives complete information regarding the type of tumor, intra as well as the extra gastric spread of the tumor, adjacent structure involvement, lymph node and distance metastasis.

These in formations are very important for the surgeon for planning the best suitable treatment for the patient. However it is insensitive in recognizing microscopic nodal invasion.

References

1. Amila Mehmedovic, Rusmir Mesihovic, Aida Saray, Nenad Vanis. Gastric Cancer Staging. EUS and CT. Med Arch. 2014; 68(1):34-36.

2. Fishman EK, Urban BA, Hruban RH. CT of the stomach: Spectrum of disease. *Radio graphics*, 2003; 23:75-87.
3. Chen CY, Hsu JS, Wu DC, Kang WY, Hsieh JS, Jaw TS *et al.* Gastric cancer: preoperative local staging with 3D multi-detector row CT--correlation with surgical and histopathologic results. *Radiology*. 2007; 242(2):472-82.
4. Angelelli G, Stabile Ianora AA, Scardapane A, Pedote P, Memeo M, Rotondo A *et al.* Role of computerized tomography in the staging of gastrointestinal neoplasm. *Semin Surg Oncol*, 2001; 20:109-121.
5. Kim JH, Eun HW, Goo GE, Shim CS, Auh YH. Imaging of various gastric lesions with 2D MPR and CT gastrography performed with multi detector CT. *Radio graphics*, 2006; 26:1101-16.
6. Horton KM, Fishman EK. Current role of CT in imaging of the stomach. *Radio graphics*, 2003; 23:75-87.
7. D'Elia F, Zingarelli A, Palli D, Grani M. Hydrodynamic CT preoperative staging of gastric cancer: Correlation with pathological findings. A prospective study of 107 cases. *Eur Radiol*, 2000; 10:1877-1885.
8. Moschetta M, Stabile Ianora AA, Anglani A, Marzulla A, Scardapane A, Angelelli G *et al.* Preoperative T staging of gastric carcinoma obtained by MDCT vessel probe reconstructions and correlations with histological findings. *Eur Radiol* 2010; 20:138-145.
9. Yan C, Zhu ZG, Yan M. Size of the largest lymph node visualized on multi detector row computed tomography is useful in predicting metastatic lymph node status of gastric cancer. *J Int Med Res*, 2010; 38:22-33.
10. James Thomas, Sudhakar Venkatesh. Gastric carcinoma: imaging diagnosis, staging and assessment of treatment response. *Cancer Imaging*. 2013; 13(2): 212-227.
11. Jing-Yu Deng, Han Liang. Clinical significance of lymph node metastasis in gastric cancer. *World J Gastroenterol*. 2014; 20(14):3967-3975.
12. Adachi Y, Shiraishi N, Suematsu T. Most important Lymph node information in gastric cancer: Multivariate prognostic study. *Ann Surg Oncol*, 2000; 7:503-507.
13. Akahoshi K, Chijiwa Y, Hamada S. Pretreatment staging of endoscopically early gastric cancer with a 15 MHz ultrasound catheter probe. *Gastrointest Endosc*, 2001; 53:593-598.
14. Faige DO. EUS in patients with benign and malignant lymphadenopathy. *Gastrointest Endosc*, 2001; 53:593-598.
15. Schwartz G. Invasion and metastasis in gastric cancer: In vitro and In vivo models with clinical considerations. *Semin Oncol*, 1996; 23:316-324.
16. Rubin BP. Gastrointestinal stromal tumours: an update. *Histopathology*, 2006; 48:83-96.
17. Kim YN, Choi D, Kim SH. Gastric cancer staging at isotropic MDCT including coronal and sagittal MPR images: endoscopically diagnosed early vs. advanced gastric cancer. *Abdom Imaging*, 2009; 34:26-34.
18. Chiao-Yun Chen, Jui-Sheng Hsu, Deng-Chyang Wu, Wan-Yi Kang, Jan-Sing Hsieh, Twei-Shiun Jaw *et al.* Gastric Cancer: Preoperative Local Staging with 3D Multi-Detector Row CT-Correlation with Surgical and Histopathologic Results. *Radiology*, 2007; 242:2,472-482.
19. Yang Dal Mo, Kim Hyun Cheol, Jin Wook, Ryu Chang Woo, Kang Jee Hee, Park Chul Hi *et al.* 64 Multi detector-Row Computed Tomography for Preoperative Evaluation of Gastric Cancer: Histological Correlation. *Journal of Computer Assisted Tomography*, 2007; 31(1):98-103.
20. Kumano S, Murakami T, Kim TT. Staging of gastric cancer: role of multi-detector row CT. *Radiology*, 2005; 237:961-966.
21. Chen C-Y, Hsu J-S, Wu D-C. Gastric cancer: preoperative local staging with 3D multi-detector row CT--correlation with surgical and histopathologic results. *Radiology*, 2007; 242:472-482.
22. Chamadol N, Wongwiwatchai J, Bhudhisawasd V, Pairojkul C. Accuracy of spiral CT in preoperative staging of gastric carcinoma: correlation with surgical and pathological findings. *J Med Assoc Thai*, 2008; 91:356-363.
23. Saito T, Kurokawa Y, Takiguchi S. Accuracy of multi detector-row CT in diagnosing lymph node metastasis in patients with gastric cancer. *Eur Radiol*, 2015; 25:368.
24. Miettinen M, El-Rifai WHL, Sobin L, Lasota J. Evaluation of malignancy and prognosis of gastrointestinal stromal tumors: a review. *Hum pathol* 2002; 33:478-83.