



ISSN Print: 2394-7500
ISSN Online: 2394-5869
Impact Factor: 5.2
IJAR 2017; 3(6): 299-302
www.allresearchjournal.com
Received: 15-04-2017
Accepted: 16-05-2017

Arvind K Jangid
Orthopaedic Resident,
Department of Orthopaedic
Government Medical College,
Vadodara, India

Vinod Nagar
Orthopaedic Resident Doctor
Department of Orthopaedic
Motilal Nehru Medical College,
Allahabad, Uttar Pradesh,
India

Achilles tendon repair and a modified technique

Arvind K Jangid and Vinod Nagar

Abstract

Background: Wound complications following open repair after acute Achilles tendon ruptures (AATR) remain the subject of significant debate. The aim of this study is to investigate the effects of covering repaired AATR using well-nourished connective tissues (paratenon and deep fascia) to avoid complications after open repair.

Methods: In this case series study, open repair was performed for 15 active young patients with AATR. After the tendon was repaired, the deep fascia and paratenon was used to cover the Achilles tendon. Patients were followed for two years and any wound complication was recorded. During the last visit, the American Orthopedic Foot and Ankle Society (AOFAS) ankle-hind foot score was completed for all patients. Calf circumference and ankle range of motion were measured and compared with the contralateral side. Patients were asked about returning to previous sports activities and limitations with footwear.

Results: None of the patients had any discomfort around the operation area, limitation with footwear, sural nerve injury, re-rupture, and skin adhesion. Only, one patient developed deep wound infection (6.6%). The AOFAS score averaged 92.5±6. Two patients (13%) were unable to return to previous sports activities because of moderate pain in heavy physical exercises. The calf circumference and ankle ROM were similar between healthy and operated sides.

Conclusion: The present study showed that fascial envelope for full covering of the repaired Achilles tendon may help to prevent the occurrence of wound complications.

Keywords: Achilles tendon, open repair, wound complication

Introduction

Acute Achilles tendon rupture (AATR) is one of the most common of tendon injuries, especially among athletes. Nonoperative treatment with splinting (casting) is associated with good results, but due to the lower rate of re-rupture and faster return to previous activities, surgical repair for acute AT rupture is preferred. The consequences of wound complications after Achilles tendon surgery are considerable and challenging. Some authors have introduced percutaneous or minimally invasive repair to decrease the incidence of these complications; however, these techniques are technically demanding, dependent on special instruments and associated with a higher risk of sural nerve injury. In addition, the bulky sutures used in other open techniques may irritate the skin over the tendon and result in the patient's discomfort. With regard to the limitations of minimally invasive techniques and to avoid the complications of open repair and to get the advantages of these techniques, we evaluated the wound outcomes of open AATR repair, through covering the repaired area using a fascial flap by displacing the deep fascia of the posterior compartment of the leg after longitudinal relaxing incision. It was hypothesized that using this new technique improves coverage of repaired tendon and results in decreased wound complications.

Materials and Methods

From February 2015 to March 2017, fifteen repairs were done on 15 patients with acute complete Achilles tendon ruptures using the modified technique. All patients had sustained Achilles tendon rupture during sports activities.

In all cases, AATR was identified by evaluating patients' standard history and conducting physical examinations and were confirmed by MRI findings and sonography findings. Most of the patients had a 4 to 5 days hospital stay.

Correspondence
Arvind K Jangid
Orthopaedic Resident,
Department of Orthopaedic
Government Medical College,
Vadodara, India

Surgical Technique

After using anesthesia, a tourniquet was placed on the thigh in the supine position before turning the patient to the prone position. The surgery began by making a posteromedial skin incision, and then it was extended directly until reaching the paratenon. Intensive care was considered to prevent inducing any damages to the soft-tissue envelope. The fascia and paratenon were kept together. The main goal of this modified technique is to achieve tight closure of the paratenon over the repaired tendon. So, after exposing the tendon, irregular tendon ends were debrided and cleaned, then by retracting two ends of the tendon, deep fascia and loose connective tis-sues (paratenon) surrounding the anterior portion of the Achilles tendon (between the superficial and deep compartments of the leg) were exposed and incised vertically along the micro vasculatures (Figure 1). After repairing the tendon by the Krackow technique (using two separate 5 gauge nonabsorbable nylon or fiber wire sutures), the posterior paratenon, which is relaxed by the anterior relaxing longitudinal incision was approximated and repaired tightly using 2-0 Vicryl absorbable sutures, to cover the repaired portion of the tendon completely (Figure 2). The tourniquet was deflated and adequate hemostasis was performed. The skin was closed using continuous absorbable sutures. After wound dressing, the leg was immobilized with a short leg cast with the ankle in gravity equinus in the prone position. Two weeks after surgery, the short leg cast was removed to inspect the wound. Then the ankle was positioned in neutral flexion to apply a new cast. After six weeks the cast was removed and the rehabilitation pro-gram was started. Weight bearing was allowed as tolerated using a reverse-90-degree ankle stop brace. All patients were examined at 2, 6 and 12 weeks, and at 6, 9, 12 months and at their final post-operative visit and then they were followed for a minimum of two years. In the primary outcome, the occurrence of wound complications such as infection, dehiscence, sterile discharge and ten-don to skin adhesion were evaluated during the follow up. Also, the incidence of deep vein thrombosis, pulmonary embolism and re-rupture were evaluated. In the final visit patients were asked about functional deficit, returning to sports activities, any discomfort around the operation site and limitations with footwear. The ankle range of motion and the calf circumference were measured and compared with the unaffected side. Also, the patients were asked to perform toe rise. The American Orthopedic Foot and Ankle Society (AOFAS) ankle-hind foot score was completed for all patients. The calf circumference and ankle range of motion were compared between the operated and healthy limbs using the paired sample t-test. $P < 0.05$ considered significant.

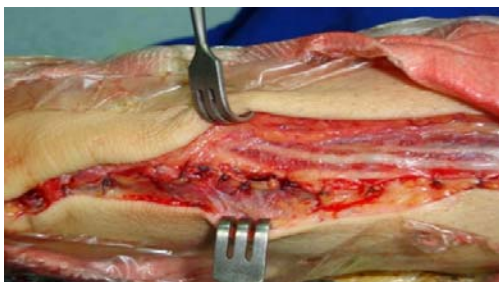


Fig 1: Two ends of tendon were retracted to expose the deep fascia and Paratenon surrounding the anterior portion of Achilles ten-don which incised vertically along the micro-vasculature

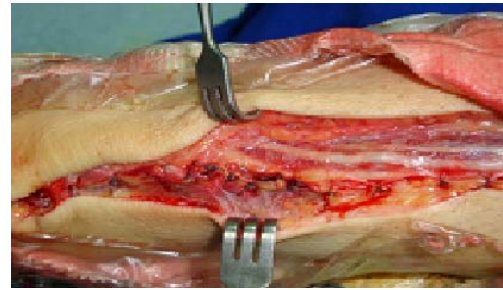


Fig 2: After repairing the tendon by the Krackow technique, the posterior paratenon was approximated and repaired tightly to cover the repaired portion of tendon completely

Table 1: Demographics characteristics of the patients enrolled in current study

NO. variables		
No. patients 15		
Males: Female 12:3		
Mean ages*(yr) 34 (18-46)		
Weight* (kg) 86.14±23.8		
Type of Sporting Activity	Football	6
at injury	Volleyball	3
	Basketball	3
(no. of patients)	tennis	2

Results

One patient (6.6%) developed superficial wound infection due to stitch abscess which showed good response to stitch removal and oral antibiotic therapy. None of the patients had wound dehiscence, sterile discharge, DVT and PE. In the final follow up the AOFAS score was 93 ± 6.3 . None of the patients complained about discomfort around the operation site or limitations with footwear. Twelve patients (80%) had returned to sports by six months, and 13 (86%) returned to sports by 12 months. Unfortunately, two patients did not return to sports. They complained about moderate pain during heavy physical exercises and left competitive sports, but had no limitations in daily living activities. There was no case of re-rupture. In the examination, we found no patient with tendon to skin adhesion. The calf circumference and ankle ROM were similar between the two limbs (Table 2).

Table 2: Comparing the calf circumference and ankle range of motion between operated and healthy sides

	Operated side	Healthy side	P-value
Calf circumference (cm)	38 ± 4.5 (34-42)	38 ± 3.9 (35-43)	> 0.05
Ankle motion (°) Dorsi flexion	15 ± 5 (10-18)	16 ± 4 (10-22)	> 0.05
Ankle motion (°) Plantar flexion	38 ± 6 (21-48)	40 ± 7 (25-48)	> 0.05

Discussion

The most important finding of this study is that the outcomes of AATR repair with the presented technique are favorable. We found only one patient with wound infection which reflects the efficacy of this modification in preventing surgical wound complications. Treatment of acute Achilles tendon ruptures may involve either operative repair (open or percutaneous surgery) or non-operative with supportive devices (cast immobilization or functional bracing). Generally, in athletes and young, active patients, open repair is preferred because it provides

more rapid return to activity and has a high rate of return to sports. With open repair, re-rupture rate is less and better, long-term outcome are achieved. Moreover, nonsurgical treatment is usually recommended for elderly patients, individuals with partial tears and cases with predictable wound complications (e.g, diabetes mellitus patients). Wound complication is an important concern in open AATR repair. It has been shown that poor blood supply and the thin layer of covering integument are the most probable precipitating factors that play a crucial role in increasing the risk of wound complications. The incidence of wound complications after open AATR repair is reported to be 11-21%. Hence, some authors have suggested minimally invasive repair techniques to overcome this problem. Although there is a report indicating the efficacy of minimally invasive techniques in decreasing complications. There are some other studies that are inconsistent with the prior study and they have not found any significant difference between open versus minimally invasive repair. In addition, those studies have reported that the rate of re-rupture is lower in open repair.

Bradley and Tibone compared the open and percutaneous surgical repair of AATR and found two cases with re-rupture in the percutaneous group, while there was no re-rupture in the open group. They recommended percutaneous repair for recreational athletes and for those who are cosmetically concerned and open repair for professional athletes. Cretnik *et al* indicated that there were slightly more, if not significant, re-ruptures and sural nerve injuries in percutaneous repair than open repair.

Based on these findings and our clinical experience with AATR repair, we prefer to use the open technique for professional and young, active athletes. Furthermore, we have looked for a method to avoid wound complications in open repair. Anatomical studies have shown that deep fascia and anterior paratenon, which almost always remain intact in AATR, contain a rich blood supply from the posterior tibial and peroneal arteries. It seems that covering the repaired Achilles tendon with these well-perfused tissues may compensate the inadequate blood supply in this region. In addition to excellent functional outcomes, we found only one patient with wound complication that was comparable with previous reports in minimally invasive technique studies. In 2012, Valente *et al* repaired 35 AATR cases with the help of a minimally invasive technique and found no case with wound complications. Also, Mukundan *et al* treated 21 patients with AATR with a mini-open technique and found one case of superficial infection. In an effort to fully understand the vasculature of Achilles tendon, Yepes *et al* suggested that medial incision can be applied to reduce wound complications and we used the advantages of this approach. Our study did not have a control group, so it was limited by descriptive design.

Conclusion

Our findings show that covering the repaired tendon with well-nourished connective tissues may decrease the rate of wound complications after open AATR repair. The authors suggest that covering the repaired area of Achilles tendon with fascia envelope can be used in all methods of open repair of AT rupture.

References

1. Paavola M, Kannus P, Paakkala T, Pasanen M, Jarvinen M. Long-term prognosis of patients with Achilles tendinopathy. An observational 8-year follow-up study. *Am J Sports Med.* 2000; 28:634-42.
2. Paavola M, Orava S, Leppilahti J, Kannus P, Jarvinen M. Chronic Achilles tendon overuse injury: complications after surgical treatment. An analysis of 432 consecutive patients. *Am J Sports Med.* 2000; 28:77-82.
3. Willits K, Amendola A, Bryant D, Mohtadi NG, Giffin JR, Fowler P, *et al*. Operative versus nonoperative treatment of acute Achilles tendon ruptures: a multicenter randomized trial using accelerated functional rehabilitation. *J Bone Joint Surg Am.* 2010; 92(17):2767-75.
4. Carmont MR, Heaver C, Pradhan A, Mei-Dan O, Gravare Silbernagel K. Surgical repair of the ruptured Achilles tendon: the cost-effectiveness of open versus percutaneous repair. *Knee Surg Sports Traumatol Arthrosc.* 2013; 21(6):1361-8.
5. Chana JS, Chen HC, Jain V. A new incision for surgery on tendoAchillis using a distally-based fascio cutaneous flap. *J Bone Joint Surg Br.* 2002; 84(8):1142-4.
6. Cretnik A, Kosanovic M, Smrkolj V. Percutaneous versus open repair of the ruptured Achilles tendon: a comparative study. *Am J Sports Med.* 2005; 33(9):1369-79.
7. Dalton GP, Wapner KL, Hecht PJ. Complications of Achilles and posterior tibial tendon surgeries. *Clin Orthop Relat Res.* 2001; 391:133-9
8. Ebinesan AD, Sarai BS, Walley GD, Maffulli N. Conservative, open or percutaneous repair for acute rupture of the Achilles tendon. *Disabil Rehabil.* 2008; 30(20-22):1721-5.
9. Jiang N, Wang B, Chen A, Dong F, Yu B. Operative versus nonoperative treatment for acute Achilles tendon rupture: a meta-analysis based on current evidence. *Int Orthop.* 2012; 36(4):765-73.
10. Aibinder WR, Patel A, Arnouk J, El-Gendi H, Korshunov Y, Mitgang J, *et al*. The rate of sural nerve violation using the achillon device: a cadaveric study. *Foot Ankle Int.* 2013; 34(6):870-5.
11. Bradley JP, Tibone JE. Percutaneous and open surgical repairs of Achilles tendon ruptures; a comparative study. *Am J Sports Med.* 1990; 18(2):188-95.
12. Yepes H, Tang M, Geddes C, Glazebrook M, Morris SF, Stanish WD. Digital vascular mapping of the integument about the Achilles tendon. *J Bone Joint Surg Am.* 2010; 92(5):1215-20
13. Mandelbaum BR, Myerson MS, Forster R. Achilles tendon ruptures. A new method of repair, early range of motion, and functional rehabilitation. *Am J Sports Med.* 1995; 23(4):392-5
14. Kitaoka HB, Alexander IJ, Adelaar RS, Nunley JA, Myerson MS, Sanders M. Clinical rating systems for the ankle-hindfoot, midfoot, hallux, and lesser toes. *Foot Ankle Int.* 1994; 15(7):349-53.
15. Bossley CJ. Rupture of the Achilles tendon. *J Bone Joint Surg Am.* 2000; 82:1804.
16. Raisbeck CC. Rupture of the Achilles tendon. *J Bone Joint Surg Am.* 2000; 82:1804-5.
17. Strauss EJ, Ishak C, Jazrawi L, Sherman O, Rosen J. Operative treatment of acute Achilles tendon ruptures: an institutional review of clinical outcomes. *Injury.* 2007; 38(7):832-8.

18. Metz R, Kerkhoffs GM, Verleisdonk EJ, van der Heijden GJ. Acute Achilles tendon rupture: minimally invasive surgery versus non operative treatment, with immediate full weight bearing. Design of a randomized controlled trial BMC Musculoskelet Disord. 2007; 8:108.
19. Valente M, Crucil M, Alecci V, Frezza G. Minimally invasive repair of acute Achilles tendon ruptures with Achillon device. Musculoskelet Surg. 2012; 96(1):35-9.
20. Mukundan C, El Husseiny M, Rayan F, Salim J, Budgen A. Mini-open repair of acute tendo Achilles ruptures-the solution? Foot Ankle Surg, 2010; 16(3):122-5.