



ISSN Print: 2394-7500
ISSN Online: 2394-5869
Impact Factor: 5.2
IJAR 2017; 3(6): 758-763
www.allresearchjournal.com
Received: 18-04-2017
Accepted: 20-05-2017

Pusapati Chiranjeevi Raju
Research Scholar, Department
of Biochemistry, Acharya
Nagarjuna University,
Nagarjuna nagar,
Guntur, Andhra Pradesh,
India

PVV Satyanarayana
Prof. Department of
Chemistry, Acharya Nagarjuna
University, Nagarjuna nagar,
Guntur, Andhra Pradesh,
India

Evaluation of nephroprotective activity of *Capsicum annuum* in rifampicin induced nephrotoxicity

Pusapati Chiranjeevi Raju and PVV Satyanarayana

Abstract

The nephroprotective effect of methanolic extract of *Capsicum annuum* fruits is experimentally evaluated by rat model. In the present study, the methanolic extract of *Capsicum annuum* fruits significantly reduced the toxicant elevated levels of urea uric acid creatinine parameters and increase in the levels of protein in blood and urine, methanolic extract of *Capsicum annuum* fruits is found to reduce such changes in kidney histology induced by Rifampicin, indicating nephroprotection. Further documented reports reveal that, plant material containing phenols, flavonoids, triterpenoids, alkaloids and saponins offers organ protection by virtue of their free radical scavenging activity. Phytochemical analysis showed the presence of phenols, flavonoids, triterpenoids, alkaloids and saponins as phytoconstituents. Hence, the role of these phytoconstituents as free radical scavengers and consequent nephroprotection cannot be ruled out. Based on improvement in serum and urine marker levels, histopathological studies, level of antioxidant enzymes and presence of phytoconstituents, it is concluded that the methanolic extract of *Capsicum annuum* fruits possesses nephroprotective activity and thus supports the traditional application of the same under the light of modern science.

Keywords: *Capsicum annuum*, rifampicin, nephroprotective, nephrotoxicity

Introduction

Kidneys are the organs that serve several essential regulatory roles in most animals, including vertebrates and some invertebrates. They are essential in the urinary system and also serve homeostatic functions such as the regulation of electrolytes, maintenance of acid–base balance, and regulation of blood pressure. They serve the body as a natural filter of the blood, and remove wastes which are diverted to the urinary bladder. In producing urine, the kidneys excrete wastes such as urea and ammonium, and they are also responsible for the reabsorption of water, glucose, and amino acids. The kidneys also produce hormones including calcitriol, erythropoietin, and the enzyme rennin.

Rifampicin is a semi synthetic antibiotic derivative of rifamycin B. The chemical name for rifampin is 3-(4-methyl-1-piperazinyloxy) rifamycin. Rifampicin is not recommended for intermittent therapy. The patient should be cautioned against intentional or accidental interruption of the daily dosage regimen since rare renal hypersensitivity reactions have been reported when therapy was resumed in such cases. Haemolysis, haemoglobinuria, haematuria, renal insufficiency or acute renal failure have been reported which are generally considered to be hypersensitivity reactions.

The human beings are exposed to environmental, occupational and xenobiotics challenges due to modern life style. Free radicals are generated during the exposure to such stressful challenges. In addition the process of metabolism and excretion of xenobiotics may also generate free radicals. These free radicals bind covalently with the tissue macromolecules leading to the cell necrosis^[1-4].

Capsicum annuum

Recently, there is a rising demand for herbal drugs because they have shown beneficial effects in the treatment of variety of disorders such as metabolic syndrome. Some of these plants and their active constituents include *Vitis vinifera*, *Nigella sativa*, *Allium sativum*, *Rosmarinus officinalis*, *Persea americana*, *Berberis vulgaris*, cinnamon, thymoquinone, rutin, *Crocus sativus*, *Garcinia mangostana* and *Camellia sinensis*. Red pepper, with the scientific name of *Capsicum annuum*, belongs to the Solanaceae family.

Correspondence
PVV Satyanarayana
Prof. Department of
Chemistry, Acharya Nagarjuna
University, Nagarjuna nagar,
Guntur, Andhra Pradesh,
India



Capsicum annum

The aim of the research is to find out new Nephroprotective agents from indigenous plants which are potent and non toxic agents. Normally herbal plants are free from side effects/adverse effects and they are low cost medicines, which will be beneficial for the people. Keeping in this view, we have selected *Capsicum annum* based on ethno pharmacology information from Kollu Hills, Namakkal District, Tamil Nadu which is traditionally used in various disorders including kidney diseases by tribes. The present study aimed at evaluates Nephroprotective of *Capsicum annum* against Rifampicin induced nephrotoxicity in rats with special reference to biochemical and histopathological studies [5-8].

Materials and Methods

Materials

Rifampicin was obtained as a gift sample from Microlabs Pvt. Ltd. Bangalore. The kits for all biochemical estimation were purchased from Coreal Clinical Systems, Verna Goa, India. The *Capsicum annum* fruits are collected from local market.

Preparation of extract

500gm of *Capsicum* fruits were obtained and washed. The collected fruits were dried at room temperature, pulverized by a mechanical grinder, sieved through 60 mesh and was Soxhlet with 70% methanol for 48 hours, concentrated to dryness in vacuum and weighed.

Animals

Female wistar rats were procured and they were housed in microloan boxes with standard laboratory diet and water *ad libitum* at temperature of 22 °C±2 °C and humidity of 45%-64%. The study was conducted after obtaining Institutional Animal Ethical Committee Clearance. (IAEC Number).

Nephroprotective Studies

Study Design of *Capsicum annum*

Grouping of Animals

Rats were divided into five groups each group consisting of six animals

Group 1: Normal control: Administered with equivalent volumes of 5ml/kg p.o. of normal saline (0.9%NaCl) for 2 weeks.

Group 2: Positive control: Received Rifampicin (1g/kg/bodyweight p.o.) every 72 hrs for 2 weeks to induce nephrosis.

Group 3: Standard: Received cystone (500mg/kg/bodyweight p.o.) and simultaneously administered after 30 min. Rifampicin (1g/kg/bodyweight p.o.) every 72 hrs for 2 weeks.

Group 4: Methanolic extract of *Capsicum annum* (250mg/kg/body weight p.o.) and simultaneously administered after 30 min. Rifampicin (1g/kg/body weight p.o.) every 72 hrs for 2 weeks.

Group 5: Methanolic extract of *Capsicum annum* (500mg/kg/body weight p.o.) and simultaneously administered after 30 min. Rifampicin (1g/kg/body weight p.o.) every 72 hrs for 2 weeks.

The study was carried out for 2 weeks. On 15th day all the animals were sacrificed under diethyl ether anaesthesia. Blood samples were collected, allowed to clot, serum was separated by centrifuging at 2500 rpm for 15 min. and analysed for various biochemical parameters. Assessment of kidney function

Biochemical parameters i.e., Estimation of urinary and Blood parameters like urea, Creatinine, uric acid and total proteins were analyzed according to the reported photometric methods. The kidney was removed, weighed and morphological changes were observed. A 10% of kidney homogenate was used for antioxidant studies such as lipid peroxidation (LPO), superoxide dismutase (SOD), catalase and glutathione peroxidase (GPx). A portion of kidney was fixed in 10% formalin for histopathological studies.

Histopathological studies

A histopathological study of kidneys was performed in histopathology laboratory by consultant histopathologist.

Statistical analysis

The values were expressed as Mean ± SEM. Statistical analysis was performed by one way analysis of variance (ANOVA) followed by Dunnett's multiple comparison test. P values < 0.05 were considered as significant [9-12].

Results- Urine Values

Table 1. Drug treatment

Group	Drug treatment	Urea (mg/dl)	Uric acid (mg/dl)	Creatinine (mg/dl)
1	5ml/kg NS	29.28±0.58	25.75±0.49	0.14±0.06
2	1g/kg Rifampicin	74.52±0.49	50.23±0.32	1.96±0.31
3	500mg/kg Cystone+1g/kg Rifampicin	30.85±0.50***	34.54±0.34***	0.61±0.21***
4	100mg/kg CAME +1g/kg Rifampicin	36.11±0.32***	38.19±0.33***	0.55±0.03***
5	200mg/kg CAME +1g/kg Rifampicin	34.88±0.51***	27.06±0.36***	0.34±0.04***

Table 2: Serum Values

Group	Drug treatment	Urea (mg/dl)	Uric acid (mg/dl)	Total protein (mg/dl)	Creatinine (mg/dl)
1	5ml/kg NS	39.37±0.44	0.841±0.33	6.603±0.2	0.96±0.03
2	1g/kg Rifampicin	95.23±0.38	1.93±0.05	4.37±0.33	2.29±0.08
3	500mg cystone +1g/kg Rifampicin	30±0.57***	0.95±0.05***	6.16±0.28***	1.47±0.05***
4	100mg/kg CAME + 1g/kg Rifampicin	32.1±0.72***	0.71±0.06***	6.22±0.31***	0.75±0.06***
5	200mg/kg CAME + 1g/kg Rifampicin	29.36±0.75***	0.31±0.53***	7.2±0.19***	0.79±0.01***

All values are expressed as Mean±SEM, N=6 animals in a group. One way analysis of variance (ANOVA) followed by multiple comparison Dunnett's test *** $P<0.001$ as compared to positive control group

Antioxidant parameter Values

Group	Catalase ($\mu\text{mole of H}_2\text{O}_2/\text{Sec/mg protein/ml}$)	Lipid peroxidise (nmol MDA/ min \times mg protein)	Glutathion peroxidise ($\mu\text{ mole of oxidized GSH / min } \times \text{mgprotein}$)	Superoxide dismutase (U/mg protein)
1	15.11±1.328	9.18±0.302	34.01±1.818	18.33±0.519
2	8.16±0.849	19.18±0.251	20.33±1.208	7.32±0.19
3	14.18±1.548***	13.55±0.394***	28.36±0.518***	16.44±0.586***
4	11.35±0.608 ^{NS}	18.28±0.372 ^{NS}	23.28±0.816 ^{NS}	12.33±0.442*
5	13.18±1.316*	14.65±0.721**	26.44±0.863*	14.36±0.18***

All values are expressed as Mean±SEM, N=6 animals in a group. One way analysis of variance (ANOVA) followed by multiple comparison Dunnett's test.

Ns; indicates no significant.

* $P<0.05$, ** $P<0.01$, *** $P<0.001$: Positive control Vs treatment.

Histopathological Studies

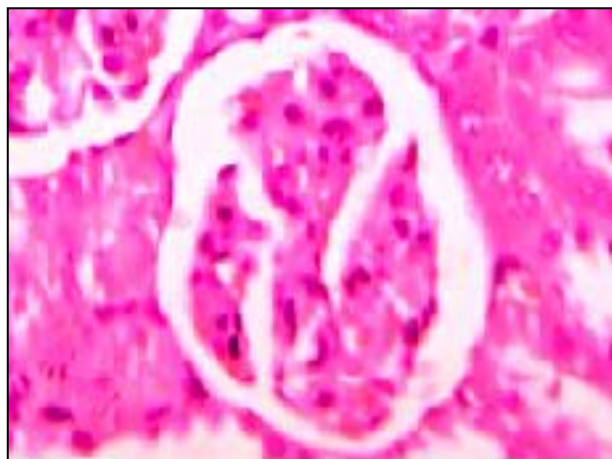


Fig 1.8.a): Group-1

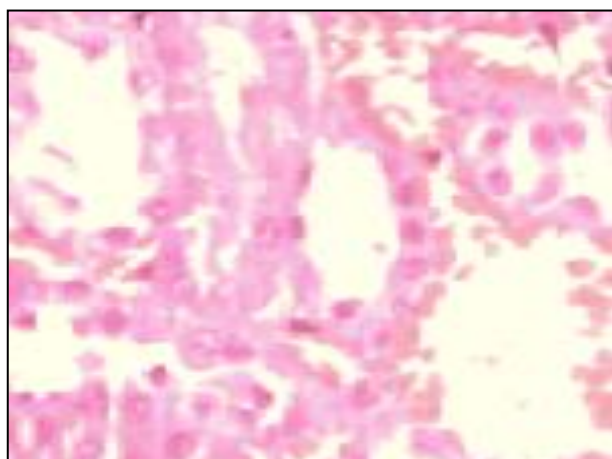


Fig 1.8.b): Group-1

Normal saline - 5ml/kg (p.o) for 2 weeks daily (Group - I)

Microscopy

Section studied shows renal parenchyma with intact normal architecture. The glomerular and tubular changes appear

unremarkable. Some of the blood vessels are dilated and congested (Figure. (b)) within the interstitium. Also few scattered mononuclear inflammatory infiltration is seen within the interstitium.

Significant observation: Some blood vessels show congestion.

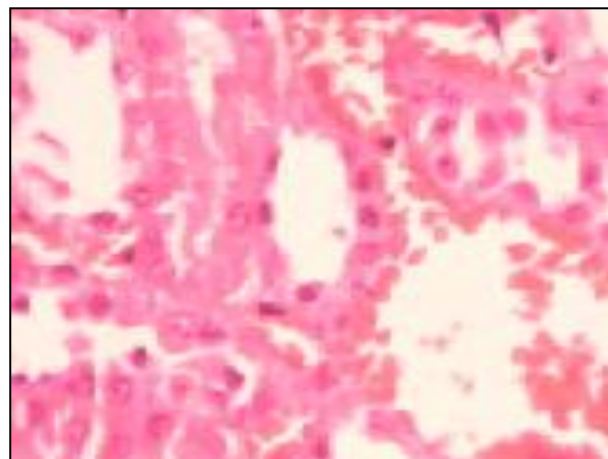


Fig 1.8.c): Group-II

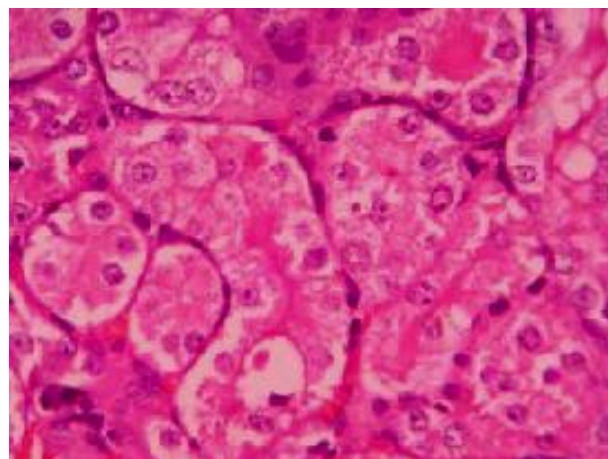


Fig 1.8.d): Group-II

Rifampicin – 1g/kg (p.o) every 72 hrs for 2 weeks (Group – II)

Microscopy

Section studied shows renal parenchyma with intact architecture. There is seen diffuse glomerular congestion (Figure. (c)) occasional tubular casts (Figure. (d)), focal hydropic degeneration of the tubular epithelial cells and peritubular congestion. Some of the tubules show partial desquamation of the epithelial cells. Also seen are blood vessel congestion and scattered mononuclear inflammatory cell infiltrations within the interstitium compared to group-I.

Significant observation: Diffuse glomerular congestion, Tubular casts, Peritubular congestion, epithelial desquamation, Blood vessel congestion.

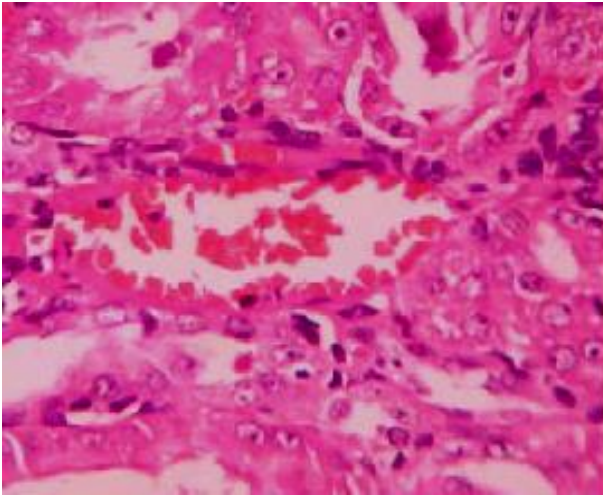


Fig 1.8.e): Group-III

Cystone (500mg/kg) p.o and simultaneously administered after 30 min. Rifampicin (1g/kg) p.o. every 72 hrs for 2 weeks (group-III)

Microscopy:

Section studied shows renal parenchyma with intact architecture. The glomerular and tubular changes appear unremarkable. Some blood vessels are dilated (Figure (e)) within the interstitium compared to group-II.

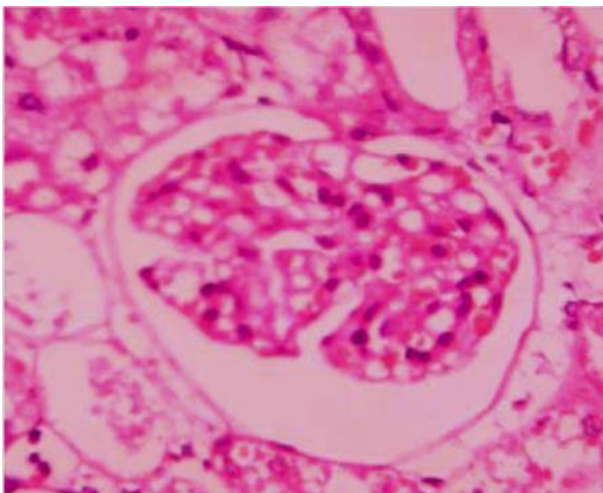


Fig 1.8.f): Group-IV

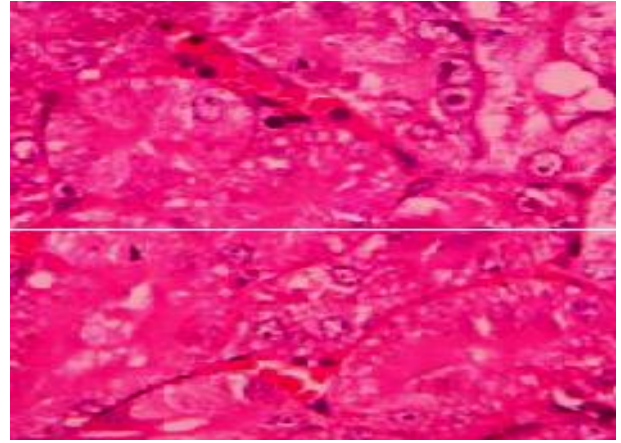


Fig 1.8.g): Group-IV

Methanolic extract of *Capsicum annuum* (250mg/kg/body weight p.o.) and simultaneously administered after 30 min. Rifampicin (1g/kg/body weight p.o.) every 72 hrs for 2 weeks (group – IV).

Microscopy: Section studied shows renal parenchyma with intact architecture. There are seen focal glomerular congestion (Figure. (f)), few the tubular epithelial cells show hydropic degeneration (Figure. (g)) and peritubular congestion. Also seen are few scattered mononuclear inflammatory cell infiltrations within the interstitium.

Significant observation: Focal glomerular congestion, Peritubular congestion, Focal hydropic degeneration of tubular epithelial cells.

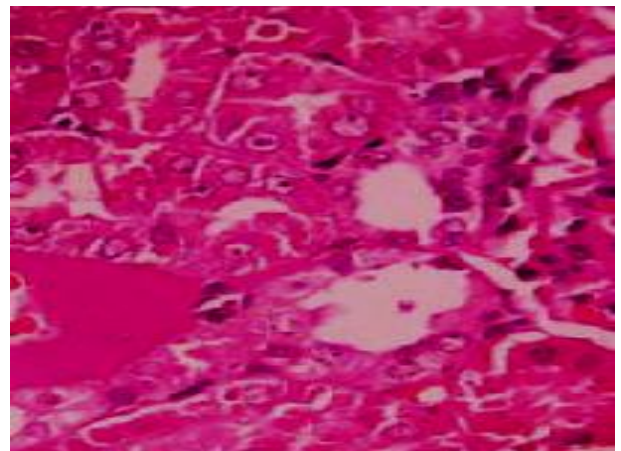


Fig 1.8.h): Group-V

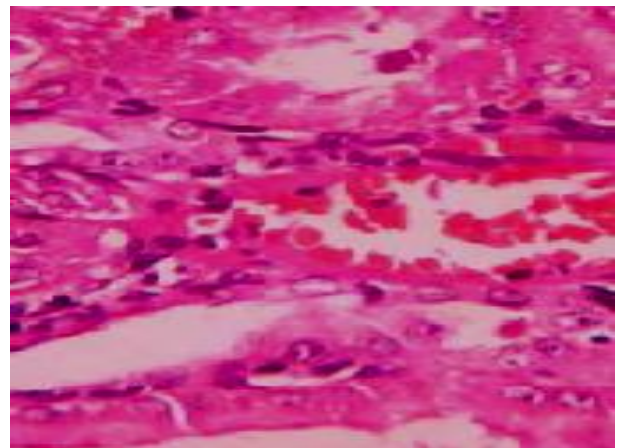


Fig 1.8.i): Group-V

Methanolic extract of *Capsicum annuum* (500mg/kg/body weight p.o.) and simultaneously administered after 30 min. Rifampicin (1g/kg/body weight p.o.) every 72 hrs for 2 weeks (group –V).

Microscopy

Section studied shows renal parenchyma with intact architecture. The glomerular and tubular changes appear unremarkable. Some of the blood vessels are dilated compared to group-IV and congested (Figure. (i)) within the interstitium. Also seen are few scattered mononuclear inflammatory infiltration is seen within the interstitium.

Significant observation: Some blood vessels show congestion.

Discussion

Rifampicin is a potent drug and is the main drug in the multidrug therapy for lung tuberculosis. It can induce hepatitis and nephritis in hypersensitive patient. Thus Rifampicin induced nephrotoxicity is well established experimental model of drug induced renal injury. Many animal experiments have demonstrated overwhelmingly, the positive correlation between oxidative stress and nephrotoxicity. Drug induced nephrotoxicity is often associated with marked elevation of biochemical parameters like urea, creatinine and uric acid in blood and urine and decrease in serum protein levels. So these biochemical parameters have been used to investigate drug induced nephrotoxicity in animal and man. In the present study drug induced nephrotoxicity by administration of Rifampicin. This toxicity characterized by marked elevation in the circulating levels of urea, creatinine and uric acid in blood and urine and decrease in total protein levels and histological features of interstitial nephritis in group 2 rats when compared to untreated (group 1) rats. However these changes were attributed by pre-treatment with oral administration of Methanolic extract of *Capsicum annuum* for 2 weeks. Oral administration of plant extract significantly decreased the urea, uric acid and creatinine where as total protein levels are elevated in both treatment group compare to toxicant group. In renal diseases, the serum urea accumulates because the rate of serum urea production exceeds the rate of clearance. Elevation of urea and creatinine levels in serum was taken as the index of nephrotoxicity. Creatinine derives from endogenous sources by tissue creatinine breakdown. Thus serum urea concentration is often considered a more reliable renal function prediction than serum creatinine. It was established that rifampin-induced Acute tubular interstitial nephritis have demonstrated the occurrence of circulating antirifampin antibodies and immunoglobulin G (IgG) deposits along the tubular basement membrane as well as containing immunoglobulin light chains in tubular lumens. Rifampicin is known to decrease the activities of catalase, glutathione peroxidase and the reduced level of glutathione. Therefore it is no doubt to assume that the nephroprotection showed by Heliotropium ethanolic extract is mediated through its potent antioxidant effect. A relation between oxidative stress and nephrotoxicity has been well demonstrated in many experimental animal models. In Rifampicin treated rats there was a significant increase in lipid peroxidation products (MDA) suggesting that the involvement of oxidative stress. In addition triterpenoids have also been reported to strongly inhibit lipid peroxidation

induced in isolated tissues via its antioxidant activity. The presence of Triterpenoids could be the reason of protection by the extract might be due to its ability to activate antioxidant enzymes. In histopathological study of saline treated group showing some blood vessels are dilated and congested within the interstitium. Also few scattered mononuclear inflammatory infiltration is seen within the interstitium. Rifampicin treated group showing diffuse glomerular congestion, Tubular casts, Peritubular congestion, epithelial desquamation, Blood vessel congestion. While treatment group (100 mg/kg) shows Focal glomerular congestion, Peritubular congestion, Focal hydropic degeneration of tubular epithelial cells and treatment group (200 mg/kg) shows only some of the blood vessels are dilated and congested within the interstitium. Also few scattered mononuclear inflammatory infiltration is seen within the interstitium. From histopathological results Methanolic extract of *Capsicum annuum* at dose of 100 mg/kg have partial protective effect while Methanolic extract of *Capsicum annuum* at dose of 200 mg/kg have protective effect on Rifampicin induced nephrotoxicity. The findings suggest the potential use of Methanolic extract of *Capsicum annuum* a therapeutically useful Nephroprotective agent. Therefore further studies to explain their mechanisms of action should be conducted to aid the discovery of new therapeutic agents for the treatment of renal diseases.

Conclusion

Based on improvement in serum and urine marker levels, histopathological studies, level of antioxidant enzymes and presence of phytoconstituents, it is concluded that the Methanolic extract of *Capsicum annuum* possesses nephroprotective activity and thus supports the traditional application of the same under the light of modern science.

Acknowledgement

I take this privilege and pleasure to acknowledge the contributions of many individuals who have been inspirational and supportive throughout my work undertaken and endowed with the precious knowledge to see success in my endeavour.

References

1. Asscher AW. Interstitial nephritis and urinary tract infections. In: (Eds) Weatherall D J, Ledingham J G G and Warrell D A. Oxford Textbook of Medicine. Oxford. Oxford University Press. 2nd Ed. 1987;18(67-68):112-116.
2. Bababunni *et al.* Nephrotoxicity Principles and methods for assessment of nephrotoxicity associated with exposure to chemicals. WHO 1991, 18-23.
3. Appel GB, Bhat P. Nephrology VIII. Tubulointerstitial diseases. In: ACP Medicine. Dale DC (editor). WebMD, Inc 2006.
4. Bonventre JV. Kidney ischemic preconditioning. *Curr Opin Nephrol Hypertens.* 2002;11(1):43-48.
5. Magied MMA, Salama NAR, Ali MR. Hypoglycemic and Hypocholesterolemia Effects of Intra-gastric Administration of Dried Red Chili Pepper (*Capsicum annuum*) in Alloxan-Induced Diabetic Male Albino Rats Fed with High-Fat-Diet. *J Food Nut Res* 2014;2:850-856.
6. Roghani M, Baluchnejadmojarad T, Sohrabi Z, Sadeghi M. Anti-hyperlycemic and hypolipidemic effect of oral

- administration of *Capsicum frutescens* in male STZ-diabetic rats. *J Med Plants* 2004;2:47-52.
7. Chen L, Kang YH. *In vitro* Inhibitory Potential Against Key Enzymes Relevant for Hyperglycemia and Hypertension of Red Pepper (*Capsicum annuum* L.) Including Pericarp, Placenta, and Stalk. *J Food Biochem* 2014;38:300-306.
 8. Ahuja KD, Robertson IK, Geraghty DP, Ball MJ. Effects of chili consumption on postprandial glucose, insulin, and energy metabolism. *Am J Clin Nutr* 2006;84:63-69.
 9. Dipalma JR, Digregorio GJ. *Basic Pharmacology in Medicine*. 3rd ed. New York: Mc Graw Hill 1990, 627-30.
 10. Farjana K, Md. Amran H, Apurba SA, Stesh CB, Nazmul Q. evaluation of analgesic and antidiarrhoeal property of the ethanolic extract of *Crataeva nurvala* Buch. Ham leaves. *Int J Pharm Sci Rev Res* 2012;12(2):5-8.
 11. Ghana Herbal Pharmacopoeia. Accra. Advent Press 1992, 63-71.
 12. Ghosh J, Myers CE. Inhibition of arachidonate 5-lipoxygenase triggers massive apoptosis in human prostate cancer cells. *Proc Natl Acad Sci* 1998;95:13182-7.