



ISSN Print: 2394-7500
ISSN Online: 2394-5869
Impact Factor: 5.2
IJAR 2018; 4(12): 01-03
www.allresearchjournal.com
Received: 01-10-2018
Accepted: 03-11-2018

Dr. Manish Chaturvedi
Assistant Professor, Dept. of
Anatomy, Gajara Raja Medical
College, Gwalior, Madhya
Pradesh, India

Dr. Preeti Pancholi
M.S. Anatomy, Dept. of
Anatomy, Gajara Raja Medical
College, Gwalior, Madhya
Pradesh, India

Dr. Neeraj Pancholi
PG IIIrd year, Dept. of
Pathology, Gajara Raja
Medical College, Gwalior,
Madhya Pradesh, India

Correspondence
Dr. Preeti Pancholi
M.S. Anatomy, Dept. of
Anatomy, Gajara Raja Medical
College, Gwalior, Madhya
Pradesh, India

A MRI study of variation in termination of spinal dural SAC

Dr. Manish Chaturvedi, Dr. Preeti Pancholi and Dr. Neeraj Pancholi

Abstract

The conus medullaries or "medullary cone" is the terminal end of the spinal cord and it is enclosed in a sac known as the dural sac (DS). After the invention of MRI, scientists found that there is wide range of termination of dural sac. The DS ending is most relevant to many clinical procedure. This is an observational study included MRI images of 71 adult individuals in the age group of 20-65 years of with 38 males & 33 females. MRI of whole spine of patients were performed. The most caudal level of the conus medullaris & dural sac was determined in relation to the adjacent vertebra and disc space with the help of di com works software. In total no of 71 cases Dural sac termination occurs around S1 & S2 vertebral level. Max no of termination occurs at S2- Lower level in 29.58% then 25.35% at S2-middle level. The present study is an attempt to provide data base for a range of termination of spinal dural sac, on MRI. Which is helpful in clinical procedures like lumbar puncture and accurate localization in cranial spinal irradiation & anaesthesiologist practicing regional anaesthesia.

Keywords: Dural sac, MRI, conus medullaris, irradiation

1. Introduction

Confidence in performing a procedure comes from a knowledge of specific regional anatomy. Lumbar puncture is an essential procedure in the armamentarium of clinicians, and its complications may result if carried out without a proper understanding of anatomical implications. The conus medullaries or "medullary cone" is the terminal end of the spinal cord and it is enclosed in a sac known as the dural sac (DS). The DS protects the dangling nerve roots of spinal cord termination and is made up of two distinct but tightly bound layers called the dura mater and arachnoid mater. Before the invention of modern imaging technique scientists studied the termination of spinal cord & dural sac by actually dissecting cadavers and it is widely accepted that the conus medullaris terminates in the lower third of L1 vertebra and that of dural sac at the lower border of S2^[1, 2]. However there were some limitations which made these findings inapplicable to living human beings. Cadaveric dissection is subject to distortion, and measurements may alter after skeletonisation of the cadaver^[3]. There are variations of the level of the thecal sac ending i.e. it may extend caudally than the S2 level^[4, 5]. After the invention of MRI, scientists found that there is wide range of termination of dural sac. Advantages of MRI are it identifies possible disorders and provide wide range in live healthy subjects^[6]. The DS ending is most relevant to clinical practice such as craniospinal irradiation, epidural and spinal anaesthesia & lumbar puncture^[6]. This study will be beneficial for clinicians doing clinical procedures like lumbar puncture and accurate localization in cranial spinal irradiation & anaesthesiologist practicing regional anaesthesia for understanding the exact nernoaxial anatomy and avoiding neurological complication.

2. Material and methods

This is an observational study in which included 71 adult individuals in the age group of 20-65 years with 38 males & 33 females, who attended the Vidya Health Imaging, Gwalior for spinal MRI Scan. Patients with intervertebral disc diseases and abnormalities of vertebral column like kyphoscoliosis. Patients, tumors or leptomenigeal seeding, history of previous spine surgery, congenital spinal anomalies like spinabifida are excluded from study. MRI of whole spine of patients were performed on Siemens essenza 1.5 Telsa supercan 16 channel machine. All measurements were performed with the help of dicom works software.

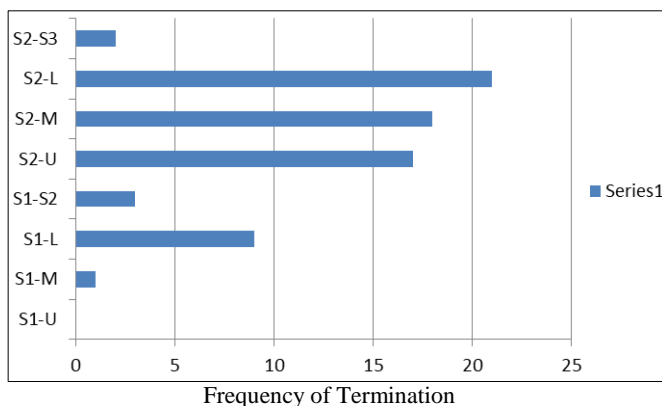
Each patient's age, sex, race and location of the lower limit of the DS were recorded. The most caudal level of the dural sac was determined in relation to the adjacent vertebra and disc space. In accordance with the method of Saifuddin *et al.* [7] each vertebra was divided into 3 equal portions (upper, middle and lower thirds respectively) and the intervertebral disc was defined as a separate region. The position of dural sac termination was defined as the vertebral segment or intervertebral disc space that will be determined by the line.

3. Result and observation

Table 1: Dural sac termination among study group

Dural Sac Termination	Frequency	%
S1-Upper		
S1-Middel	1	1.40
S1-Lower	9	12.68
S1-S2	3	4.22
S2-Upper	17	23.94
S2-Middle	18	25.35
S2-Lower	21	29.58
S2-S3	2	2.82
Total	71	99.99%

In total no of 71 cases Dural sac termination occurs around S1 & S2 vertebral level. Max no of termination occurs at S2- Lower level in 29.58% then 25.35% at S2-middle level. In 33 females dural termination max no of termination found at S2 level. In which 30.3% found at S2 lower level, 27.2% on S2 middle level & 24.2% on S2 upper level. In 38 male 28.9% of dural termination found on S2 lower level, 23.68 on S2 middle & S2 upper. 15.79% of dural end found on S1 lower level.



Graph 1: Dural sac termination among study group

4. Discussion

In total no of 71 cases Dural sac termination occurs around S1 & S2 vertebral level. Max no of termination occurs at S2- Lower level in 29.58% then 25.35% at S2-middle level. In 33 females dural termination max no of termination found at S2 level. In which 30.3% found at S2 lower level, 27.2% on S2 middle level & 24.2% on S2 upper level. In 38 male 28.9% of dural termination found on S2 lower level, 23.68 on S2 middle & S2 upper. 15.79% of dural end found on S1 lower level. Larsen *et al.* [8] performed a radio-anatomical study of the DS. They reported that the tip of the DS ended at the S1-S2 intervertebral disc space in the majority of cases, and further described a range of DS tip endings extending from the L5-S1 to S4-S5 intervertebral disc spaces. Dunbar *et al.* 1993 [9] in a Magnetic Resonance

Imaging studies demonstrated significant variation in the terminal location of the caudal sac, ranging from S2 to S4. The most frequent termination was at S2 (12/24). In four patients (4/24), termination was at mid S1 and in eight others (8/24), it was found to be at or below S3. Crighton *et al.* [10] in 1997 found a mean termination level of the DS at the middle third. Scharf *et al.* [11] 1998 reported similar findings, with 8.7% of patients having a DS lower than the S2-S3 junction. 17.4% of patients had a DS termination at mid-S1. Macdonald *et al.* 1999 [12] found minor gender differences in the level of DS termination, with the level ranging from the upper third of S1 to the upper third of S4. Hansasuta A *et al.* [4] in 1999 [10] dissected 27 cadavers The majority of dural sacs ended at S (2) with a range from S(1) to S(3). Binokay *et al.* [13] in 2006 done magnetic resonance imaging (MRI) studies of 743 patients were assessed to identify the tip of the DS. They demonstrated that the end of the DS was usually located at the upper one-third of S2 (25.2%). The mean level in females was also the upper one-third of S2 (26.5%) and in males the lower one-third of S2 (24.1%). The overall mean DS position was mostly at the upper one-third of S2. No significant differences in DS position were seen between male and female patients or with increasing age. The distribution of DS location in a large adult population was shown to range from the L5-S1 intervertebral disk to the upper third of S3 vertebrae. Nazmy *et al.* [14] who determined that the inferior border of the DS was lower than the inferior border of S2 in 31% of patients. A Cilliers *et al.* [15] 2010 retrospectively reviewed the lumbosacral MR imaging of 309 patients, The overall mean of the DS position was at the middle third of S2. Although the caudal DS tip was at the level of S2 in the majority of patients, a notable percentage (13.9%) had a DS tip level lower than the lower third of S2, and 15.2% had levels higher than the S1-S2 intervertebral disc.

5. Conclusion

Spinal dural sac terminate around S1 & S2 vertebral level. Maximum number of termination occurs at S2 Lower level variations are in present in dural sac length. The results are compared to the previous studies some variations are present in results which are probably due to many factors like different Ethnic & Racial groups, Genetic factors; Environmental conditions; & different age & sex groups. The present study is an attempt to provide data base for a range of termination of spinal dural sac, in Indian population on MRI. Which is helpful in clinical procedures like lumbar puncture and accurate localization in cranial spinal irradiation & anaesthesiologist practicing regional anaesthesia.

6. References

1. Boonpirak N, Apinhasmit W. Length and caudal level of termination of spinal cord in thai adults. *Acta Anat.* 1994; 149:74-8.
2. Demiryurek D, Aydingoz U, Asit MD *et al.* MR imaging determination of the normal level of conus medullaris. *J Clin Imaging.* 2002; 226:375-7.
3. Lanier VS, McKnight HE, Trotter M. Caudal analgesia: an experimental and anatomical study. *Am J Obstet Gynecol.* 1944; 47:633-641.
4. Hansasuta A, Tubbs RS, Oakes WJ. Filum terminal fusion and dural sac termination: study in 27 cadavers. *Pediatr Neurosurg.* 1999; 30:176-9.

5. Crighton IM, Barry BP, Hobbs GJ. A study of the anatomy of the caudal space using magnetic resonance imaging. *Br J Anaesth.* 1997; 78:391-395.
6. Ruggieri PM. A practical approach to magnetic resonance physics in spinal imaging. In: Modic MT, Masaryk TJ, eds. *Magnetic Resonance of the Spine.* 2nd ed. Philadelphia: Mosby, 1994, 1-35.
7. Saifuddin A, Burnett SJ, White J. The variation of position of the conus medullaris in an adult population. A magnetic resonance imaging study. *Spine (Phila Pa 1976).* 1998; 1; 23(13):1452-6.
8. Larsen JL, Olsen KO. Radiographic anatomy of the distal dural sac. A myelographic investigation of dimensions and termination. *Acta Radiol.* 1991; 32:214-219.
9. Dunbar SF, Barnes PD, Tarbell NJ. Radiologic determination of the caudal border of the spinal field in cranial spinal irradiation. *Int J Radiat Oncol Biol Phys.* 1993; 26:669-673.
10. Crighton IM, Barry BP, Hobbs GJ. A study of the anatomy of the caudal space using magnetic resonance imaging. *Br J Anaesth.* 1997; 78:391-395.
11. Scharf CB, Paulino AC, Goldberg KN. Determination of the inferior border of the the cal sac using magnetic resonance imaging: implications on radiation therapy treatment planning. *Int J Radiat Oncol Biol Phys.* 1998; 41:621-624.
12. McDonald A, Chatrath P. level of termination of spinal cord and the dural sac: A MRI study. *Clin Anat.* 1999; 12:149-52.
13. Binokay F, Akgul E, Bicakci K, Soyupak S, Aksungur E, Sertdemir Y. Determining the level of the dural sac tip: magnetic resonance imaging in an adult population. *Acta Radiol.* 2006; 47:397-400.
14. Nazmy MS, Attalla EM, Refeat A. Effect of magnetic resonance myelography on the target volume in craniospinal irradiation in children. *Clin Oncol.* 2009; 21:14-18.
15. Cilliers A, Schulenburg DH, Janse van Rensburg J. MRI determination of the vertebral termination of the dural sac tip in a South African population: clinical significance during spinal irradiation and caudal anaesthesia *SA Journal of Radiology.* 2010, 52-55.