



ISSN Print: 2394-7500
ISSN Online: 2394-5869
Impact Factor: 5.2
IJAR 2018; 4(12): 342-345
www.allresearchjournal.com
Received: 12-10-2018
Accepted: 15-11-2018

Dr. Rajesh Baghel
Associate Professor,
Department of Radiodiagnosis
GRMC, Gwalior, Madhya
Pradesh, India

Dr. Dinesh Sahu
Senior Resident, Department
of Radiodiagnosis, GRMC,
Gwalior, Madhya Pradesh,
India

Dr. Ruchi Vaish
Senior Resident, Department
of Radiodiagnosis, GRMC,
Gwalior, Madhya Pradesh,
India

Dr. Amit Jain
PG Resident, Department of
Radiodiagnosis, GRMC,
Gwalior, Madhya Pradesh,
India

Correspondence
Dr. Ruchi Vaish
Senior Resident, Department
of Radiodiagnosis, GRMC,
Gwalior, Madhya Pradesh,
India

Role of cyanoacrylate glue and its efficacy in the treatment of varicose vein

Dr. Rajesh Baghel, Dr. Dinesh Sahu, Dr. Ruchi Vaish and Dr. Amit Jain

Abstract

To evaluate the role of cyanoacrylate glue therapy and its efficacy and technical feasibility in the management of primary varicose vein due to great saphenous vein incompetency with or without incompetent perforators. This is a prospective study done in 30 patients who presented with varicose veins due to great saphenous vein reflux with or without incompetent perforators and with or without venous ulcer. All patients were subjected to cyanoacrylate glue therapy in great saphenous vein followed by foam sclerotherapy for any incompetent were done at months 1, 3, 6 and 12. The study's Primary end point was closure of the target vein at 12 month as assessed by duplex ultrasound. Technical success rate of procedure was 100%. Of all the 30 patients Saphenous vein closure rate was 96.6% at one year. There was no femoral venous extension of cyanoacrylate in any of the patients. Significant improvement was found in reduction in pain and in diameter and tortuosity of saphenous vein. Ulcer healing rate was 100%. Symptoms and quality of life improved in all the patients. There was no significant adverse effects noted during the procedure and in follow up. In patients with incompetent GSV, treatment with cyanoacrylate glue therapy results in high occlusion rates. Cyanoacrylate adhesive embolization and sclerotherapy is safe, easy, cost effective, minimally invasive, non surgical out-patient procedure for the treatment of primary varicose veins with 100% patient acceptance and very less morbidity compared to surgery.

Keywords: Ultrasonographic, fatty liver, cyanoacrylate glue therapy, technical feasibility

Introduction

Varicose veins are veins that have become enlarged and twisted. When veins become varicose, the leaflets of the valves no longer meet properly, and the valves do not work (Valvular incompetence). This allows blood to flow backwards and they enlarge even more. Varicose veins are most common in the superficial veins of the legs, which are subject to high pressure when standing. Besides being a cosmetic problem, varicose veins can be painful, especially when standing. Severe long-standing varicose veins can lead to leg swelling, venous eczema, skin thickening (lipodermatosclerosis) and ulceration. Although life-threatening complications are uncommon, varicose veins may be confused with deep vein thrombosis, which may be life-threatening [1].

The traditional surgical treatment has been vein stripping to remove the affected veins. Newer, less invasive treatments which seal the main leaking vein are available. Alternative techniques, such as ultrasound-guided foam sclerotherapy, radiofrequency ablation and endovenous laser treatment, are available as well. Because most of the blood in the legs is returned by the deep veins, the superficial veins, which return only about 10% of the total blood of the legs, can usually be removed or ablated without serious harm [2, 3].

In the present Cyanoacrylate Adhesive Embolization and Sclerotherapy (CAES) study, we explore the feasibility and efficacy of an inexpensive treatment combining adhesive embolization of GSV and perforators with the commonly available n-butyl cyanoacrylate glue (which is used as topical skin adhesive or for endovascular embolization Of arteriovenous malformations and vascular tumors 28, 29) and sclerotherapy for the treatment of primary varicose veins.

Aims and Objective

To evaluate the role of cyanoacrylate glue therapy and its efficacy in the management of primary varicose vein due to great saphenous vein incompetency with or without incompetent perforators and with or without venous ulcer.

Material and Methods

This prospective study was conducted as collaboration between the department of Radio diagnosis and department of Surgery. The study period was from July 2018 till March 2018. Consecutive patients who had presented to the Surgery department with complaints of dilated and tortuous saphenous veins with or without venous ulcer.

Inclusion criteria

1. Males and non-pregnant females of any age over 18 years.
2. Primary varicose veins due to great saphenous vein reflux with or without perforator reflux.
3. Good mental health to understand and consent for the procedure with investigative nature.
4. Patients willing for follow-up.

Exclusion criteria

1. Great saphenous vein diameter more than 8 mm.
2. Recurrent varicose veins.
3. Present or previous DVT.
4. Lower limb arterial disease.
5. Hypercoagulable status.

All patients who were referred to our Radiology department with symptoms of lower limb primary superficial venous insufficiency were subjected to physical examination and a thorough Doppler study to map the sources of reflux in pathological veins. Patients satisfying inclusion and exclusion criteria were considered for the study.

Procedure

These patients underwent routine colour duplex ultrasound using ALOKA Pro sound ALPHA-6, linear array probe with frequency 10 MHz to confirm the venous insufficiency and to know the extent of the venous disease. The procedure was explained to the patient in their own languages and their consent for participating in the study was taken. Procedures was performed in supine position with maintaining proper aseptic precautions. Cyanoacrylate adhesive embolization of GSV in the thigh and leg was performed followed by foam sclerotherapy of any incompetent perforators in the legs whenever required. The principle of adhesive embolization was to inject cyanoacrylate glue into dilated saphenous vein or perforators followed immediately by external compression to cause collapse and obliteration of the vessel lumen, with special attention to prevent any spread of glue into the deep veins. (BERRY). The glue used in our study was a very low-viscosity, rapidly polymerizing fluid N butyl cyanoacrylate glue (RECKSEAL TM).

Under USG guidance a 20G, venflow needle was percutaneously placed within the dilated GSV in the lower thigh and leg having the straight course for ease of puncture after applying the tourniquet at saphenofemoral junction, the intravascular position of the needle was confirmed by movement of the needle within the vein. The dextrose-containing syringe was exchanged quickly for a 1-ml syringe loaded with 0.5 ml of cyanoacrylate glue (Reckseal

or Endocryl, Samarth Pharma Pvt. Ltd) and 0.15 ml of air (0.10 ml of air is taken to fill the intraluminal dead space of the venflow needle and push the full dose of cyanoacrylate glue into the cannulated vein when injected). The glue was injected using a fairly quick and continuous push of the plunger as the needle was withdrawn and firm immediate external compression was applied for 30 s. This resulted in intravenous spread of the glue, and collapse – adhesive occlusion of the vein. Deposited glue in the vein appeared echogenic and if dense, cast a post-acoustic shadow. Short unoccluded segments between treated segments were not treated unless there was an associated visible perforator in ultrasound entering the segment. After occlusive embolization of GSV in the thigh, perforators were treated if they were found to be incompetent – defined as reflux time of more than 0.35 s and diameter of more than 3mm at the deep fascial level. Perforators smaller than 3mm showing long reflux times were also treated, if they were located close to a venous ulcer, or communicate directly with symptomatic dilated superficial veins. For dilated and tortuous vein and incompetent perforators in legs, foam sclerotherapy was done using Fagan's method [4] of foam sclerotherapy. The Tessari micro bubble method of UGFS sclerotherapy was used [5]. Polidocanol was the detergent sclerosant used in the procedure (pharmaceuticals – injection asklero 3% / 2ml, manufacturer Samarth pharma private limited. Price-Rs 85/-). The detergent sclerosant (Polidocanol) was mixed with room air to form the foam. This was done using the three way tap switch and two 10 ml disposal syringes. A 3:1 ml room air to sclerosant ratio was mixed with approximately 18-20 rapid exchanges which causes the turbulent flow via three way tap switch to produce micro bubble foam (Tessari micro bubble method). Typical ratios described of air to sclerosant are 3:1 to 5:1 [6]. The foam was stable for 1-2 minutes and remixing was done if reduced to froth. The maximum dose of detergent sclerosant, polidocanol that can be used per session is 12 mL of 1% (4ml of 3%) [7].

After the procedure, roller bandage was applied firmly from groin to foot and the patients were mobilized. Patients were instructed to applied the bandage for three -four weeks. If the bandage get loosened then reapplied it firmly again. Patients had given ecosprine and clopidogrel prophylactically. Any pain in the postoperative period was managed with oral analgesics and cold fomentation.

Follow-up

The patients were asked to revisit us at 1, 3, 6, 9 and 12 months. Clinical assessment, and ultrasound were performed on patients during follow-up.

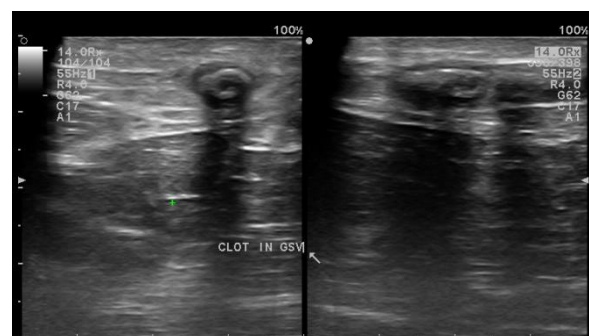


Fig 1: USG image showing thrombosed GSV with echogenic glue within its lumen.

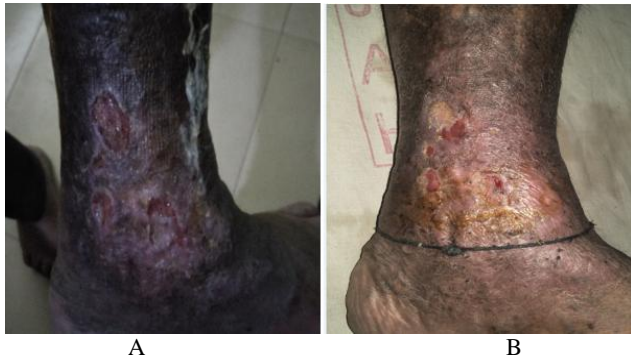

Fig 2: a showing venous ulcer over medial malleolus. Fig. 2b showing significant healing and reduction in size of ulcer on 2month follow up after the glue injection for varicose vein.

Observation & Results

Table 1: Gender distribution of patients

S. NO	Gender	No. of Patients
1	Male	28
2	Female	02

Table 2: Sign and symptoms of patients

S. No	Sign & Symptoms	No. of patients	Percentage
1.	Pain	22	73.3
2.	Limb edema	12	40
3.	Itching	14	46.6
4.	Ulceration	8	26.6
5.	Dilated tortous veins	15	50
6.	Skin discolouration	13	43.3
7.	Skin thickening	15	50

Table 3: Finding on usg Doppler

S. No.	Findings	NO. of Patients
1.	Incompetent SFJ	18
2.	Incompetent SPJ	8
3.	Incompetent Perforators	9

Table 4: Glue + Foam Sclerotherapy

Treatment Option	Only Glue therapy	Glue + Foam Sclerotherapy
NO. of Patients	18	12

Table 5: Outcome of study

S. No	Result	No. of Patients	Percentage
1	Success	29	96.6
2	Failure	01	3.3

Table 6: No. of Session required

S. No.	No. of Session	No. of Patients
1	1	21
2	2	9

Total 30 patients were included in the study with 28 male and 2 female. Most of the patients were presented with complaints of leg pain (73.3%) with itching, skin discolouration and skin thickening as other complaints. Venous ulceration was found in 8 patients (26.6%). On Doppler findings incompetent SFJ SPJ and incompetent perforators was found in 18,8 and 9 patients respectively. Glue therapy was performed in 18 and combined glue +foam sclerotherapy was performed in 12 patients for

Incompetent SFJ with incompetent perforators. successful outcomes was found in 29 patients with presence of echogenic glue within the vessels at 12month follow up. Failure was found in 1 patient probably patient was on antiplatelet therapy for cardiac pathology. No serious complication was found in successive follow up apart from minor pain at the injection site which was managed with nonsteroidal anti- inflammatory medicines.

Discussion

Various surgical ie vein stripping to remove the affected veins and non surgical treatment options such as ultrasound-guided foam sclerotherapy, radiofrequency ablation and endovenous laser treatment, The intravascular use of NBCA also known as superglue has a history of >20 years in arteriovenous malformations and venous applications in other parts of the body. Various Study results have revealed that on contact with intravascular tissue, NBCA rapidly undergoes a polymerization reaction and begins to solidify on coming in contact with the anions of the blood [8, 9]. This polymerization creates an acute inflammatory effect over the vein wall which progresses to granulomatous inflammation; simultaneous gradual resorption of the polymer takes place, resulting in the transformation of a patent vein to an occluded fibrotic cord [9, 10].

The glue used in this study is low viscosity liquid with quick polymerization quality hence the injected venflow withdrawl- external compression had to be fairly quick. Since the glue polymerize very quickly in coming in contact with the blood, the deliver of the glue could not be done with the catheter as the risk of catheter lumen blockage. For the same reason cyanoacrylate glue was injected segmentally at multiple sites directly using the disposable venflow (18G) within the vein percutaneously.

Because of the low viscosity and unpredictability of extent of spread of glue, to prevent the catastrophic complication on DVT, tight tourniquet was used at SFJ and site of injecting the glue should be atleast 8cm from the SFJ. The clinical and ultrasonographic findings during follow-up in our patients correlate with the pathology of cyanoacrylate embolization where veins with deposited palpably hard cyanoacrylate within them cause a transient thrombophlebitic reaction (corresponding to acute inflammatory response) and gradually reduce to a slightly firm fibrotic cord (corresponding to gradual resorption of cyanoacrylate and scarring).

Results from this study confirm that CAE is safe and highly effective for the treatment of CVD. The study showed that occlusion of the target vein at 3 months was high and 12 month occlusion rate in our study found to be 96.5% and similar to that observed in a prior single-arm CAE study (95% in a small Europea study (96%) feasibility study [11] and in a prospective CAE multicenter [12]. No serious procedural and post procedure adverse effects were noted. Although some cases of phlebitis of the treated GSV had occurred, were mild, transient, and successfully treated with the over counter nonsteroidal anti-inflammatory medications. Prophylactically antibiotics were given to prevent any infection post procedural.

Primary advantage of this treatment was low cost and easily availability of cyanoacrylate glue required for CAES. Other advantages of CAES include outpatient nature of the procedure, no requirement of tumescent anaesthesia or immobilization, efficiency comparable to multiple published

studies using proprietary cyanoacrylate, clinical improvement in all patients, very good ulcer healing rate and low complication rate. The primary disadvantage is the unpredictability of the length of glue extension and a possibility of catastrophic occlusion of common femoral vein (although not seen in any patient in our study), because of which it should be performed by interventionists with good prior experience with usage of cyanoacrylate glue. A minor disadvantage of this procedure is that it requires multiple skin punctures compared to single puncture required to treat the whole length of saphenous vein when proprietary cyanoacrylate glue (Saphen venaseal or Variclose) is used.

Conclusion

CAES is a minimally invasive alternative treatment option for the treatment of primary varicose veins. In current study, CAES was found to be efficacious, feasible, easily affordable, cost effective treatment option especially for poor patients which can be performed in an outpatient basis. Result of study was found to be comparable with the various other treatment options.

References

1. Żyłaki – Przewlekła Niewydolność żylna: Zakrzepica – Medycyna Praktyczna: Lekarze pacjentom. Zakrzepica. Retrieved, 2013.
2. Jump up^ Merck Manual Home Edition, 2nd ed. Merck.com. Retrieved, 2013.
3. Jump up^ Varicose veins. In Health Encyclopaedia. nhsdirect.nhs.uk
4. Fegan WG. Injection with compression as a treatment for varicose veins. Proc. R Soc. Med. 1965; 58:874-6.
5. Tessari L. Nouvelle technique d'obtention de la scleromousse. Phlebologie. 2000; 26:705-6.
6. Wollmann JC. The history of Sclerosing foams. Dermatol Surg. 2004; 30:694-703.
7. Perspectives in Vascular Surgery and Endovascular Therapy. 2007; 317-324.
8. Charles L Dietzek, FACOS DO, Rasmussen L, Lawaetz M, Bjoern L, Blemings A *et al.* Randomized clinical trial comparing endovenous laser ablation and stripping of the great saphenous vein with clinical and duplex outcome after 5 years. J Vasc Surg. 2013; 58:421-6.
9. Almeida JJ, Min RJ, Raabe R, McLean DJ, Madsen M. Cyanoacrylate adhesive for the closure of truncal veins: 60-day swine model results. Vasc Endovascular Surg. 2011; 45:631-5.
10. Levrier O, Mekkaoui C, Rolland PH *et al.* Efficacy and low vascular toxicity of embolization with radical versus anionic polymerization of N-butyl-2-cyanoacrylate (NBCA). An experimental study in the swine. J Neuroradiol. 2003; 30:95-102.
11. Almeida JJ, Javier JJ, Mackay EG, Bautista C, Cher DJ, Proebstle TM. Two-year follow-up of first human use of cyanoacrylate adhesive for treatment of saphenous vein incompetence. Phlebology, 2014. [Epub ahead of print].
12. Proebstle TM, Alm J, Dimitri S, Rasmussen L, Whiteley M, Lawson J *et al.* Twelve-month follow-up of the European multicenter study on cyanoacrylate embolization of incompetent great saphenous veins[Abstract]. J Vasc Surg: Venous and Lym Dis. 2014; 2:105-6.