



ISSN Print: 2394-7500
ISSN Online: 2394-5869
Impact Factor: 5.2
IJAR 2018; 4(6): 182-184
www.allresearchjournal.com
Received: 17-04-2018
Accepted: 26-05-2018

Dr. Jay Prakash Yadav
Dept. of Anatomy, Govt.
Medical College, Churu,
Rajasthan, India

Dr. Saurabh Sharma
PhD. Research Scholar,
Dept. of Human Anatomy
Peoples Medical College and
Research Center, Bhopal,
Madhya Pradesh, India

Study of variations of right coronary artery: Cadaveric study

Dr. Jay Prakash Yadav and Dr. Saurabh Sharma

Abstract

Introduction: The aim of the study was to identify right coronary artery branching pattern and its variations. This may indirectly affect the patient's prognosis. This study describes the presence of normal arterial pattern and variations of right coronary artery in fifty heart specimens.

Materials and Method: This study was carried out on 25 formalin fixed adult human cadaveric heart specimens of both sexes. Visceral pericardium and subepicardial fats were removed. The right coronary artery and its branches were carefully dissected and followed till their termination.

Results: The right coronary artery was found to be arising from pulmonary trunk in three heart specimens in our study. Third coronary artery was found in one specimen. Sinu atrial nodal artery was arising from right coronary from right coronary artery in 94% and from left coronary artery in 6% Right dominance was observed in 18(70%) specimens. Fistula between right coronary artery and pulmonary artery was found in one specimen.

Conclusion: Branching pattern of right coronary artery is important for interpretation of coronary angiography and surgical revascularization of myocardium.

Keywords: Fistula, ventricle, pulmonary artery, Coronary artery, cardio – thoracic

Introduction

The myocardium supply by the Coronary arteries. These artery divide in to two right and left coronary arteries arise from ascending aorta. Right coronary artery arises from right anterior aortic sinus and left coronary artery arises from left posterior aortic sinus. The left coronary artery is responsible for irrigation, not only of most of the left ventricle, but also considerable portion of right ventricle ^[1].

Right coronary artery runs between pulmonary trunk and right auricle and then runs downwards and is divided into two segments. First segment runs along the right border of the heart up to inferior border of heart. It gives right conus artery and supplies infundibulum of the right ventricle. If the right conus artery arises separately from the aortic sinus, then it is called as Third coronary artery. The second segment runs up to the apex as right marginal artery and supplies right ventricle. Sometimes it may runs in the posterior interventricular groove and may give rise to Posterior interventricular branch. Hence according to the origin of posterior interventricular artery, the coronary artery dominance has been considered. Right coronary artery ends in the crux by anastomosing with circumflex artery. It supplies the right atrium, right ventricle, atrioventricular septum and part of left ventricle ^[2].

Materials and Method

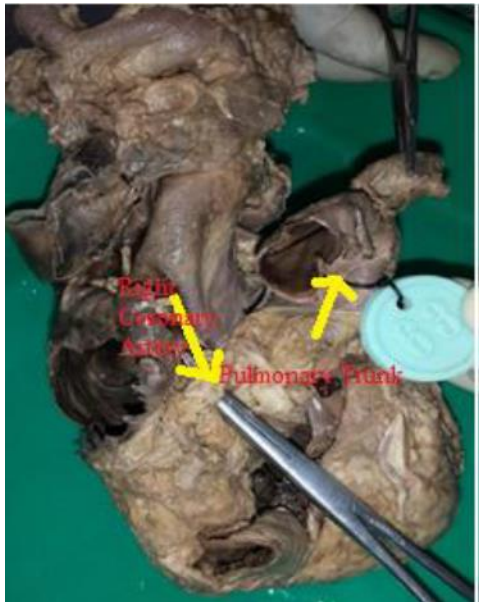
These coronary artery study on 25 heart specimens of both sexes (male and female) in Anatomy department, Govt. medical college and hospital, Churu (Raj). The carefully dissected the right coronary artery and its branches. And study on the normal and abnormal patterns of coronary arteries and its braches.

Result

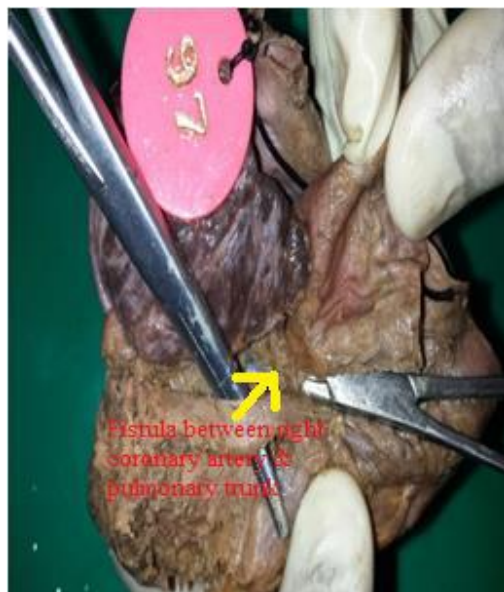Right coronary artery was found to be arising from right anterior aortic sinus in 22 specimens of the heart. Right coronary artery was arising from Pulmonary trunk in 3 heart specimens. Fistula was found in 1 specimens. Fistula found between the coronary artery and its braches Coronary fistula.

Correspondence

Dr. Saurabh Sharma
PhD. Research Scholar,
Dept. of Human Anatomy
Peoples Medical College and
Research Center, Bhopal,
Madhya Pradesh, India



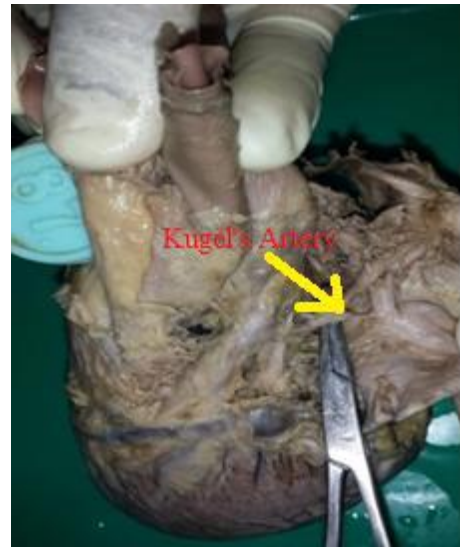The second branch of first segment, the Sino - atrial nodal artery was arising from right coronary artery in 94% and from left coronary artery in 6%. Right conus artery, A.V. nodal artery and right marginal artery were observed in all specimens



In the 3 specimens, Kugel's artery was found its origin from Circumflex artery and coursed posterior to the atrial wall

and was found to anastomose with an atrial branch of right coronary artery.

The right coronary artery form an artey is called the Posterior interventricular artery. The dominance of the heart was decided according to the origin of posterior interventricular artery. Right dominance was observed in 18(70%) specimens. Left dominance was observed in 2(8%) specimens. Co - dominance was found in 5 (22%) specimens.



Shows Kugel's artery

Discussion

Coronary endothelial sprouts developed at around 5th week of Intrauterine life from the bulbous card is which has not yet differentiated into the aorta and pulmonary trunk. The first evidence of coronary vessel development is the appearance of the blood islands at the beginning of the 5th week just under the epicardium in the sulci of the developing heart.

In the present study, the first and highest branch of first segment of right coronary artery (third coronary artery) was arising in 2% of cases from a separate ostium which was not similar to Kalpana (7) and Olabu (8) study which was about 35%.

The second branch of first segment, the Sino - atrial nodal artery was arising from right coronary artery in 94% and from left coronary artery in 6%. When compared to other studies, Sino - atrial nodal artery was arising from right coronary artery in our study was found to be higher (94%).

Table 1: Sino – atrial nodal artery (SANA)

Source of SANA	Baroidi & Scomazzons 1956 Number (%)	James 1961 Number (%)	Caltano & Lopes 1995 Number (%)	Kalpana 2003 Number (%)	Present study
Right coronary artery	51(51)	57(54)	58(58)	56(56)	22(44)
Left coronary artery	41(41)	45(42)	42(42)	35(35)	3(6)
Both	8(8)	4(4)	0(0)	8(8)	-
Directly from Aorta	-	-	-	-	-
Total	100(100)	106 (100)	100(100)	100(100)	25(50)

Table 2

Point of termination	James 1961 Number(%)	Kalpna 2003 Number(%)	Present study
1 Provided by right coronary artery Hypoplastic	-	-	-
¼ way down Posterior interventricular septum	2(2)	9(9)	1(2)
½ way down Posterior interventricular septum	27(25)	46(46)	1(2)
¾ way down Posterior interventricular septum	39(37)	26(26)	5 (20)
At apex	28(26)	8(8)	12(46)
Total	96(90)	89(89)	18(70)

Right dominance was found to be higher than other dominances in our study, which was not similar to other studies. The origin of Posterior interventricular artery is one

of the parameters on which Schlesinger's (1940) system of arterial dominance was based.

Table 3

Dominant artery (Posterior interventricular artery)	Cavalcanti (1995)	Kalpna (2003)	Present study
Right	88.18	89	18(70)
Left	11.82	11	2(8)
Co – dominant	-	-	5(22)
Total	100	100	25(100)

Kugel's artery was origin from circumflex artery and coursed posterior to the left atrium and was found to have an communication with an atrial branch of right coronary artery. These artery was found in three specimens.

Fistula between right coronary artery and pulmonary artery was observed in two specimens in our study.

Conclusion

The variations of the right coronary artery are very common. The identification of normal coronary artery pattern and its branches and variations are important for cardiologists, cardiothoracic surgeons and radiologists while performing coronary angiography and surgical procedures. The study is useful in treatment planning, Angioplasty and Coronary artery bypass surgery of cardiac patients.

References

1. M Esmaeilzadeh, A Khaledifar, Ausefi, Gh Omrani. Right coronary artery to pulmonary artery fistula, the role of echocardiography. Iranian Cardiovas. Res. Journal. 2007; 1(1):50-52.
2. Asim Kumar Datta. Essentials of Human Anatomy. 8th ed. Kolkata: Current books international: 2008:82-83.
3. Fitzgerald MJ, Embryologia humana Sao Paulo: Harper & Row do Brasil, 1980, 48.
4. Padmashree Chougulee, Nazmeen Silotry, Lalith Chavan, Variation in the branching pattern of coronary arteries. I.J.S.R. 2014; 3(8):270-73.
5. Zoll PM, Wessler S, Schlesinger MJ. Interarterial anastomosis in the human heart with particular reference to anaemia and relative cardiac anoxia, Circulation. 1951; 4:797.
6. Yamanaka O, Hobbs RE. Coronary artery anomalies in 1,26,595 patients undergoing coronary arteriography, Cathet. Cardiovasc. Diag. 1990; 21:28-40.