



ISSN Print: 2394-7500
ISSN Online: 2394-5869
Impact Factor: 5.2
IJAR 2018; 4(6): 189-192
www.allresearchjournal.com
Received: 21-04-2018
Accepted: 24-05-2018

Dr. Jay Prakash Yadav
Dept. of Anatomy, Govt.
Medical College, Churu,
Rajasthan, India

Dr. Saurabh Sharma
PhD. Research Scholar,
Dept. of Human Anatomy
Peoples Medical College and
Research Center, Bhopal,
Madhya Pradesh, India

Sex determination from the palatine index using radiographic methods and clinical study models

Dr. Jay Prakash Yadav and Dr. Saurabh Sharma

Abstract

Aims & Objectives: The aim of this study is to evaluate and compare between nasal width and nasal length male and female population.

Conclusion: On the basis of anthropometric measurements, it can be concluded that ethnic differences in the nasal length, width male and female population.

Keywords: Palatal index, study models, anthropometric, palatomaxillary sutures

Introduction

Hard palate forms the roof of the mouth and floor of nasal cavity. It is made up of palatine process of maxilla and horizontal plates of palatine bones. These process meet at the cruciform suture made of intermaxillary, interpalatine and palatomaxillary sutures. The posterior border of hard palate is free and presents a midline projection directed backwards called posterior nasal spine which gives attachment to musculus uvulae on each side.

Many studies have emphasized the importance of anthropometric measurements as a means of studying variation in human populations as well as an important tool in forensic science for crime detection. In the 20th century, the application of anthropometry to the study of racial types was replaced by more sophisticated techniques for evaluating racial differences. Recently, anthropometry has found increase use in medical sciences especially in the discipline of forensic medicine.

Sex, age and racial affinity are the three most vital determinations that must be made when dealing with skeletal remains (Iscan and Helmer, 1993). Sex determination is important for the identification of an individual since many skeletal features vary by gender.

Success in sex determination is limited by the fragmented, scattered, incomplete or burned remains (Reichs, 1986b), but in the forensic identification often fragmentary remains are available (Burris and Harris, 1998). Even broken parts are sufficient, if appropriate areas (pelvis, femoral heads, skull and sternum) are represented (Kerley, 1977). As often fragmentary remains are available for forensic identification, thus the sexual dimorphism of those areas/individual bones of the skeleton should be studied that are most protected and resistant to damage.

Aims and Objectives

1. To measure nasal height and width radiographically and clinically.
2. To measure palatal height and width radiographically and clinically.
3. To calculate nasal and palatal indices.
4. To compare the nasal and palatal indices radiographically and clinically.

Materials and Methods

The study will be carried out using a total sample size of 196 subjects with 98 males and 98 females. Subjects will be selected randomly from OPD of People's Dental College, People's Medical College, Bhopal and Private Diagnostic Centers.

Inclusion Criteria

- Patient age 18-60 years
- Full complement of permanent dentition (excluding third molars)

Correspondence

Dr. Saurabh Sharma
PhD. Research Scholar,
Dept. of Human Anatomy
Peoples Medical College and
Research Center, Bhopal,
Madhya Pradesh, India

- Class I molar and canine occlusion
- Class I skeletal relationship, decided visually by using the two-finger technique
- Free of local factors that disturb the integrity of the dental arches (congenital missing teeth; retained deciduous; supernumerary teeth)

Exclusion Criteria

- Patients with history of any rhinoplastic surgery
- Patients with history of any orthognathic surgery
- Patients with history of any facial or any cosmetic surgery
- Patients with history of orthodontic corrections
- Patients with any congenital disorder
- Patients with history of any trauma

- Patients with history of habits like thumb sucking or mouth breathing.

Name, age and sex of the subject will be noted and any systemic history, if present, will be noted down.

Informed consent of subjects will be taken.

Lateral cephalometric and PA cephalometric view of the subject will be taken.

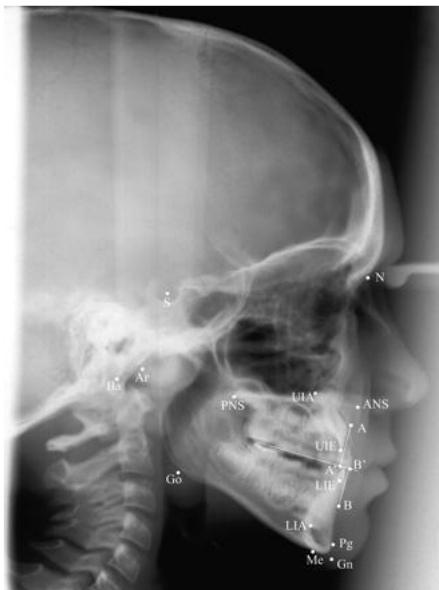Impression of the maxillary arch will be made using alginate impression material. Impression will be poured using dental stone and cast will be fabricated.

Digital vernier caliper will be used to measure the palatal width, palatal length, nasal width and nasal length.

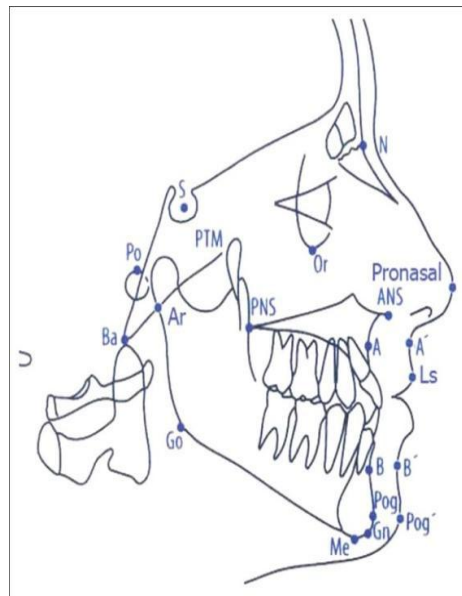
Measurements will be done by one observer to prevent inter-observer error.

Recording Data

Lateral Cephalogram



Lateral Cephalogram-Radiographic View



Lateral Cephalogram- Pictorial Representation

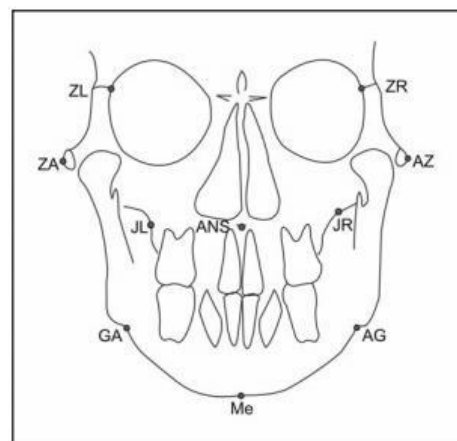
Subject will be positioned with cephalostat using ear rods placed between external auditory meatus in standing position.

- The mid-sagittal plane of subject should be vertical and perpendicular to X-ray beam and parallel to image receptor.
- Frankfort horizontal plane should be oriented parallel to floor.
- Image receptor will be positioned.
- Subject should be instructed to close in centric and swallow.
- Distance of 15cm from mid-sagittal plane to image receptor will be used.
- Distance from subject to source should be 5 feet.

Landmark on lateral cephalogram

- ANS (Anterior nasal spine): Anterior point on maxillary bone
- PNS (posterior nasal spine): Posterior limit of bony palate or maxilla

Postero-Anterior Cephalogram



PA Cephalogram

Head of the subject should be positioned in such a way that the x-ray beam will be perpendicular to the subject's coronal plane with the x-ray source behind the head and the film cassette in front of the patient's face.

Landmark on PA- Cephalogram

JL/JR- Deepest point of the alveolar maxillar process
 ZL/ ZR- The most internal point of the frontozygomatic suture
 ANS- Anterior Nasal Spine

Palatal Index

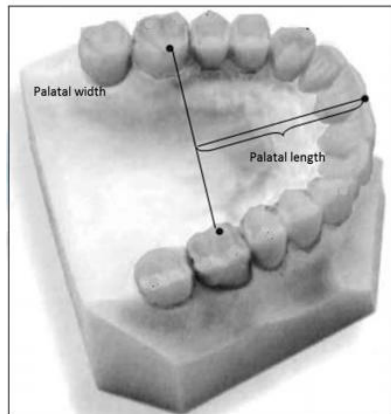
Radiographic Measurement

Palatal length will be measured on Lateral Cephalogram by measuring the distance between anterior nasal spine (ANS) and posterior nasal spine (PNS). Palatal width will be measured on PA-Cephalogram by measuring the distance between JL and JR.

Clinical Measurement

Palatal Width (PW): The linear distance between the mesio-lingual cusp tip of the right and left first permanent molar.

Palatal Length (PL): The perpendicular distance from incisal point to a line joining the mesiolingual cusp tip of the right and left first permanent molar.



Measurement on Dental Cast

Palatal Index will then be calculated as follows:

Palatal Index= (Palatal width/Palatal length) × 100

Result

Table 1: Clinical Measurement

Sex	N	Mean	SD	Minimum	Maximum	P value
M	98	5.91	0.47	2.30	3.75	0.0002
F	98	4.71	0.44	1.70	3.10	0.0001

P value<0.001 and its statistically significant

The range of palatal length in males were 2.30 to 3.75 cms and for females it was 1.70 to 3.10 cms.. The average value for male cases and female cases were 5.91±0.47 cms and 4.71±0.44 cms respectively.

Table 2: Mean palatal width

Sex	N	Mean	SD	Minimum	Maximum	P value
M	98	3.13	0.31	1.80	3.50	0.0001
F	98	2.23	0.25	1.60	2.50	0.0001

The range of palatal width in males were 1.80 to 3.50 cms and for females it was 1.60 to 2.50 cms. The average value for male cases and female cases were 3.13 ±0.31 cms and 2.23±0.25 cms respectively.

Table 3: Mean palatal index

Sex	N	Mean	SD	P value
M	98	87.1 2	16.22	0.0002
F	98	84.23	12.23	0.0001

The average values in males and females were 87.12(±16.22) and 84.23(±12.23) respectively. There was significant statistical difference found in the palatal index of males and females.

Radiographic measurement

Table 4: Palatal length

Sex	N	Mean	SD	Minimum	Maximum	P value
M	98	6.51	0.50	3.50	5.30	0.0002
F	98	4.73	0.42	2.70	4.10	0.0001

The range of palatal length in males were 3.50 to 5.30 cms and for females it was 2.70 to 4.10 cms. The average value for male cases and female cases were 6.51 ±0.50 cms and 4.733±0.42 cms respectively.

Table 5: Palatal width

Sex	N	Mean	SD	Minimum	Maximum	P value
M	98	4.91	0.44	2.31	3.73	0.0002
F	98	3.71	0.32	2.10	3.12	0.0001

The range of palatal width in males were 2.31 to 3.73 cms and for females it was 2.10 to 3.12 cms. The average value for male cases and female cases were 4.91 ±0.44 cms and 3.71±0.32 cms respectively. There was statistically significant difference found in the palatal index of males and females in both models and radiographic methods.

Discussion

Hassanali J *et al.* studied 125 hard palates of African dry skulls and found that 43.2% of total skulls belonged to leptostaphyline group, 23.7% mesostaphyline (intermediate) and 33.1% brachystaphyline palates (wide palate)⁹. In the present study according to palatine index 47.78% skulls belonged to brachystaphyline type, 18.89% mesostaphyline and 33.3% leptostaphyline palates.

These findings correlated with another study conducted by D’Souza *et al.*, where brachystaphyline was more common than leptostaphyline¹⁰. Woo in 1949 studied hard palates of 2,214 skulls in different racial groups and note that palatine index of males is smaller than that of females. It was suggested that mean palatine indices increase in order that the percentages of anterior direction of palatine sutures decrease.

Conclusion

On the basis of anthropometric measurements, it can be concluded that ethnic differences in the palatal length and width. This data is an important tremendous relevance in forensic investigations, clinical practice and plastic surgery. The knowledge of the morphological variations in the hard palate is very helpful in maxillofacial surgeries and also in repair of cleft palate.

References

1. Sumati, Patnaik VVG, Phatak A. Determination of sex from hard palate by discriminant function analysis.

- International Journal of Basic and Applied Medical Sciences. 2012; 2(3):243-51.
2. Ikechukwu E, Bassey T, Ihetuge C. Study of the nasal indices and bialar angle of the Ibo and Yoruba Ethnic groups of Nigeria. *Journal of Biology, Agriculture and Healthcare*. 2012; 2(11):149-52.
 3. Ray SK, Saha K, Kumar A, Banjare S. Anthropometric Study of Nasal Index among the Population of Western Uttar Pradesh Region. *Int J Sci Stud*. 2016; 4(2):65-70.
 4. G Oladipo, H Fawehinmi, Y Suleiman. The study of nasal parameters (nasal height, nasal width, nasal index) amongst the Yorubas of Nigeria. *The Internet Journal of Biological Anthropology*. 2008, 3(2).
 5. G Oladipo, Udoaka A, Afolabi E, Manuel IB. Nasal parameters of Itsekiris and Urhobos of Nigeria. *The Internet Journal of Biological Anthropology*. 2008; 3(1).
 6. Bass WM. Human osteology in the skulls or cranium 4th Edition Missouri Archaeological Society, Columbia, 1995, 83-5.
 7. Porter JP, Olson KL. Analysis of the African American female nose. *Plastic Reconstruction Surgery*. 2003; 111(2):627-8.
 8. Woo JK. Direction and type of transverse palatine suture and its relation to the form of hard palate. *American Journal of Physical Anthropology*. 1949; 7:385-99.
 9. Paul O, Yinka OS, Taiye AS, Gift AM. An anthropometric study of some basic nasal parameters of three major ethnic groups in Kogi state, Nigeria. *American Journal of Clinical and Experimental Medicine*. 2015; 3(2):62-7.
 10. Zolbin MM, Hassanzadeh G, Mokhtari T, Arabkheradmand A, Hassanzadeh S. Anthropometric Studies of Nasal Parameters of Qazvin Residents, Iran. *MOJ Anat Physiol*. 2015; 1(1):1-5.