ISSN Print: 2394-7500
ISSN Online: 2394-5869
Impact Factor: 5.2
IJAR 2019; 5(4): 76-79
www.allresearchjournal.com
Received: 06-02-2019
Accepted: 07-03-2019

Sibani Patro
Department of Radiodiagnosis, IMS & SUM hospital, Siksha O Anusandhan University, K8, Kalinga Nagar, Bhubaneswar, Odisha, India

Satya SG Mohapatra
Department of Radiodiagnosis, IMS & SUM hospital, Siksha O Anusandhan University, K8, Kalinga Nagar, Bhubaneswar, Odisha, India

Adya K Panda
Department of Radiodiagnosis, IMS & SUM hospital, Siksha O Anusandhan University, K8, Kalinga Nagar, Bhubaneswar, Odisha, India

Subhashree Das
Department of Radiodiagnosis, IMS & SUM hospital, Siksha O Anusandhan University, K8, Kalinga Nagar, Bhubaneswar, Odisha, India

Rajesh Pattnaik
Department of Radiodiagnosis, IMS & SUM hospital, Siksha O Anusandhan University, K8, Kalinga Nagar, Bhubaneswar, Odisha, India

Correspondence
Satya SG Mohapatra
Department of Radiodiagnosis, IMS & SUM hospital, Siksha O Anusandhan University, K8, Kalinga Nagar, Bhubaneswar, Odisha, India

CT guided Tru-cut biopsy of lung masses and its histopathological correlation at tertiary care center in eastern India

Sibani Patro, Satya SG Mohapatra, Adya K Panda, Subhashree Das and Rajesh Pattnaik

Abstract
Lung cancer is a standout amongst the most widely recognized reasons for malignant growth related demise around the world. With the assistance of CT, an expanding number of lung injuries are recognized and described. In any case, histopathological analysis is regularly important to decide the most fitting administration of these injuries. Here our point is to associate radiological discoveries of lung illnesses with histopathological discoveries and to survey the adequacy, convenience of Tru-cut biopsy as an analytic strategy in lung tumors. Along with that we attempted to decide the occurrence and kind of lung malignancy predominant in this region. For this study we took 50 patients who were alluded to the Department of Radio diagnosis, IMS and Sum Hospital experienced CT-guided Tru-cut biopsy and was corresponded with histopathological examination. In result we got Majority of the cases were malignant. Adenocarcinoma prevailed among the cases, trailed by squamous cell carcinoma and small cell carcinoma. CT-guided Tru-cut biopsy is a generally protected, basic and reliable methodology with high diagnostic yield to set up histological determination. Consequently, CT-guided transcutaneous biopsy ought to be prudently utilized with imaging in order to choose appropriate treatment choices and accomplish desirable therapeutic response.

Keywords: Lung mass, Trucut biopsy, Squamous cell carcinoma, Adenocarcinoma, Small cell carcinoma, Diagnostic accuracy

1. Introduction

Lung cancer is the most common cause of morbidity and mortality worldwide [1]. With the help of CT, an increasing number of lung lesions are detected and characterised. But histopathological diagnosis is often necessary to determine the most appropriate management of these lesions.

In this clinical scenario, imaging-guided biopsy is one of the main methods to obtain tissue specimens. Various imaging techniques including computed tomography (CT) fluoroscopy and ultrasound (US) can be used to guide chest biopsies, but CT is most frequently employed because of its high spatial and contrast resolution as well as its 3D imaging ability; in many cases CT is preferred based on the localisation of the nodule or other patient-related factors. Tru-cut biopsy is a simple procedure, relatively safe, rapid, reliable technique for the diagnosis of lung mass lesions, particularly with the aid of CT scan [2, 3]. The diagnostic accuracy has been reported as being >80% for benign disease and >90% for malignant disease [4]. CT with core biopsy not only distinguishes between benign and malignant lesions but also helps in establishment of histological diagnosis of lung cancer, so initiation of appropriate chemotherapy or surgery is possible without unnecessary delay. CT-guided Tru-cut biopsy is an accurate and sensitive diagnostic procedure in thoracic malignancy [5].

Indications includes a new or enlarging solitary nodule or mass greater than 1cm in diameter, multiple nodules in a patient without known neoplastic disease or in prolonged remission, non-resolving pneumonic consolidation, diagnosis of hilar masses following negative bronchoscopy, biopsy of malignant masses for molecular diagnosis and targeted therapy.

Contraindications includes uncooperative patients, bleeding diathesis (International normalized ratio [INR] >1.4, Platelet count <50,000 per µL), positive pressure ventilation, severe respiratory compromise, pulmonary hypertension, severe interstitial lung disease,

small lesions close to the diaphragm, central lesions adjacent to large vessels or bronchi, pneumothorax, severe bullous emphysema, suspected hydatid cyst. The most common complication includes pneumothorax [6, 7], Other complications includes alveolar hemorrhage, air embolism, hemothorax, hemoptysis.

2. Materials and methods

The Prospective study of 50 patients who were referred to the Department of Radiodiagnosis, IMS & Sum Hospital underwent CT-guided Tru-cut biopsy and was correlated with histopathological examination. The study was conducted over a period of 6months from June 2018 to November 2018.

2.1. Prerequisities before biopsy

Prothrombin time (PT), international normalized ratio (INR), activated partial thromboplastin time (APTT), and platelet count were checked. Aspirin was discontinued 5 days prior to biopsy. Patients on oral anticoagulants were switched to heparin for 2 to 3 days, which in turn was discontinued few hours before the procedure. Informed consent was obtained in a written form from all patients.

2.2. Pre biopsy plans

Location of lesion, Location of number of fissures adjacent to the lung lesion or within the pathway of the biopsy needle trajectory, Location of adjacent arteries and veins, to plan the needle trajectory to avoid these vascular structures, Angle of entry of needle, route of entry and distance between skin and the lesion and the length of throw (1 or 2.5cm) on the CT scan monitor.

2.3. Patient positioning and instructions

The patients were positioned either in prone, supine or lateral depending on the skin site entry chosen. The breathing technique required during the procedure was explained to be patient and practiced beforehand. Deep breaths and coughing was asked to be avoided.

2.4. Biopsy procedure

Scan the lesion in biopsy position. Skin entry site was localized: placing a row of metallic markers on the skin at the desired level. Scan was repeated at the marker site. The skin site was sterilized with betadine and aseptic measures were followed. Local anaesthesia (lidocaine) was instilled to skin and subcutaneous tissue, chest wall musculature and the overlying pleural surface. Outer guiding 17G coaxial needle was placed into the subcutaneous tissue. Needle trajectory was then checked with further scan and adjusted prior to pleural puncture. A single pleural puncture was made and the needle path was adjusted. The outer guiding needle was positioned on the near edge of the lung lesion. Breath hold was performed by the patient during needle advancement to limit lung parenchymal injury. With the guiding needle in position, the inner stylet was removed and finger was placed over the lumen. The 18G cutting needle was placed into the lesion via the guiding needle. Biopsy gun firing was done to obtain an adequate tissue core.The tissue core was removed from cutting needle and placed into formalin for histopathological examination.

3. Results and discussion

3.1. Age distribution

Age In Years	No. of Patients
21-30	1
31-40	3
41-50	10
51-60	14
61-70	13
>70	9

3.2. Clinical features

Symptoms	No. of Patients
Cough with expectoration	50
Chest pain	43
Dyspnea on exertion	21
Hemoptysis	12
Weight loss	6
Hoarseness of voice	2

3.3. Location of lesion

Location of lesion	No. of patients
Right upper lobe	17
Right middle lobe	7
Right lower lobe	7
Left upper lobe	8
Left lower lobe	6
Right hilum	3
Left hilum	2

3.4. Histopathological findings

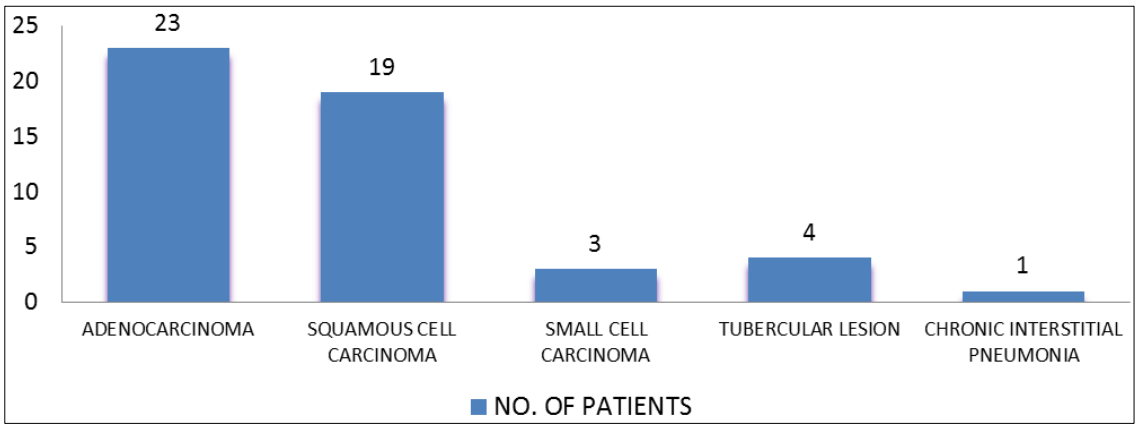

3.5. Correlation of CT findings with histopathology findings

Characteristics		No. of Lesions	Histopathology	
			B	M
Shape	Oval/round	5	3	2
	Irregular	45	2	43
Margins	Circumscribed	4	2	0
	Lobulated	10	3	7
	Spiculated	38	0	38
Enhancement	Enhancing			
	Homogeneous	8	4	4
	Heterogeneous	42	1	41
	Non Enhancing	0	0	0
Cavitation	Cavitatory	4	2	2
Calcification	Present	7	1	6
Lymphadenopathy	Present	38	3	35
Pleural effusion	Present	25	3	22
Lung collapse	Present	10	2	8
Svc obstruction	Present	2	0	2
Mediastinal invasion	Present	6	0	6
Chest wall invasion	Present	3	0	3

3.6. Overall correlation of ct findings with histopathological findings

	CT	Histopathology
Malignant	47	45
Benign	3	5

Axial CT image shows an ill-defined lesion with spiculated margin in lower lobe of right lung extending upto the hilum. There are few satellite nodules.
On histopathology: Squamous cell carcinoma (below fig. 1).

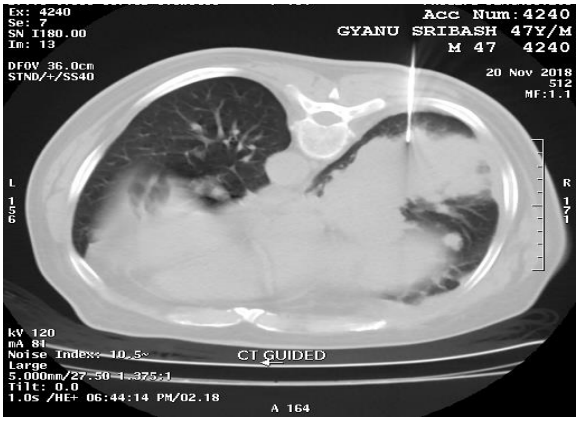

Fig 1: Squamous cell carcinoma

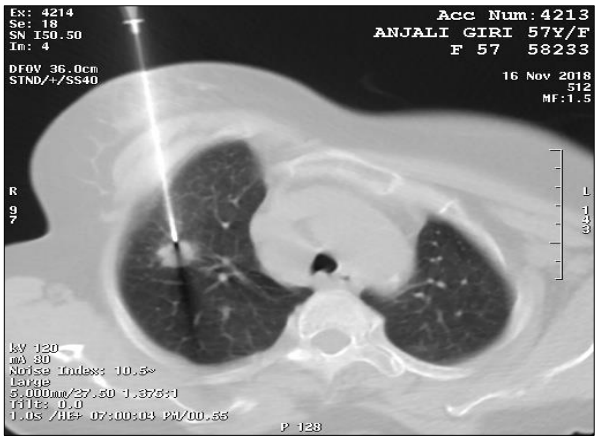

Fig 2: Small cell carcinoma

Axial CT image shows an oval, lobulated lesion in upper lobe of right lung.
On histopathology: Small cell carcinoma (Fig. 2)

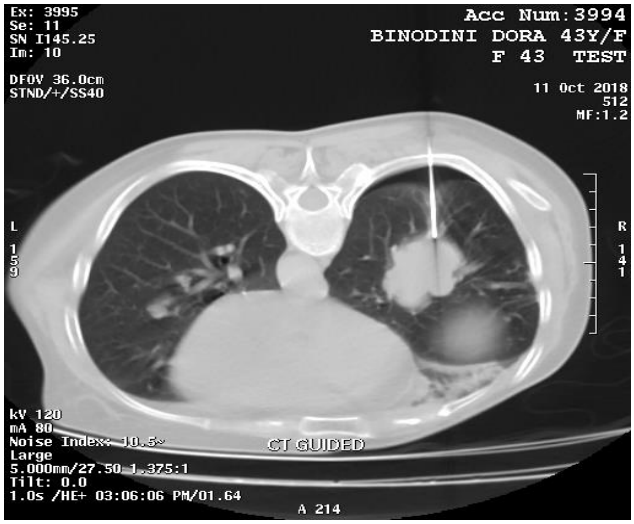

Fig 3: Adenocarcinoma

Axial CT image shows an oval, lobulated lesion in lower lobe of right lung.
Post procedure: Minimal pneumothorax and alveolar hemorrhage On histopathology: Adenocarcinoma (above fig. 3)

Conclusion

CT scan is a very useful non-invasive diagnostic modality in the clinical evaluation of lung masses. CT guided biopsy is a simple, safe and reliable procedure with high diagnostic accuracy for diagnosis. Histopathological diagnosis is necessary to determine the most appropriate management of these lesions. The most prevalent lung cancer in our study was adenocarcinoma. pneumothorax and alveolar hemorrhage was the most common complications.

Reference

1. Epidemiology and End Results (SEER) statistics fact sheets: Lung and Bronchus by National Cancer Institute.

2. Enzinger FM, Weiss SW. Soft Tissue Tumors. 3rd ed. New York: USA: Mosby, 1995.
3. Manhire A, Charig M, Clelland C, Gleeson F, Miller R, Moss H *et al.* Guidelines for radiologically guided lung biopsy. Thora. 2003; 58:920-36.
4. Tsukada H, Satou T, Iwashima A, Souma T. Diagnostic accuracy of CT-guided automated needle biopsy of lung nodules. AJR Am J Roentgenol. 2000; 175:239-43.
5. Viggiano RW, Swensen SJ, Rosenow EC 3rd. Evaluation and management of solitary and multiple pulmonary nodules. Clin Chest Med. Pub Med Google Scholar. 1992; 13(1):83-95.
6. Ohno Y, Hatabu H, Takenaka D, Higashino T, Watanabe H, Ohbayashi C *et al.* CT-guided transthoracic needle aspiration biopsy of small (< or=20 mm) solitary pulmonary nodules. AJR Am J Roentgenol. 2003; 180:1665-9.
7. Anderson JM, Murchison J, Patel D. CT-guided lung biopsy: Factors influencing diagnostic yield and complication rate. Clin Radiol. 2003; 58:79.