



ISSN Print: 2394-7500
ISSN Online: 2394-5869
Impact Factor: 5.2
IJAR 2019; 5(4): 204-206
www.allresearchjournal.com
Received: 01-02-2019
Accepted: 03-03-2019

Dr. Shubhangi S Gattani
MPT Student In Neuro
Physiotherapy, Dr. A. P. J.
Abdul Kalam College of
Physiotherapy, Loni,
Ahmednagar, Maharashtra,
India

Dr. RM Singaravelan
Professor/HOD Neuro-
physiotherapy, Dr. A. P. J.
Abdul Kalam College of
Physiotherapy Loni,
Ahmednagar, Maharashtra
India

Therapeutic exercises in patient with spinal cord injury: A case report

Dr. Shubhangi S Gattani and Dr. RM Singaravelan

Abstract

Spinal Cord Injury (SCI) is the injury to neural elements of the spine which can result in different degrees of sensorimotor deficits and autonomic and sphincter dysfunction. Over the last four decades, the focus of spinal cord injury (SCI) rehabilitation has shifted from medical management to issues that affect quality of life and community participation.

This case report describes use of therapeutic exercise for rehabilitating the patient with spinal cord injury. A 28 year old male businessman by occupation met with an accident on 11th may 2017 and was operated for the same on 12th may 2017 and came to Neuro Physiotherapy department on 21st April 2018 with chief complaint of difficulty in walking since 11 months. As per the investigations, patient was diagnosed with spinal cord injury (T12 level). Physiotherapy treatment was given for 30 weeks [1 hour/day, 5 days/week] for 6 weeks followed by 3 weeks of interval (in this way 5 sessions of conventional physiotherapy treatment was completed). 30 weeks intervention includes transfer activity, functional training, gait re-education, functional independence. ASIA Impairment Scale (AIS) and Spinal Cord Independence Measure Sale (SCIMS) were the outcome measures of the study. After 30 weeks of intervention, there was significant improvement in the walking, ADLs; motor and sensory score.

Keywords: Spinal cord injury, Asia impairment scale, spinal cord independence measure scale, physiotherapy treatment

Introduction

Spinal cord injury (SCI) is a series of complex syndromes of central nerve system ^[1] of any etiology (traumatic and non-traumatic) affecting the spinal cord, and may lead to alterations of neurological function below the lesion: motor, sensory and autonomic ^[2]. The most common consequence of spinal cord injury is paralysis. It is a low- incidence, high- cost disability requiring tremendous changes in an individual's lifestyle ^[3]. The neurologic deficit or dysfunction can be either temporary or permanent, complete or incomplete ^[4]. Incomplete SCI subjects strongly depend on visual input to compensate for proprioceptive deficits and impaired balance. With respect to etiological factors ^[3], trauma accounts for approximately 60% of cases of spinal cord injury in developed countries, and about 80% in developing countries, Traffic accidents have a significant overall incidence, ranging from 12% to 63% ^[3]. It also has widespread consequences for many body functions including bowel, bladder, respiratory, cardiovascular and sexual functions ^[5]. The rehabilitation of patients with spinal cord injury (SCI) is greatly important and promotes longer survival, less morbidity, and higher quality of life ^[1]. Conventional rehabilitation primarily provides compensatory strategies for accomplishing mobility and strengthening above the level of the lesion ^[6].

Case description

History- 28 year old male who is businessman by occupation met with an accident with four wheeler in the evening on 11 may 2017. He was brought to nearby hospital on two wheeler by people around him. X-ray was done and immediately next day he was operated for the vertebral fracture with dorsolumbar spine fixation by using screws and rod for T11, T12 and L1. Then patient was referred to the Neuro Physiotherapy department, came with a chief complaint of difficulty in walking since 11 months, in between those 11 months he was taking physiotherapy treatment at home, after then patient was examined and physiotherapy treatment was started and intervention was carried out for 30 weeks[1 hour/day, 5 days/week]

Correspondence

Dr. Shubhangi S Gattani
MPT Student In Neuro
Physiotherapy, Dr. A. P. J.
Abdul Kalam College of
Physiotherapy, Loni,
Ahmednagar, Maharashtra,
India

for 6 weeks followed by 3 weeks of interval (in this way 5 sessions of conventional physiotherapy was completed).

Investigations

A spine Radiograph of the patient showed anterior vertebral compression fracture and wedge compression fracture of T12 vertebrae.

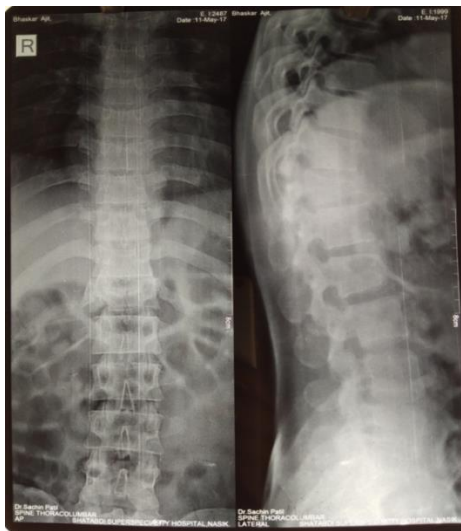

Fig 1: Pre-operative X-ray

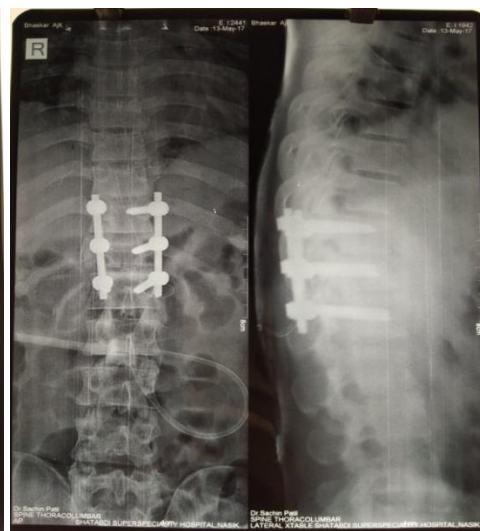

Fig 2: Post-operative X-ray

MRI finding shows moderate collapse of D12 vertebral body noted, displaced vertebral body fracture extending into posterior elements, Bulging of posterior portion compressing cord aggravated by epidural hemorrhage, moderate to severe canal stenosis, mild wedge collapse of L2 vertebral body.

Outcome measures

1. ASIA Impairment Scale (AIS)
2. Spinal Cord Independence Measure Scale (SCIMS)

Intervention

After evaluation the patient was advised to come for regular Physiotherapy treatment. On the basis of problems list, short term and long term goals were planned. Treatment session was given for 30 weeks [1 hour/day, 5 days/week] for 6 weeks followed by 3 weeks of interval (in this way 5 sessions of conventional physiotherapy treatment was completed) with breaks in between to rest.

Procedure

Physiotherapy assessment was done. ASIA Impairment Scale and SCIMS were used to assess the patient and protocol was individualized, based on specific impairments and patient goals. Initially, the treatment protocol started with transfer which include wheelchair to bed, bed to wheelchair and then progress to wheelchair to mat, mat to wheelchair; hot water fermentation for low back pain, mat activity started with prone on elbows, prone on hands, quadripod and progressed to perturbations in quadripod; trunk exercises in sitting includes side flexion, forward flexion and side to side rotations; Pelvic bridging activity, abdominal curls, back extensor exercises. Passive Range of Motion (ROM) for lower limbs and resistance training for upper limb with weight cuff and was progressed to dumbbells; stretching to hamstring, tendoachillies, quadriceps; sit to stand with the help of walker, mini squats initially without hold progressed to hold. Gait training was initially started with help of mirror feedback in parallel bars with Hip Knee Ankle Foot Orthosis (HKAFO) progressed to gait training on walker than progressed to crutch walking under supervision, wheel chair training on levelled surface progressed to ramp, intermittent catheterization for bladder was started at 4th session. ASIA Impairment Scale (AIS),

Spinal Cord Independence Measure Scale (SCIMS) scale was reassessed after 30 weeks and significant improvement was seen in pre and post scores.

Data analysis and results

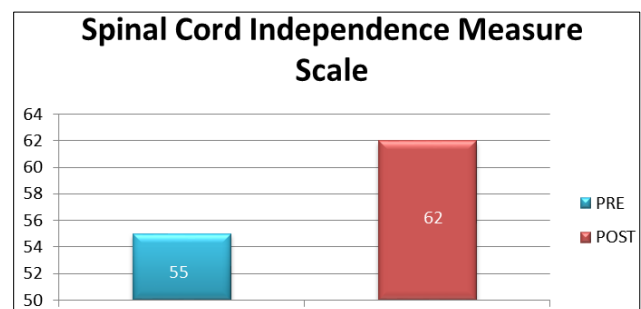
Table 1: ASIA Impairment Scale (AIS)

Assessment	Neurological level	Complete/Incomplete	AIS
PRE	T12	Incomplete	B
POST	T12	Incomplete	C

On day 1 pre assessment score for right sensory and motor was T12 and for left sensory and motor was L1; post assessment for right sensory L1 and motor L2, left sensory and motor T12.

Table 2: Spinal Cord Independence Measure Scale (SCIM)

SCIM	Pre	Post
Score	55/100	62/100



Graph 1: represents SCIMS score pre and post intervention

Discussion

The purpose of study was to see the improvement in patient with spinal cord injury after receiving therapeutic physiotherapy for 30 weeks. The primary aim of the study

was to achieve the functional independence through stage related tonal management, mat activity, transfer activity, balance training, gait reeducation and functional training. After the intervention improvement was seen in SCIMS, pre-intervention score was 55/100 and total post-intervention score was 62/100, which means it has been improved in various aspects like Transfer, bladder, ambulation.

Douglas (1983) *et al* regarding the benefits of using Orthosis while ambulation, is the prevention of joint deformity and improvement of joint range of motion. They claimed that during standing the body weight is applied vertically downward and symmetrically upon both feet. In standing position the gravitational positioning of flexed joints decreased, and as a result the risk of deformity of lower limb joint decreased as well.⁷

Improvement was also seen in ASIA Impairment Scale, pre intervention grading was B after 30 weeks of intervention the grading was C.

Conclusion

Physiotherapy interventions with a focus on participation allowing a preliminary conclusion that exercises and gait training both have a positive effect on participation after SCI. Significant changes were seen in anxiety, aggression and attention through ASIA Impairment Scale, Spinal Cord Independence Measure Scale after 30 weeks i.e 5 sessions of physiotherapy treatment.

Limitation

The limitation of study was lack of physiotherapist during 3 weeks of interval.

References

1. Jie Shi, Chunna Lan, Chunjiao Zhu, Zhongjie Yi, Lizao Chen, Changjie Zhang. Rehabilitation of a SCI patient involving the medulla oblongata injury after a traffic accident: a case report. *Int J Clin Exp Med*. 2016; 9(11):22648-22651.
2. Liliana Rodríguez S, John Gonzalez, Meryene Barrios, Claudia Pachon. Physiotherapeutic Intervention in a Patient with Spinal Cord Injury (SCI) *Indian Journal of Science and Technology*. 2017; 10(32). DOI:10.17485/ijst/2017/v10i32/117217
3. O'Sullivan SB, Schmitz TJ. *Physical rehabilitation fifth edition*.
4. Associação Brasileira de Medicina Física e Reabilitação Spinal cord injury: rehabilitation *Acta Fisiatr*. 2012; 19(2):90-8.
5. Harvey LA. Physiotherapy rehabilitation for people with spinal cord injuries. *Journal of Physiotherapy*. 2016; 62:4-11.
6. Andrea Behrman L, Susan Harkema Locomotor J. Training after Human Spinal Cord Injury: A Series of Case Studies *Physical Therapy*. 2000; 80(7):688-700.
7. Douglas R, Larson PF, D' Ambrosia R, McCall RE. The LSU Reciprocal-Gait Orthosis. *Orthopedics*. 1983; 6:834-8.