



ISSN Print: 2394-7500
ISSN Online: 2394-5869
Impact Factor: 5.2
IJAR 2019; 5(9): 326-328
www.allresearchjournal.com
Received: 22-07-2019
Accepted: 24-08-2019

Yoshita Bhawsinka
Department of Ophthalmology
Kalinga Institute of Medical
Sciences, KIIT University,
Patia, KIIT Road,
Bhubaneswar, Odisha, India

Arif Mohammad Rohan
PG Resident, Department of
Ophthalmology, Kalinga
Institute of Medical Sciences,
KIIT University, Patia, KIIT
Road, Bhubaneswar, Odisha,
India

Manmath Kumar Das
Department of Ophthalmology
Kalinga Institute of Medical
Sciences, KIIT University,
Patia, KIIT Road,
Bhubaneswar, Odisha, India

Correspondence
Arif Mohammad Rohan
PG Resident, Department of
Ophthalmology Kalinga
Institute of Medical Sciences,
KIIT University, Patia, KIIT
Road, Bhubaneswar, Odisha,
India

Spectral domain optical coherence tomographic in vogt-koyanagi-harada syndrome

Yoshita Bhawsinka, Arif Mohammad Rohan and Manmath Kumar Das

Abstract

Optical coherence tomography (OCT) is a rapidly evolving, robust technology that has profoundly changed the practice of ophthalmology. Compared to conventional TD-OCT, SD-OCT had statistically significantly better reproducibility in most sectoral macular thickness and peripapillary RNFL sectoral measurements. Here our aim is to report Spectral-Domain Optical Coherence Tomography (SD-OCT) findings in a case of Acute VKH syndrome. SD-OCT was performed on a case of Acute VKH. Both 5 line HD raster scan and the central macular scan was done in both eyes. Retinal Pigment Epithelium (RPE) was found to be intact with no pigment epithelial detachment. Multiple pockets of subretinal fluid with multiple subretinal septa are seen. The internal limiting membrane (ILM) shows irregularities. Subretinal deposits of fibrin are seen. Inner retina appears thickened and the vitreomacular interface is found to be normal. The mean choroidal thickness was found to be increased. SD-OCT is a very good diagnostic tool to differentiate VKH from other causes of exudative retinal detachment like central serous chorioretinopathy and posterior scleritis.

keywords: Acute Vogt- Koyanagi –Harada syndrome (VKH), spectral domain, optical coherence tomography (OCT)

Introduction

Vogt-Koyanagi-Harada disease (VKH) is an uncommon multisystem inflammatory disorder characterized by panuveitis with serous retinal detachment ^[1]. Most patients seek medical care by an ophthalmologist at the acute uveitic stage when blurred vision becomes a problem. At this stage, the patients may suffer from bilateral blurred vision, first occurring to one eye and then the other several days later. Clinical examinations usually reveal multiple serous retinal detachments, and edema and congestion of optic papilla, choroidal thickening, and protrusion around the optic papilla ^[2]. Optical coherence tomography (OCT) having advantages of non-invasiveness, high safety, high resolution (5 μ m axial resolution), fast scanning speed, and large data acquisition capability (which allows for 3D reconstruction and stratified analysis), high repeatability, is considered an ideal method for quantitative analysis of internal retina structure. Researchers have previously described OCT manifestations of VKH at the acute uveitic stage ^[3, 4].

As spectral-domain OCT becomes more widely adopted, its higher axial resolution and greater sensitivity may lead to increased recognition and awareness of these features. Here in this study we described the features of acute VKH disease on SD-OCT, that are best explained by the formation of multiple subretinal compartments separated by dense fibrinous membranes.

Material and methods

Patient was evaluated thoroughly, anterior segment was examined under slit lamp and posterior segment was examined by indirect ophthalmoscopy. To support our diagnosis investigation like fundus photo and fundus fluoresceine angiography (FFA) was done. SD-OCT was also done and the following parameters were studied retinal pigment epithelium integrity and regularity, outer retina, inner retina, vitreomacular interface. The choroidal thickness was measured using enhanced depth imaging method in SD-OCT.

Case history

The patient for this experiment was a 23yr old, female presented with complains of severe headache (generalized and moreover the occipital area) with bilateral progressive diminution of vision. She was admitted under neurology as a case of migraine. Her all other vital parameters were normal and she was investigated with MRI, MRV which were found to be normal. When the headache did not subside and vision did not improve even after 2 days of treatment, she was referred to the ophthalmology department. She gives no history of similar ocular complaints in the past, trauma or any ocular surgery. There was no history of fever, seizures and other systemic illnesses.

Results

She was well oriented and her general examination was normal. On ocular examination, her visual acuity at the time of presentation in the right eye (RE) was 2/60 (counting fingers 2 meters) and in left eye (LE) was also 2/60 (counting fingers 2 meters). Pupils of both the eyes were round, regular but sluggishly reacting to light. The rest anterior segment was normal in both eyes. On dilated funduscopy, both the eyes had a similar finding. The media was clear. Optic disc of both eyes was normal in size and shape but was hyperemic. Although Cup:disc ratio was 0.3:1. The macula of both the eyes showed an absent foveal reflex with multiple pockets of serous retinal detachment. Retinal vessels were within normal limits. [Fig 1]

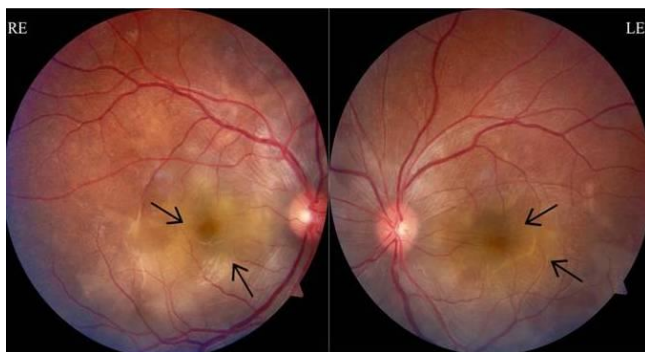

Fig 1: Image of both Right and left eye fundus showing multiple pockets of subretinal fluid.

Since there was an exudative retinal detachment in both the eyes, SD-OCT and Fundus fluorescein angiography (FFA) was advised to reach a diagnosis.

Her SD-OCT of both eyes showed multiple pockets of subretinal fluid with multiple subretinal septa are seen. The internal limiting membrane shows irregularities. Retinal pigment epithelium (RPE) was found to be intact with no pigment epithelial detachment. Sub retinal deposits of fibrin are seen. Inner retina appears thickened and the vitreomacular interface is found to be normal. The mean choroidal thickness was found to be increased. RPE undulation index of RE was 0.998 and that of LE was 0.985. [Fig 2]

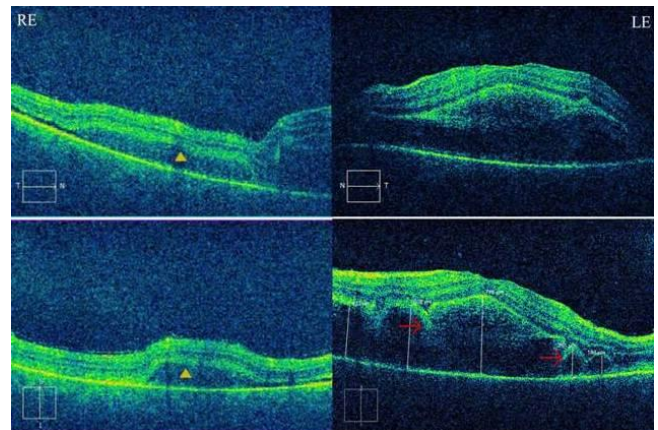


Fig 2: SD-OCT image of both eye showing typical findings of VKH syndrome before treatment (Arrow mark represents multiple subretinal septa and yellow triangle showing pockets of subretinal fluid)

Fundus fluorescein angiography (FFA) showed typical starry sky appearance in both the eyes. In early arteriovenous phase (15 to 30 secs) of FFA, there were numerous punctate hyper fluorescent dots at the level of RPE in both the eyes. These dots enlarge and stain the surrounding subretinal fluid. [Fig 3a, 3b] In Late phase (30 secs – 10 mins) of FFA, there were Multiple serous retinal detachments with pooling of dye in the subretinal space in both eyes. [Fig 3c, 3d]

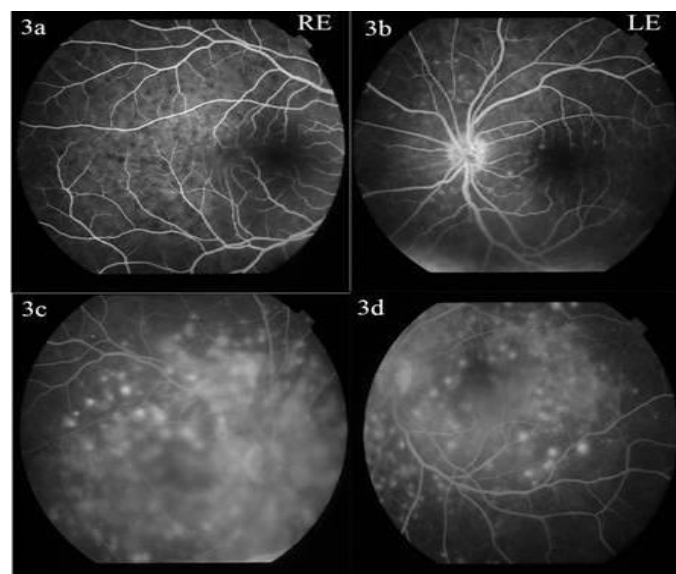


Fig 3: FFA image of both eyes in early phase (fig 3a & 3b) and in late phase (fig 3c & 3d) showing typical starry sky appearance of VKH syndrome.

Considering typical SD-OCT findings of VKH along with FFA appearance a provisional diagnosis of VKH was made. she was started on Intravenous methylprednisolone 1gm iv infusion in 1 pint 5% dextrose (over 90 min) once daily for 3 days With continuous BP and HR monitoring, HGT was recorded pre and post-injection. Post-treatment funduscopy revealed decreased pockets of subretinal fluids in both eyes. SD-OCT findings 2 months after treatment showed Shallow pockets of subretinal fluid. The internal limiting membrane still shows some irregularities. Inner retina and the vitreomacular interface is found to be normal. RPE undulation index of RE was 0.991 and LE was 0.994. [Fig 4]

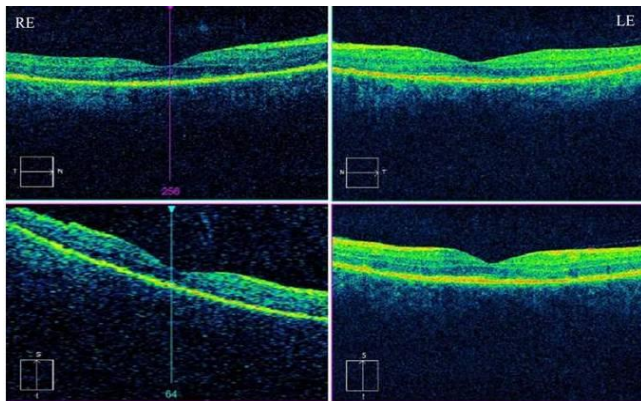


Fig 4: SD-OCT image of both eye showing no VKH syndrome after treatment

Discussion

Bilateral intraocular inflammation with exudative retinal detachment is a hallmark clinical feature of VKH disease in the acute stage [5, 6, 7]. Yamaguchi *et al.* suggest that the onset of the inflammatory phase of VKH disease leads to acute extravasation of protein-rich, fibrinous fluid that accumulates in the subretinal space. A fibrin membrane then forms on the RPE [5], subretinal septum is a typical finding of VKH, responsible for multilobular dye pooling in FA [5]. Fluctuations in the internal limiting membrane (ILM) and folds in RPE are common in VKH. Fluctuations in ILM is defined as at least 2 sets of peaks and trough at the level of ILM [6]. Fovea thickness and RPE undulation index are elevated significantly in VKH. RPE undulation index = $(L_h + L_v) / 12000$

L_h and L_v are RPE line length in 6mm foveal centered horizontal and vertical OCT scans [9]. RPE undulation index quantitatively describes choroidal deformations and is significantly reduced after treatment, and is used to assess the effectiveness of treatment [10]. As spectral-domain OCT becomes more widely adopted, its higher axial resolution and greater sensitivity may lead to increased recognition and awareness of these features.

Conclusion

In conclusion, we believe that the features of acute VKH disease on SD-OCT are best explained by the formation of multiple subretinal compartments separated by dense fibrinous membranes. However, this entity may be confused as acute central serous chorioretinopathy (CSC), particularly in cases presenting with bilateral serous retinal detachments and pigment epithelium detachments (PEDs) [5, 8, 9]. Two conditions have different pathophysiology since VKH is primarily a diffuse stromal choroiditis with secondary

involvement of the choriocapillaris, whereas as CSC occurs a result of choroidal vascular hyperpermeability. Typically, SD-OCT is a very good diagnostic tool to differentiate VKH from other causes of exudative retinal detachment like central serous chorioretinopathy and posterior scleritis.

References

- Burkholder BM. Vogt-Koyanagi-Harada disease. *Curr Opin Ophthalmol.* 2015; 26(6):506-11.
- Shinohara K, Moriyama M, Shimada N *et al.* Analysis of shape of eyes and structure of optic nerves in eyes with tilted disc syndrome by swept-source optical coherence tomography and three-dimensional magnetic resonance imaging. *Eye (Lond).* 2013; 27(11):1233-41.
- Parc C, Guenoun JM, Dhote R *et al.* Optical coherence tomography in the acute and chronic phases of Vogt-Koyanagi-Harada disease. *Ocul Immunol Inflamm.* 2005; 13(2-3):225-27.
- Okamoto Y, Miyake Y, Horio N *et al.* Delayed regeneration of foveal cone photopigments in Vogt-Koyanagi-Harada disease at the convalescent stage. *Invest Ophthalmol Vis Sci.* 2004; 45(1):318-22.
- Yamaguchi Y, Otani T, Kishi S. Tomographic features of serous retinal detachment with multilobular dye pooling in acute Vogt-Koyanagi-Harada disease. *Am J Ophthalmol.* 2007; 144:260-5.
- Rao NA, Gupta A, Dustin L *et al.* Frequency of distinguishing clinical features in Vogt-Koyanagi-Harada disease. *Ophthalmology.* 2010; 117(3):591-599.
- Aggarwal K, Agarwal A, Deokar A, Mahajan S, Singh R, Bansal R *et al.* OCTA Study Group. Distinguishing features of acute Vogt-Koyanagi-Harada disease and acute central serous chorioretinopathy on optical coherence tomography angiography and en face optical coherence tomography imaging. *J Ophthalmic Inflamm Infect.* 2017; 7(1):3.
- Shin WB, Kim MK, Lee CS, Lee SC, Kim H. Comparison of the clinical manifestations between Acute Vogt-Koyanagi-Harada disease and acute bilateral central serous chorioretinopathy. *Korean J Ophthalmol.* 2015; 29(6):389-395.
- Lin D, Chen W, Zhang G *et al.* Comparison of the optical coherence tomographic characters between acute Vogt-Koyanagi-Harada disease and acute central serous chorioretinopathy. *BMC Ophthalmol.* 2014; 14:87.
- Hosoda Y, Uji A, Hangai M, Morroka S *et al.*, Relationship between retinal lesions and inward choroidal bulging in Vogt-Koyanagi-Harada Disease, *Am J Ophthalmol.* 2014; 157(5):1056-63.